

occurrence of the c-kit Asp816Val activating mutation in T cells, B cells, and myelomonocytic cells in patients with mastocytosis. *Exp Hematol* 2000;28:140-7.

- Afonja O, Amorosi E, Ashman L, Takeshita K. Multilineage involvement and erythropoietin independent erythroid progenitor cells in a patient with systemic mastocytosis. *Ann Hematol* 1998; 77:183-6.
- Sotlar K, Fridrich C, Mall A, Jaussi R, Bultmann B, Valent P, et al. Detection of c-kit point mutation Asp-816→Val in microdissected pooled single mast cells and leukemic cells in a patient with systemic mastocytosis and concomitant chronic myelomonocytic leukemia. *Leuk Res* 2002;26:979-84.

- Pardanani A, Reeder T, Li CY, Tefferi A. Eosinophils are derived from the neoplastic clone in patients with systemic mastocytosis and eosinophilia. *Leuk Res* 2003;27:883-5.
- Cools J, DeAngelo DJ, Gotlib J, Stover EH, Legare RD, Cortes J, et al. A tyrosine kinase created by fusion of the PDGFRA and FIP1L1 genes as a therapeutic target of imatinib in idiopathic hypereosinophilic syndrome. *N Engl J Med* 2003;348:1201-14.
- Reeder TL, Bailey RJ, Dewald GW, Tefferi A. Both B and T lymphocytes may be clonally involved in myelofibrosis with myeloid metaplasia. *Blood* 2003;101:1981-3.

Malignant Lymphomas

Detection of *bcl-2* rearrangement in mucosa-associated lymphoid tissue lymphomas from patients with hepatitis C virus infection

It has been shown that t(14;18)(q32;q21) involving fusion of *IGH* with *MALT1* occurs frequently in mucosa-associated lymphoid tissue (*MALT*) lymphomas. Results of the present study indicate that the classical form of t(14;18)(q32;q21) involving fusion of *IGH* with *bcl-2* can be detectable in a subset of *MALT* lymphomas in patients with hepatitis C virus (HCV) infection.

haematologica 2003; 88:873-874
(<http://www.haematologica.org/2004/7/873>)

Extranodal marginal zone B-cell lymphomas of mucosa-associated lymphoid tissue (*MALT* lymphomas) comprise approximately 8% of non-Hodgkin's lymphomas (NHL) and are among the 6 most common forms of NHL. *MALT* lymphomas usually result from chronic stimulation of B-cells by persistent infection or autoimmune processes.¹ Among the genetic abnormalities associated with *MALT* lymphomas, t(11;18)(q21;q21) is the most common. This translocation fuses apoptosis inhibitor-2 (*API2*) with *MALT* lymphoma-associated translocation gene-1 (*MALT1*).¹ However, Streubel *et al.* showed that t(14;18)(q32;q21) involving fusion of the immunoglobulin heavy chain gene (*IGH*) with *MALT1* also occurs in *MALT* lymphomas.² This finding was supported by recent reports from Sanchez-lzquierdo *et al.* and Murga Penas *et al.*^{3,4} The translocation described by these 3 groups was detected most frequently in *MALT* lymphomas of the conjunctiva, liver, skin, parotid gland, and salivary gland. Interestingly, all of these anatomical sites are susceptible to hepatitis C virus (HCV) infection.⁵

Chronic antigenic stimulation of B-cells resulting from HCV infection has been suggested to contribute to the development of lymphoproliferative disorders.⁶ Previous studies have also suggested a role for the *bcl-2* rearrangement during development of lymphoproliferative disorders among HCV-infected individuals.⁷ However, the incidence of the classical form of t(14;18)(q32;q21) involving fusion of *IGH* with *bcl-2* has not been investigated in *MALT* lymphoma patients. In the present study, *MALT* lymphoma tissue from 11 HCV-infected and 9 HCV-negative patients was analyzed for the presence of this translocation (Table 1). DNA isolated from *MALT* lymphoma biopsy specimens was analyzed for the presence of *bcl-2* rearrangement at the major (MBR) and minor breakpoint regions (mcr) by polymerase chain reaction (PCR) as previously described.⁸ The *MALT* lymphoma biopsy specimens were collected from the primary site of disease.

Rearrangement of *bcl-2* was detected in 5 of 20 (25%) *MALT* lymphoma biopsy specimens after both the first and second rounds of amplification. Control experiments were

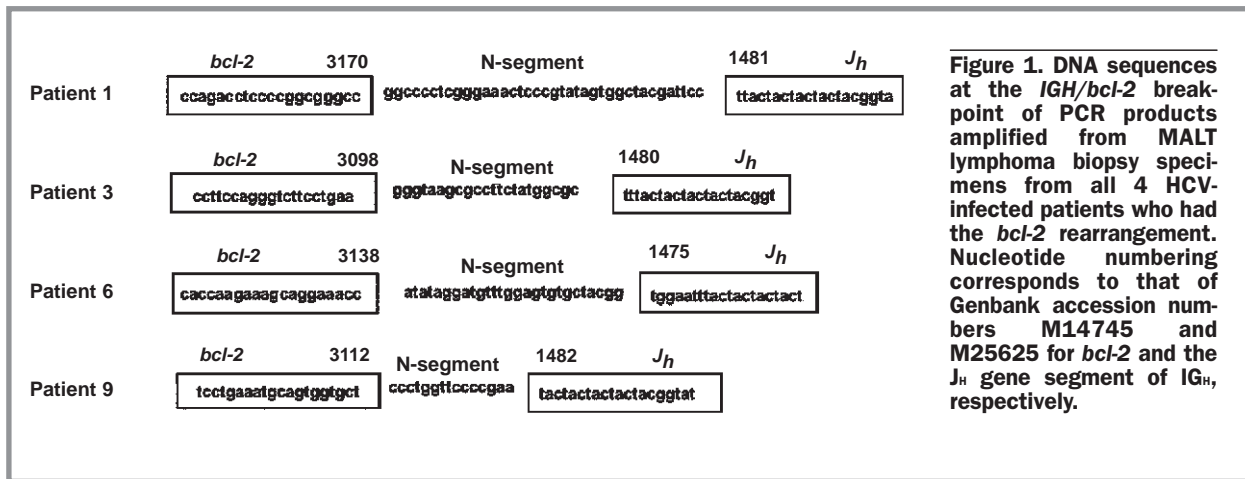
Table 1. Clinical characteristics and *bcl-2* rearrangement status of the *MALT* lymphoma patients studied.

| Patient | Age/ Sex | Sites of Disease | HCV Status | MC | <i>bcl-2</i> Rearr. |
|---------|-------------|-------------------------|---------------|----|------------------------|
| 1 | 65/F | Stomach, BM | + | + | + |
| 2 | 66/F | Skin | + | + | - |
| 3 | 59/M | Liver, BM | + | + | + |
| 4 | 66/F | Stomach | + | + | - |
| 5 | 55/F | Salivary gland, BM | + | + | - |
| 6 | 69/F | Salivary gland, BM | + | - | + |
| 7 | 51/F | Skin, BM | + | - | - |
| 8 | 79/M | Salivary gland, stomach | + | - | - |
| 9 | 72/F | Stomach | + | - | + |
| 10 | 57/F | Salivary gland, BM | + | - | - |
| 11 | 60/F | Lung, BM | + | - | - |
| 12 | 38/M | Ocular adnexa, BM | - | - | - |
| 13 | 70/F | Stomach, BM | - | - | + |
| 14 | 69/F | Stomach, spleen | - | - | - |
| 15 | 64/M | Fatty renal capsule, BM | - | - | - |
| 16 | 61/F | Stomach, BM | - | - | - |
| 17 | 65/F | Stomach, BM | - | - | - |
| 18 | 60/F | Stomach, spleen, BM | - | - | - |
| 19 | 71/M | Stomach, BM | - | - | - |
| 20 | 67/M | Stomach, BM | - | - | - |

Rearr.: rearrangement; BM: bone marrow; F: female; M: male; MC: type II mixed cryoglobulinemia syndrome.

performed to verify that the methods used to test for *bcl-2* rearrangement were reliable. Tumor biopsy specimens from 15 of 15 HCV-negative follicular lymphoma (FL) patients were positive for *bcl-2* rearrangement. Of these translocations, 13 occurred at the MBR and 2 occurred at the mcr. In contrast, *bcl-2* rearrangement was not detected in peripheral blood mononuclear cell from 50 healthy HCV-negative donors. These positive and negative control experiments demonstrate that the methods used to test for *bcl-2* rearrangement reliably detected the genetic abnormality without yielding false positive results.

MALT lymphoma biopsy specimens were also analyzed for expression of Bcl-2, Bcl-6, and CD10 by immunohistochemistry. All *MALT* lymphoma biopsy specimens tested were negative for both Bcl-6 and CD10 expression, which excludes the possibility that these tumors were of follicular origin. Bcl-2 expression was analyzed in *MALT* lymphoma biopsy specimens from 3 of 5 patients positive for the *bcl-2* rearrangement and from 12 of 15 patients negative for the *bcl-2* rearrangement. Bcl-2 expression was detected in 3 of 3 patients positive for the *bcl-2* rearrangement, a result consistent with those of previous studies correlating Bcl-2 expression with the *bcl-2* rearrangement.⁹ Bcl-2 was expressed in 8 of 12 *MALT* lymphoma biopsy specimens neg-



ative for the *bcl-2* rearrangement. It is possible that Bcl-2 expression in these MALT lymphomas is driven by mechanisms other than the *bcl-2* rearrangement, as has been reported elsewhere.^{10,11}

Rearrangement of *bcl-2* has been proposed to be involved in the multistep mechanism of lymphomagenesis. Increased Bcl-2 expression promotes clonal expansion of B cells by preventing apoptosis. Previous studies have suggested that the *bcl-2* rearrangement contributes to the pathogenesis of lymphoproliferative disorders associated with HCV infection.⁷ In agreement with this possibility, the results of the present study indicate that the *bcl-2* rearrangement can be detected in a subset of MALT lymphomas from HCV-infected patients (Figure 1). It is important to point out that 15 of the 20 MALT lymphoma patients studied had bone marrow involvement. Therefore, it would also be of interest to investigate the frequency of *bcl-2* rearrangement among MALT lymphoma patients with an earlier stage of disease. Additional studies are required to clarify the relationship between *bcl-2* rearrangement and MALT lymphoma development in both the presence and absence of HCV infection.

An interaction between genetic influences and environmental stimuli during lymphomagenesis has been suggested previously.⁹ This interaction is illustrated by a patient who developed follicular lymphoma 2 years after being diagnosed with MALT lymphoma. Rearrangement of *bcl-2* was present in both the follicular and MALT lymphomas and VDJ rearrangement analysis indicated that both lymphomas were derived from the same B-cell clone. It was postulated that the follicular lymphoma in this patient may have developed as a result of co-operation between the presence of *bcl-2* rearrangement and B-cell exposure to the germinal center environment. HCV infection may serve as an environmental stimulus that supports development of MALT lymphomas harboring the *bcl-2* rearrangement.

Massimo Libra,^{*} Valli De Re,^{*} Annunziata Gloghini,^{*} Daniela Gasparotto,^{*} Laura Gragnani,^{*} Patrick M. Navolanic,[†] Salvatore De Vita,[^] Maria Clorinda Mazzarino,[§] Anna Linda Zignego,[¶] Antonino Carbone,[°] Mauro Boiocchi^{*}

^{*}Division of Experimental Oncology, [†]Division of Pathology, Centro di Riferimento Oncologico, Aviano, Pordenone, Italy;

[‡]Department of Internal Medicine, University of Florence, Italy;

[§]Department of Microbiology and Immunology, Brody School of Medicine at East Carolina University, Greenville, NC, USA;

[¶]Division of Rheumatology, DPMSC, University of Udine, Italy;

[°]Department of Biomedical Sciences, University of Catania, Italy

Key words: MALT lymphoma, *bcl-2* rearrangement, t(14;18), hepatitis C virus.

Funding: This work was funded in part by the Italian Association for Research on Cancer (AIRC). The authors thank Mrs. Luigina Mei for editorial assistance.

Correspondence: Dr. Mauro Boiocchi, Division of Experimental Oncology 1, Centro di Riferimento Oncologico, Via Pedemontana Occidentale 12, 3301 Aviano (PN). Phone: international +39.0434.659300. Fax: international +39.0434.659659. E-mail: mboiocchi@cro.it/os1@cro.it

References

1. Isaacson PG. Extranodal marginal zone B-cell lymphoma of mucosa-associated lymphoid tissue (MALT lymphoma). In: Jaffe ES, Harris NL, Stein H, Vardiman JW, editors. World Health Organization Classification of Tumours. Pathology and Genetics: Tumours of Haemopoietic and Lymphoid Tissues. Lyon, France: IARC Press: 2001.
2. Streubel B, Lamprecht A, Dierlamm J, Cerroni L, Stolte M, Ott G, et al. t(14;18)(q32;q21) involving IGH and MALT1 is a frequent chromosomal aberration in MALT lymphoma. *Blood* 2003; 101:2335-9.
3. Sanchez-Izquierdo D, Buchonnet G, Siebert R, Gascoyne RD, Climent J, Karan L, et al. MALT1 is deregulated by both chromosomal translocation and amplification in B-cell non-Hodgkin lymphoma. *Blood* 2003;101:4539-46.
4. Murga Penas EM, Hinz K, Röser K, Copie-Bergman C, Wlodarska I, Marynen P, et al. Translocations t(11;18)(q21;q21) and t(14;18)(q32;q21) are the main chromosomal abnormalities involving MALT/MALT1 in MALT lymphomas. *Leukemia* 2003; 17:2225-9.
5. De Vita S, Sacco C, Sansonno D, Gloghini A, Dammacco F, Crovatto M, et al. Characterization of overt B-cell lymphomas in patients with hepatitis C virus infection. *Blood* 1997;90:776-82.
6. De Re V, De Vita S, Marzotto A, Rupolo M, Gloghini A, Pivetta B, et al. Sequence analysis of the immunoglobulin antigen receptor of hepatitis C virus-associated non-Hodgkin lymphomas suggests that the malignant cells are derived from the rheumatoid factor-producing cells that occur mainly in type II cryoglobulinemia. *Blood* 2000;96:3578-84.
7. Zignego AL, Giannelli F, Marrocchi ME, Mazzocca A, Ferri C, Giannini C, et al. t(14;18) translocation in chronic hepatitis C virus infection. *Hepatology* 2000;31:474-9.
8. Libra M, De Re V, De Vita S, Gasparotto D, Gloghini A, Rupolo M, et al. Low frequency of *bcl-2* rearrangement in HCV-associated non-Hodgkin's lymphoma tissue. *Leukemia* 2003;17:1433-6.
9. Aiello A, Du MQ, Diss TC, Peng HZ, Pezzella F, Papini D, et al. Simultaneous phenotypically distinct but clonally identical mucosa-associated lymphoid tissue and follicular lymphoma in a patient with Sjögren's syndrome. *Blood* 1999;94:2247-51.
10. Pan L, Diss TC, Cunningham D, Isaacson PG. The *bcl-2* gene in primary B cell lymphoma of mucosa-associated lymphoid tissue (MALT). *Am J Pathol* 1989;135:7-11.
11. Casato M, Mecucci C, Agnello V, Fiorilli M, Knight GB, Matteucci C, et al. Regression of lymphoproliferative disorder after treatment for hepatitis C virus infection in a patient with partial trisomy 3, Bcl-2 overexpression, and type II cryoglobulinemia. *Blood* 2002;99:2259-61.