

Skeletal Anomalies and Normal Variants in Patients with Palatally Displaced Canines

Rosalia Leonardi^a; Ersilia Barbato^b; Maurizio Vichi^c; Mario Caltabiano^d

ABSTRACT

Objective: To test the null hypothesis that there is no increased prevalence of skeletal anomalies and/or normal variants as evidenced by the cephalometric radiographs of patients with palatally displaced canines (PDC).

Materials and Methods: The treatment records of 38 white subjects between 14 and 20 years old with PDC were collected and evaluated retrospectively. Inclusion criteria for the study required that the case records include good-quality panoramic radiographs and lateral cephalometric radiographs with the first four cervical vertebrae clearly visible. The anomalies recorded for each case included sella bridge, atlanto-occipital ligament calcification or ponticulus posticus, and posterior arch atlas deficiency. A control group consisted of 70 consecutively treated subjects who had no other dental anomalies and whose maxillary canines had erupted normally. Fisher's exact test and Pearson's chi-square test were used to determine possible statistically significant differences in the incidence of skeletal anomalies and/or normal variants between the group of patients with PDC and the control group.

Results: The prevalence of skull anomalies and normal variants seen in cephalometric radiographs was increased in patients with PDC. Because of the presence of ponticulus posticus (Pearson's chi-square, $P < .050$; Fisher's exact test, $P < .052$), sella bridge (Pearson's chi-square, $P < .042$; Fisher's exact test, $P < .042$), and posterior arch deficiency (Pearson's chi-square, $P < .047$; Fisher's exact test, $P < .039$), statistically significant differences were observed between subjects with PDC and the control group.

Conclusions: The null hypothesis was rejected. There is an increased prevalence of skull skeletal anomalies and/or normal variants in patients with PDC. (*Angle Orthod.* 2009;79:727–732.)

KEY WORDS: Palatally displaced canine; Skeletal anomalies, normal variant; Cephalometric radiograph

INTRODUCTION

Cephalometric radiographs are used in orthodontics to evaluate the development, growth, and morphometric relationships of craniofacial and dental struc-

tures, but they also include other diagnostic information about the skull, face, and upper cervical spine. Various occult pathologies and rare normal variants involving the head or spine have been reported thanks to this information.^{1–8}

On the other hand, most of these pathologic conditions, developmental abnormalities, or normal variants are associated with a significant problem in other systems.^{4,9,10} Interestingly, some of these findings are detectable very early in life¹¹ and often precede other signs or symptoms in syndromes. Therefore, in some cases, they could potentially be valuable for an early diagnosis.

Recently a higher incidence of interclinoid ligament (ICL) or sella turcica bridge calcification has been associated with palatally displaced canines (PDC).⁵ Thus the occurrence of a new sign in craniofacial skeletal anomalies, concomitant with PDC, has been estab-

^a Associate Professor, Department of Orthodontics, University of Catania, Catania, Italy

^b Professor, Department of Orthodontics, University of Rome "La Sapienza," Rome, Italy

^c Professor, Department of Statistics, University of Rome "La Sapienza," Rome, Italy

^d Professor, Department of Orthodontics, University of Catania, Catania, Italy

Corresponding author: Dr Rosalia Leonardi, Department of Orthodontics, University of Catania, via S. Sofia no. 78, Catania, Italy (e-mail: rleonard@unict.it)

Accepted: October 2008. Submitted: August 2008.

© 2009 by The EH Angle Education and Research Foundation, Inc.

lished. This relationship may be based on the involvement of neural crest cells (NCCs) and/or homeobox or hox genes during the development stage.¹² It appears that tooth formation and eruption and sella turcica bridge calcification, as well as neck and shoulder skeletal development, are influenced by NCCs.¹³

The aims of this study were: (1) to describe the skeletal anomalies and normal variants of the cervical column (partial cleft of the posterior portion of the arch of atlas and ponticulus posticus) in patients with PDC, (2) to evaluate the presence of “sella turcica bridge” in patients with PDC, and (3) to compare the findings of the PDC group with those found in subjects with normal craniofacial morphology and no obvious dental anomalies. The null hypothesis that there is no increased prevalence of skeletal anomalies and/or normal variants seen in cephalometric radiographs of patients with PDC was tested.

MATERIALS AND METHODS

The treatment records of 38 white subjects (16 male and 22 female subjects, ages 14 to 20 years; mean age 16.3 years) with PDC were collected retrospectively from a large number of patients seen over a 24-month period in the Department of Orthodontics, University of Catania, Italy, and the Department of Orthodontics, University of Roma “La Sapienza,” Italy. The diagnosis was made on the basis of clinical examinations and standardized radiographs and confirmed visually during surgery according to established standardized techniques.¹⁴

To be included in the study, the case records needed to include good-quality dental panoramic and lateral cephalometric radiographs with at least the first four cervical vertebrae visible. The exclusion criteria were the presence of a cleft lip and palate or other dental or craniofacial anomaly or syndromes, trauma, and multi-reagent chemotherapy.

A power analysis suggested that a control sample size of 70 patients was sufficient to evaluate significant differences in the skeletal anomalies between subjects with PDC and a control group. Thus the control group consisted of 70 subjects (41 female and 29 male subjects ages 15 to 19 years; mean age 15.5 years) who had no other dental anomalies and whose maxillary canines had erupted normally. This group represented randomly selected white subjects treated at the orthodontic clinics of both universities during the previous 24 months. The exclusion criteria were the same as those for the study group. The study was approved by the ethical committees of the relevant institutions.

Visual assessment of skeletal anomalies and normal variants of the cervical column on lateral profile radiographs and measurements to evaluate a “sella

turcica bridge” was performed by two of the authors. The tracings were made on ultrathin 0.003-inch transparent acetate sheets using a Pentel 0.5-mm lead pencil.

The cephalometric radiographs were evaluated on a masked, illuminated viewbox in a room with reduced lighting and were measured manually. Before starting the study, the authors calibrated themselves by scoring the first 30 radiographs together to establish agreement. Radiographs were interpreted and scored independently.

Skeletal Anomalies and Normal Variants of the Cervical Column

Visual assessment of the cervical column consisted of the first four cervical units that are normally seen on a standardized lateral skull radiograph. Data regarding posterior arch deficiency and atlanto-occipital ligament calcification were collected. Regarding cervical column anomalies,¹⁵ only data on posterior arch deficiency was recorded and processed with the statistical analysis because cervical vertebrae fusion cannot be diagnosed—only suspected—using lateral skull radiographs.¹⁶ Atlanto-occipital ligament calcification (arcuate foramen or ponticulus posticus)^{17,18} was recorded and scored according to a standardized scoring scale; this meant evaluating the extent of ossification in the atlanto-occipital ligament. Ponticulus posticus was scored as Class I (no calcification), Class II (incomplete calcification), or Class III (complete calcification).

Sella Turcica Bridge

The extent of a sella turcica bridge was quantified from each profile radiograph as previously described.^{5,19} Briefly, the sella turcica length (the distance from the tuberculum sella to the tip of the dorsum sella) and anteroposterior greatest diameter (from the tuberculum sella to the furthest point on the inner wall of the pituitary fossa) were measured.

A standardized scoring scale was established by comparing the measurements taken for sella turcica length and diameter. If the length of the sella turcica was greater than or equal to three fourths of the diameter, it was scored as Class I (no calcification); if the length was less than or equal to three fourths of the diameter (ICL partially calcified), it was designated Class II; and a Class III rating was given for a radiographically visible diaphragma sella (ICL completely calcified).

Reliability and Error

The reliability of a visual assessment of morphologic characteristics of cervical vertebrae (posterior arch de-

Table 1. Age and Gender Distribution of Patient Sample

Age Class (y)	N	Mean	SD	Male		Female	
				N	%	N	%
14–16	43	14.7565	0.42	18	41.9	25	58.1
16–18	45	16.5438	0.55	18	40.0	27	60.0
18–20	20	19.3515	0.54	9	45.0	11	55.0
Total	108	13.1669	1.49	45	41.7	63	58.3

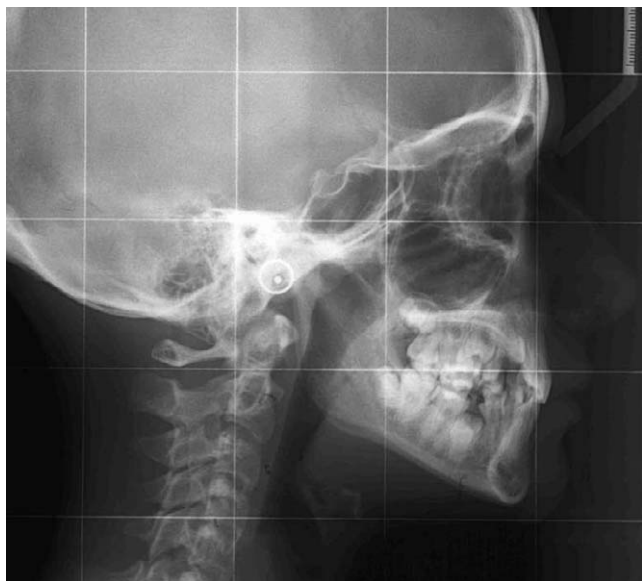


Figure 1. Lateral cephalometric radiograph from a patient with palatally displaced canines. A sella turcica bridge can be appreciated.

iciency and ponticulus posticus) was determined by interobserver examinations by the authors. This showed “very good” agreement (kappa = 0.79).

To calculate the error of the method for measuring sella turcica “bridge,” 25 radiographs were selected randomly and measured. Two weeks later, the measurements were repeated and the same distances between two set of recordings were calculated. Random error was calculated using the Houston method.²⁰ No systematic error was detected between the duplicate measurements of the conventional variables. Differences between duplicate measurements ranged from 0 to 0.7 mm. The coefficient of reliability ranged from 95.8% to 98.5%. The random error (the square root of half of the variance of the difference between duplicate

measurements) ranged from 0.15 to 0.22 for both length and diameter and was not particularly significant.

Statistical Analysis

Skeletal anomalies and/or normal variants were tabulated for both groups. Descriptive statistics were computed and the groups were compared. Fisher’s exact test and Pearson’s chi-square test were used to determine the possible statistically significant differences in the incidence of skeletal anomalies and/or normal variants between the group of patients with PDC and the control group. All statistical analyses were done with the software Statistical Package for the Social Sciences (SPSS Inc, Chicago, Ill).

RESULTS

Data regarding the age and gender distribution for the study sample are reported in Table 1. The prevalence of incomplete and complete (sella bridge) ICL calcification (Figure 1) in the subjects with PDC was higher than that in the control group. In fact, 34.2% of patients with PDC versus 25.7% of control patients showed an ICL that was more than half calcified. Complete calcification of the ICL (sella turcica bridge) was observed in 18.4% of subjects with PDC and only 5.7% of the control subjects. These differences were statistically significant according to Pearson’s chi-square test ($P < .042$) and Fisher’s exact test ($P < .042$) (Table 2).

More PDC subjects (18.4%) showed complete calcification of the atlanto-occipital ligament (ponticulus posticus), as opposed to the control group (4.3%) (Figure 2). Incomplete calcification of the atlanto-occipital ligament was observed in 15.8% of patients with PDC and 15.7% of the control subjects. These were statistically significantly different according to Pearson’s chi-square test ($P < .050$) and Fisher’s exact test ($P < .052$) (Table 3).

The prevalence of partial cleft in the posterior portion of the neural arch of the atlas was also increased in patients with PDC (15.8%). This difference was statistically significant according to Pearson’s chi-square test ($P < .047$) and Fisher’s exact test ($P < .039$) (Table 4).

Table 2. Interclinoid Ligament Calcification Among Patients and Control Subjects

Calcification of the Diaphragma Sellae	Control Group		Subjects with PDC		Pearson’s Chi-Square		Fisher’s Exact Test	
	N	%	n	%	Value	P	Value	P
No calcification	48	68.6	18	47.4	6.336	.042	6.175	.042
More than half calcified	18	25.7	13	34.2				
Completely calcified	4	5.7	7	18.4				
Total	70	100.0	38	100.0				

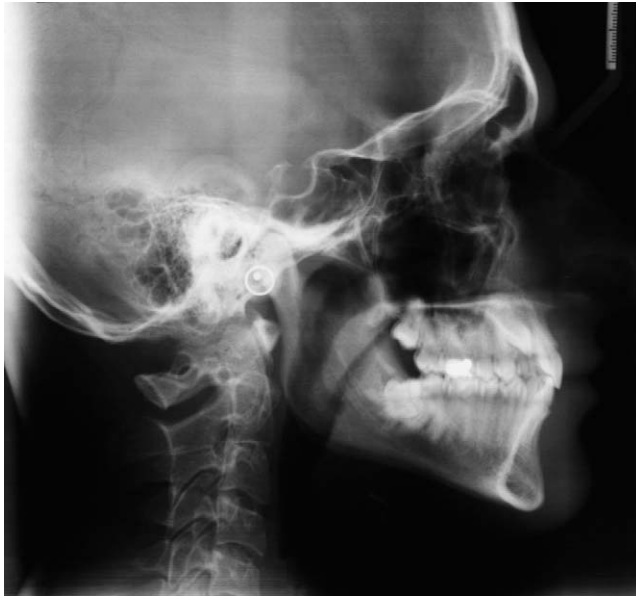

Figure 2. Lateral cephalometric radiograph from a patient with palatally displaced canines. A complete calcification of the atlanto-occipital ligament or ponticulus posticus can be appreciated.

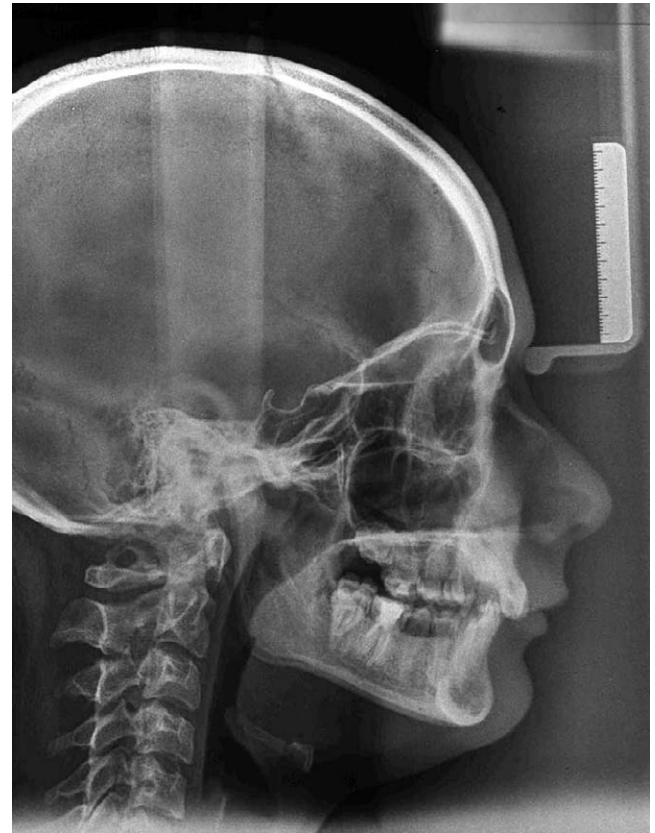


Figure 3. Lateral cephalometric radiograph from a patient with palatally displaced canines. A partial calcification of the interclinoid ligament (partial bridged sella), ponticulus posticus, and a probable fusion of the first and the second cervical vertebrae can be observed.

However, no statistically significant associations were observed between bridged sella and ponticulus posticus (chi-square = 2.736, $P = .615$); bridged sella and partial cleft of the atlas (chi-square = 3.484, $P = .179$); and ponticulus posticus and partial cleft of atlas (chi-square = 1.181, $P = .736$); although these characteristics were observed in some patients (Figure 3).

DISCUSSION

Anomalies of the cervical vertebrae have been described in several syndromes,⁹ and associations between cervical vertebrae and maxillary malformations^{15,21,22} and condyle and vertical craniofacial mor-

phology (deep bite)^{6,7,23} have been reported more recently.

On the other hand, a greater frequency of sella turcica bridge has been described in patients with severe craniofacial deviations⁴ and tooth anomalies⁵ and has

Table 3. Atlanto-occipital Ligament Calcification among Patients and Control Subjects

Atlanto-occipital Ligament Calcification	Control Group		Subjects with PDC		Pearson's Chi-Square		Fisher's Exact Test	
	N	%	N	%	Value	P	Value	P
No calcification	56	80.0	25	65.8	5.978	.050	5.636	.052
Incomplete calcification	11	15.7	6	15.8				
Completely calcified	3	4.3	7	18.4				
Total	70	100.0	38	100.0				

Table 4. Posterior Arch Deficiency among Patients and Control Subjects

Posterior Arch Deficiency	Control Group		Subjects with PDC		Pearson's Chi-Square		Fisher's Exact Test	
	N	%	N	%	Value	P	Value	P
Absent	67	95.7	32	84.2	4.267	.047	4.039	.039
Present	3	4.3	6	15.8				
Total	70	100.0	38	100.0				

also been noted in some patients with other disorders and syndromes.^{10,24–26} The results of the present study demonstrate an increased prevalence of posterior arch deficiency, ponticulus posticus, and sella turcica bridge in patients with PDC.

With regard to ponticulus posterior or arcuate foramina, we observed an increased prevalence (34.2%) of complete and incomplete arcuate foramina in subjects with PDC, in contrast to the prevalence (15.8%) observed in the control group. This finding is consistent with the literature.^{11,17,18} An increased prevalence of complete and partial ICL calcification was also detected in patients with PDC compared to the control sample. These results are consistent with the reported radiographic data of sella turcica bridge in patients with dental anomalies.⁵

Posterior arch deficiency of the atlas occurred more frequently in individuals with PDC (15.8%) compared to the control sample (4.3%). In fact, no anomaly was detected in our sample of orthodontic patients without PDC. In this study, we deliberately did not evaluate cervical vertebrae fusion, as this is best determined with the use of flexion and extension radiographs, which can demonstrate a change in the distance between vertebrae if they are not fused.¹⁶ Thus, to avoid false-positive or false-negative results, these data were recorded but were not evaluated from a statistical point of view.

Overall, these findings indicate that some skeletal anomalies and normal variants seen in cephalometric radiographs are associated not only with malformations of the jaw, craniofacial morphology, and occlusion^{15,21,25} but also with tooth anomalies such as PDC.

This relationship seems to be based on the involvement of NCCs and/or homeobox or hox genes during the developmental stages^{12,27} and formation of teeth and sella turcica. Therefore, neck and shoulder skeletal development²⁷ is influenced in the same way; in fact, homeobox gene mutation may be responsible for congenital cervical spine anomalies. Because the teeth, the head, and the cervical spine are influenced in their development by NCCs, it is conceivable to assume that any disturbance of NCCs might interfere with the development of one or more systems that are under their influence.

The etiology of PDCs has been debated for a long time. Data from multiple sources support a genetic etiology.^{28,29} Tests of genetic influence have focused on bilateral PDC, sex and population differences in the incidence of PDC, familial occurrence of PDC, and the occurrence of other dental anomalies concomitant with PDC.²⁸ Bearing this in mind, our findings broaden the concept somewhat that PDC is seen only in conjunction with other dental anomalies²⁹ or skeletal anomalies and normal variants of skull and cervical vertebrae

in patients with PDC. In fact, PDC is associated with other clinically recognizable features that often occur together and could be considered part of a “syndrome.”

We believe that future research into the molecular basis of dentofacial abnormalities could benefit from the reporting of new clinical interrelationships such as those presented here. Our findings are consistent with the hypothesis that a common pathogenesis probably relates to a simultaneous embryogenesis of some skull structures. Moreover, from a clinical point of view, these skeletal anomalies and/or normal variants may be considered risk factors that could enable the clinician to make an early diagnosis and thus treat the eruption disturbance at an early stage.

CONCLUSIONS

- The null hypothesis was rejected. There was a statistically significant increase in the prevalence of skeletal anomalies and/or normal variants in patients with PDC versus the control group.
- Because many of these skeletal anomalies and normal variants are present early in life, their early detection can be used to forecast the presence of PDC later in life, enabling the clinician to adopt preventive measures.

REFERENCES

1. Tetradis S, Kantor ML. Prevalence of skeletal and dental anomalies and normal variants seen in cephalometric and other radiographs of orthodontic patients. *Am J Orthod Dentofacial Orthop.* 1999;116:572–577.
2. Hickam HE, Morrissy RT. Os odontoideum detected on a lateral cephalogram of a 9-year-old orthodontic patient. *Am J Orthod Dentofacial Orthop.* 1990;98:89–93.
3. Huggare J. Congenital absence of the atlas posterior arch. A case report. *Br J Orthod.* 1995;22:71–73.
4. Becktor JP, Einersen S, Kjaer I. A sella turcica bridge in subjects with severe craniofacial deviations. *Eur J Orthod.* 2000;22:69–74.
5. Leonardi R, Barbato E, Vichi M, Caltabiano M. A sella turcica bridge in subjects with dental anomalies. *Eur J Orthod.* 2006;28:580–585.
6. Sonnesen L, Kjaer I. Cervical vertebral body fusions in patients with skeletal deep bite. *Eur J Orthod.* 2007;29:464–470.
7. Sonnesen L, Kjaer I. Cervical column morphology in patients with skeletal Class III malocclusion and mandibular overjet. *Am J Orthod Dentofacial Orthop.* 2007;132(4):427.e7–12.
8. Abdel-Kader HM. Sella turcica bridges in orthodontic and orthognathic surgery patients. A retrospective cephalometric study. *Aust Orthod J.* 2007;23:30–35.
9. Lachman RS. The cervical spine in the skeletal dysplasias and associated disorders. *Pediatr Radiol.* 1997;27:402–408.
10. Kjaer I, Becktor KB, Lisson J, Gormsen C, Russell BG. Face, palate, and craniofacial morphology in patients with a solitary median maxillary central incisor. *Eur J Orthod.* 2001;23:63–73.

11. Kendrick GA, Biggs NL. Incidence of the ponticulus posticus of the first cervical vertebra between ages six to seventeen. *Anat Rec.* 1963;145:449–451.
12. Miletich I, Sharpe PT. Neural crest contribution to mammalian tooth formation. *Birth Defects Res C Embryo Today.* 2004;72:200–212.
13. Matsuoka T, Ahlberg PE, Kessar N, et al. Neural crest origins of the neck and shoulder. *Nature.* 2005;436:347–355.
14. Becker A, Sharabi S, Chaushu S. Maxillary tooth size variation in dentitions with palatal canine displacement. *Eur J Orthod.* 2002;24:313–318.
15. Sandham A. Cervical vertebral anomalies in cleft lip and palate. *Cleft Palate J.* 1986;23:206–214.
16. Guille JT, Sherk HH. Congenital osseous anomalies of the upper and lower cervical spine in children. *J Bone Joint Surg Am.* 2002;84:277–288.
17. Hasan M, Shukla S, Siddiqui MS, Singh D. Posterolateral tunnels and ponticuli in human atlas vertebrae. *J Anat.* 2001;199:339–343.
18. Mitchell J. The incidence of the lateral bridge of the atlas vertebra. *J Anat.* 1998;193:283–285.
19. Cederberg RA, Benson BW, Nunn M, English JD. Calcification of the interclinoid and petroclinoid ligaments of sella turcica: a radiographic study of the prevalence. *Orthod Craniofac Res.* 2003;6:227–232.
20. Houston WJ. The analysis of errors in orthodontic measurements. *Am J Orthod.* 1983;83:382–390.
21. Horswell BB. The incidence and relationship of cervical spine anomalies in patients with cleft lip and/or palate. *J Oral Maxillofac Surg.* 1991;49:693–697.
22. Ugar DA, Semb G. The prevalence of anomalies of the upper cervical vertebrae in subjects with cleft lip, cleft palate, or both. *Cleft Palate Craniofac J.* 2001;38:498–503.
23. Sonnesen L, Pedersen CE, Kjaer I. Cervical column morphology related to head posture, cranial base angle, and condylar malformation. *Eur J Orthod.* 2007;29:398–403.
24. Axelsson S, Storhaug K, Kjaer I. Post-natal size and morphology of the sella turcica in Williams syndrome. *Eur J Orthod.* 2004;26:613–621.
25. Kjaer I, Fischer Hansen B, Reintoft I, Keeling JW. Pituitary gland and axial skeletal malformations in human fetuses with spina bifida. *Eur J Pediatr Surg.* 1999;9:354–358.
26. Kjaer I, Keeling JW, Reintoft I, Nolting D, Fischer Hansen B. Pituitary gland and sella turcica in human trisomy 21 fetuses related to axial skeletal development. *Am J Med Genet.* 1998;80:494–500.
27. Morotomi T, Kawano S, Toyono T, et al. In vitro differentiation of dental epithelial progenitor cells through epithelial-mesenchymal interactions. *Arch Oral Biol.* 2005;50:695–705.
28. Peck S, Peck L, Kataja M. The palatally displaced canine as a dental anomaly of genetic origin. *Angle Orthod.* 1994;64:249–256.
29. Baccetti T. A controlled study of associated dental anomalies. *Angle Orthod.* 1998;68:267–274.