

Double-level cervical total disc replacement for adjacent segment disease: is it a useful treatment? Description of late onset heterotopic ossification and review of the literature

G.M.V. BARBAGALLO, F. CERTO, M. VISOCCHI¹, G. SCIACCA, V. ALBANESE

Division of Neurosurgery, Department of Neurosciences, Policlinico "G. Rodolico" University Hospital, Catania, Italy

¹Institute of Neurosurgery, Catholic University, Rome, Italy

Abstract. – We report a rare case of double-level adjacent segment disease (ASD), occurring ten years later an anterior cervical discectomy (ACD) without fusion, treated by cervical arthroplasty, highlighting the outcome at long-term follow-up and focusing on heterotopic ossification.

In 1995 a 25-year-old man satisfactorily underwent ACD at C4/C5. At that time MRI also showed signs of degenerative disc disease (DDD) at C3/C4 and C5/C6. Ten years later, a new MRI scan showed a large C3/C4 and a smaller C5/C6 soft disc hernia together with spondylotic changes at the level above and below the site of the first surgery. At C4/C5 imaging revealed a kyphotic stable "pseudoarthrosis" with anterior bridging osteophyte. The patient underwent double-level arthroplasty with ProDisc-C. Clinical and radiological outcome was satisfactory. 3 and 5 years after surgery, X-rays and CT scan documented the progressive development of heterotopic ossification, with gradual reduction of range of motion. A late onset heterotopic ossification can neutralize the theoretical advantages of cervical arthroplasty, which should be considered an effective surgical option only in selected cases. ACDF and restoration of normal lordosis can be a viable alternative in cervical revision surgery, as motion preservation can not be always maintained for a long time.

Key Words:

Adjacent segment disease, Anterior cervical discectomy, ACDF, Arthroplasty, Disc prosthesis, Heterotopic ossification, Prodisc, Pseudoarthrosis.

Introduction

Cervical arthroplasty is a novel technique gaining increasing popularity as alternative to

other anterior surgical approaches, like anterior cervical discectomy (ACD) and anterior cervical discectomy and fusion (ACDF), used to treat cervical degenerative disc disease (DDD). Such increasing popularity stems from the hope to avoid some of the complications usually encountered with ACD or ACDF.

However, given the scant emerging data on heterotopic ossification (HO) at medium- and long-term follow-up, the role of HO in the setting of total disc replacement will be reviewed.

Several studies have reported the onset or progression of both radiological and clinical adjacent segment disease (ASD), i.e. spondylosis or disc herniations involving the motion segment above or below the site of a previous ACDF¹⁻¹⁹. The latter technique, although still regarded as a gold-standard procedure with a reported excellent clinical and radiological outcome, is known to induce biomechanical changes causing alterations of intradiscal pressure²⁰⁻²², increased strain¹⁵ and raised motion of adjacent functional spinal units (FSU)¹⁸, with consequent development of degenerative changes, as also shown by a prospective study comparing arthrodesis and arthroplasty¹⁷.

Experience with cervical total disc replacement (TDR) in patients previously treated with ACDF and harbouring *de novo* myeloradiculopathic symptoms secondary to ASD is available in the literature²²⁻²⁸. Conversely, a review of the literature did not reveal evidence on the role of arthroplasty in cases of documented ASD following ACD without fusion at the index surgery.

To our knowledge this is the first paper describing the use of cervical arthroplasty in a case of double-level ASD, respectively at C3/C4 and C5/C6, diagnosed ten years later an ACD alone performed at C4/C5.

Case Report

A 35 year old man presented because of recurrent neck pain and paresthesiae in both upper limbs and hands. Sensory disturbances rapidly extended to the lower limbs.

His past medical history was only remarkable for an anterior cervical discectomy that he had undergone at the age of 25, because of a C4/C5 soft disc hernia causing focal spinal cord compression and myelopathy. At that time, Magnetic Resonance Imaging (MRI) showed not only the C4/C5 disc hernia, with high signal intensity changes within the spinal cord on T2-weighted images, but also signs of accelerated disc degeneration both at C3/C4 and, to a lesser extent, at C5/C6 (Figure 1). However, symptomatology was thought to be related only to cord compression at C4/C5 and, consequently, that level was treated with ACD. Post-operatively, the patient sustained a significant clinical improvement and the subsequent follow-up was uneventful.

Ten years later, he returned back complaining of neck pain, recurrent paresthesiae and numbness in both upper limbs along with clumsiness

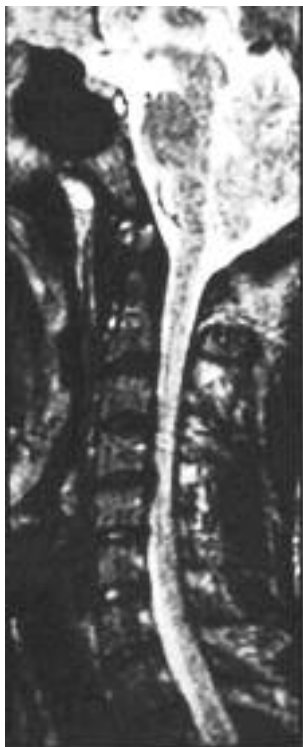

Figure 1. Preoperative (1995), T2-weighted, sagittal magnetic resonance image showing both a large disc herniation at C4/C5 causing spinal cord compression and signs of degenerative disc disease at C3/C4 and, to a lesser extent, at C5/C6.

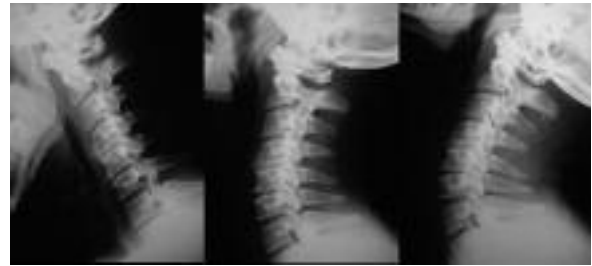

Figure 2. Preoperative (2005) cervical x-rays with flexion (*left*), neutral (*middle*) and extension (*right*) views showing a reduced disc height at C4/C5, along with a kyphotic angulation, with increased interspinous process distance, and absence of angular movement at the same level.

in the hands. A rapid progression of sensory disturbances to the lower limbs associated with severe walking disturbances prompted his admission for further treatment.

Neurologic examination demonstrated hypoaesthesia in the right C6 dermatome, absence of motor deficits, tetrahyperreflexia, clumsiness of both hands, bilateral positive Hoffmann sign, a left-sided upgoing plantar reflex and continuous ankle clonus. No sphincteric alterations were registered. His myelopathy was graded 3 according to the Nurick classification. The patient also completed the Neck Disability Index (NDI) and Short Form-36 (Physical Component Score – PCS, and Mental Component Score – MCS) questionnaires, whose values, respectively, were NDI: 26%, PCS: 35.6 and MCS 72,3.

X-rays showed signs of degenerative disc disease at C3/C4 and C5/C6, a reduced disc space height at C4/C5 together with segmental kyphosis, increased interspinous distance and osteophyte bridging over the anterior surfaces of C4 and C5 vertebral bodies. On flexion and extension views no angular motion was detected at the site of previous ACD (C4/C5) (Figure 2). A cervical MRI scan demonstrated changes at C3/C4 and C5/C6 consistent with ASD, i.e. a large soft disc herniation at C3/C4 and a smaller, median soft disc hernia associated with spondylotic changes at C5/C6. At both levels significant spinal cord compression was present, with persistent intramedullary T2-weighted high signal changes at the level of previous surgery (Figure 3). Computerized tomography (CT) sagittal reconstructions confirmed x-rays findings at C4/C5.

A standard right-sided, microsurgical cervical approach was performed; identification of the vertebral body midline was performed by using our experience with the Anatomical Midline Marking Technique²⁹.

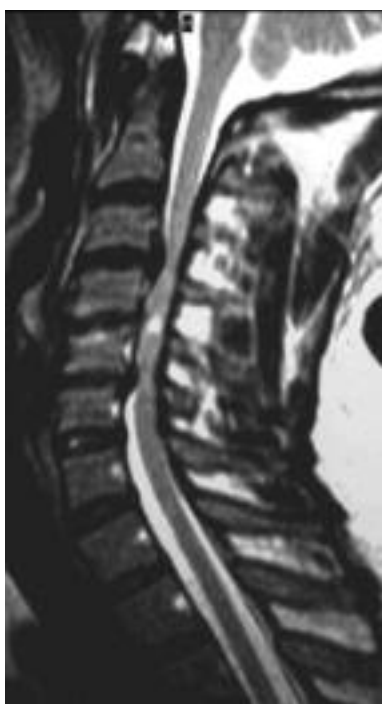

Figure 3. Magnetic Resonance imaging performed ten years later, in 2005. T2-weighted sagittal image showing a large disc herniation at C3/C4 causing spinal cord compression and a smaller disc herniation indenting the spinal cord at C5/C6. High signal changes are seen within the spinal cord at C4/C5.

Due to the large disc hernia causing severe spinal cord compression at C3/C4, we decided to treat this level first in order to prevent possible neurological worsening secondary to further spinal cord compression during surgical maneuvers at C5/C6. After opening the posterior longitudinal ligament and decompressing neural structures, two 5 mm high ProDisc-C were implanted at C3/C4 and C5/C6, respectively. At C3/C4 we used the prosthesis with the widest footprint we could implant without drilling the uncinata processes, given the absence of uncoarthrosis and foraminal stenosis. This prevented the use of a deeper device, which would have been associated also with increased width, according to the ProDisc-C sizes.

Postoperatively, a rapid improvement of both neck pain and myelopathic signs was registered; ankle clonus was no longer present on the left side since the second postoperative day. No anti-inflammatory drugs were used after surgery.

Clinical follow-up showed a significant improvement of myelopathy (Nurick grade 1) and a better Neck Disability Index (NDI) and Short-Form 36 (SF-36) scores, 2%, Physical Compo-

nent Score (PCS) 70 and Mental Component Score (MCS) 82.5 respectively.

Analysis of ROM at treated levels was calculated by using two lines parallel to the ProDisc-C keels' and by measuring the intervening angle in flexion and extension on lateral x-rays. Lordosis was assigned a negative value and kyphosis a positive one; the difference between the two values gave the final ROM. The OsiriX Medical Imaging Software was used to measure prostheses' motion three times per level and a mean value was obtained. Radiological outcome confirmed a mean total range of motion of 7.3° at C3/C4 and of 10.3° at C5/C6, and a lordotic angle of both FSUs, as well as a satisfactory sagittal alignment of the entire cervical spine despite the remaining kyphosis at C4/C5. The difference of C2-C7 Cobb's angles measured at full flexion and full extension gives an overall cervical spine ROM of 26.7°, with a Cobb's angle of 23° in neutral position (Figure 4).

Further clinical and radiological controls were performed at 6 and 12 months, 3 and 5 years. Despite stable neurology, a progressive heterotopic ossification at the treated vertebral levels was documented.

Discussion

Since the publications by Smith and Robinson and by Cloward^{30,31}, ACDF has been used to treat either cervical soft disc hernia or spondylosis. Over the years several technical refinements have been used in order to further improve results, and currently large experience with excellent clinical and radiological outcome is available³²⁻³⁴. Another technique, the anterior cervical discectomy (ACD) alone, has been reported to achieve similar clinical outcome without needing intervertebral bone grafts or spacers to get solid fusion³⁵⁻⁴⁷. Indeed, Savolainen et al hypothesized that "for a good clinical outcome, a solid bony fusion is perhaps unnecessary; a fibrous fusion may be enough"⁴⁴. However, ACD is known to be associated with a higher risk either of residual increased neck and shoulder pain^{40,48} or of developing a postoperative kyphotic deformity of the cervical spine⁴⁹; and this, in turn, can lead to the development of degenerative changes at adjacent levels^{50,13}.

It has been shown that ACDF induces biomechanical changes leading to modifications of intradiscal pressure²⁰⁻²² and to increased stress and motion of vertebral segments adjacent to the

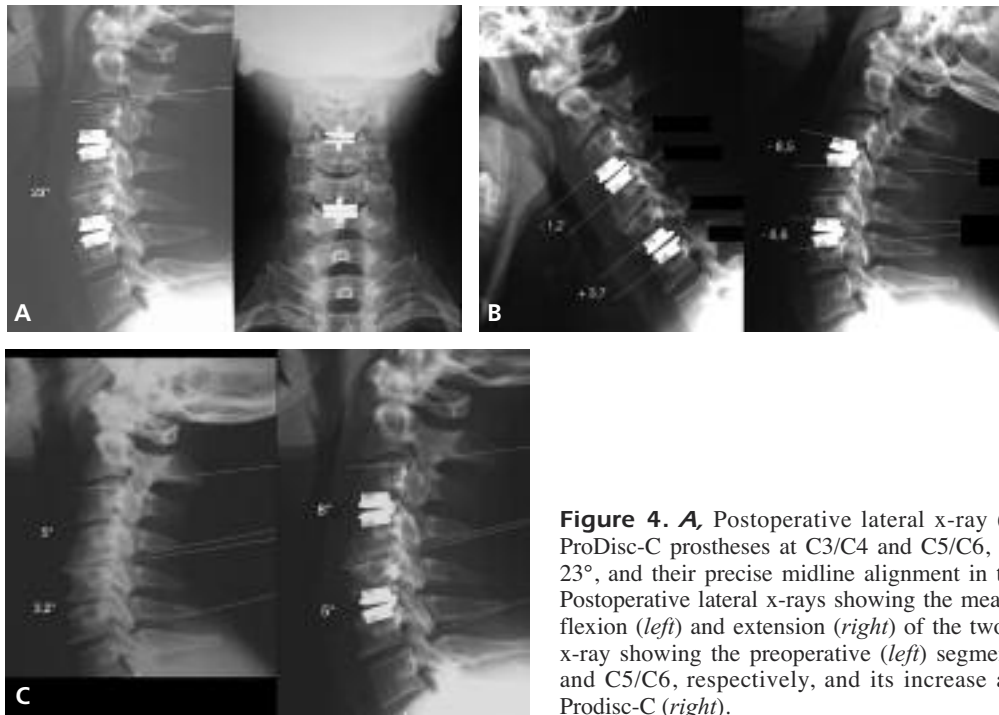


Figure 4. **A**, Postoperative lateral x-ray (*left*) showing the two ProDisc-C prostheses at C3/C4 and C5/C6, with a Cobb's angle of 23°, and their precise midline alignment in the AP view (*right*). **B**, Postoperative lateral x-rays showing the mean angular movement in flexion (*left*) and extension (*right*) of the two ProDisc-C. **C**, Lateral x-ray showing the preoperative (*left*) segmental kyphosis at C3/C4 and C5/C6, respectively, and its increase after arthroplasty with Prodisc-C (*right*).

fused ones^{15,18}. Eventually, the modified biomechanical behaviour of the cervical spine is responsible for the onset or progression of DDD at the functional spinal units (FSU) above or below the fusion, either radiographically or clinically. Several studies have analysed these issues both retrospectively and prospectively¹⁻¹⁹. Conversely, experimental⁵¹⁻⁵² and clinical^{18,27} studies suggest that arthroplasty allows for lower intradiscal pressures at adjacent levels compared with fusion.

Our case suggests a progression of degenerative disc disease already present at C3/C4 and C5/C6, i.e. ASD, in a case previously treated by ACD without fusion. It should be highlighted that either cervical X-rays or CT scan obtained before the second operation showed segmental kyphosis at C4/C5, with increased interspinous processes distance and an anterior osteophytic spur bridging C4 to C5. Indeed, flexion/extension X-rays confirmed the absence of motion at C4/C5 and the presence of pseudoarthrosis. The latter may result from the development of fibrous tissue in the intervertebral space after ACD^{46,49,50}. This phenomenon should be also considered as an intermediate step in the “natural” fusion process that is observed also in cases of ACD without fusion, especially when the height of the intervertebral gap is reduced⁴⁹.

We think that the time interval between the first operation and the onset of recurrent symptoms is

in agreement with the current literature¹⁻¹⁹ favoring the hypothesis of ASD at C3/C4 and C5/C6 rather than of spontaneous aging of the cervical spine at two disc levels, just the ones above and below the previously operated disc space, respectively. Moreover, it has been shown that the symptomatic ASD's rate is higher when on preoperative MR there are already signs of DDD at the disc levels adjacent to the treated (by ACDF) ones⁵³, and in cases of multilevel ASD following fusion procedures the degenerative changes were found more frequently at the upper level rather than at the lower one¹; this is consistent with the present case's findings, in which spinal cord compression was more severe at C3/C4.

We submit that although ACD alone is reported to achieve similar satisfactory clinical outcome to ACDF, without the complications attributed to fusion, the former technique neither prevents postoperative segmental kyphotic deformities of the cervical spine, as shown in our case at C4/C5 (Figure 4b), nor can avoid the progression of adjacent segments disease, a frequently reported complication of ACDF. In the present case, despite the satisfactory clinical outcome after the first operation, DDD at C3/C4 and C5/C6 progressively worsened over years to further spinal cord compression leading to recurrent myelopathy requiring surgery for the second time. TDR with Prodisc-C, a semiconstrained artificial disc,

allowed for complete neural decompression, motion preservation at C3/C4 and C5/C6, with a mean total ROM of 7.3° and 10.3°, respectively, as well as maintenance of satisfactory cervical spine lordosis. Kyphotic deformities at the treated levels, a reported complication associated with the use of the Bryan disc⁵⁴, were not encountered. We measured three times the FSU angle at C3/C4 and C5/C6, either before or after arthroplasty, and a mean value was obtained confirming increased segmental lordotic angle after TDR (Figure 4c). Laminectomy or laminoplasty, simple, safe and effective techniques used in the treatment of cervical myelopathy⁵⁵, were not chosen in the present case because the mainly anterior spinal cord compression, the preoperative sagittal alignment (with segmental kyphosis) and

the patient's age were considered as contraindication for a posterior approach.

However, despite stable mid- and long-term clinical improvement, as documented also by functional evaluation, imaging over the following years showed progression of HO (Figure 5).

Several studies^{11,17,24,56-60} on different disc prostheses have documented a satisfactory short- and intermediate-term outcome, and rare complications have been reported⁶¹. HO is a known phenomenon, whose causes remain unexplained⁶²⁻⁶⁴ and incidence highly variable^{65,66}. Patient-related conditions⁶⁴, unnatural segmental motion after prosthesis's implantation⁶², bone morphogenetic proteins released from normal bone in response to abnormal conditions like trauma, inflammation or disease of connective tissue attachments

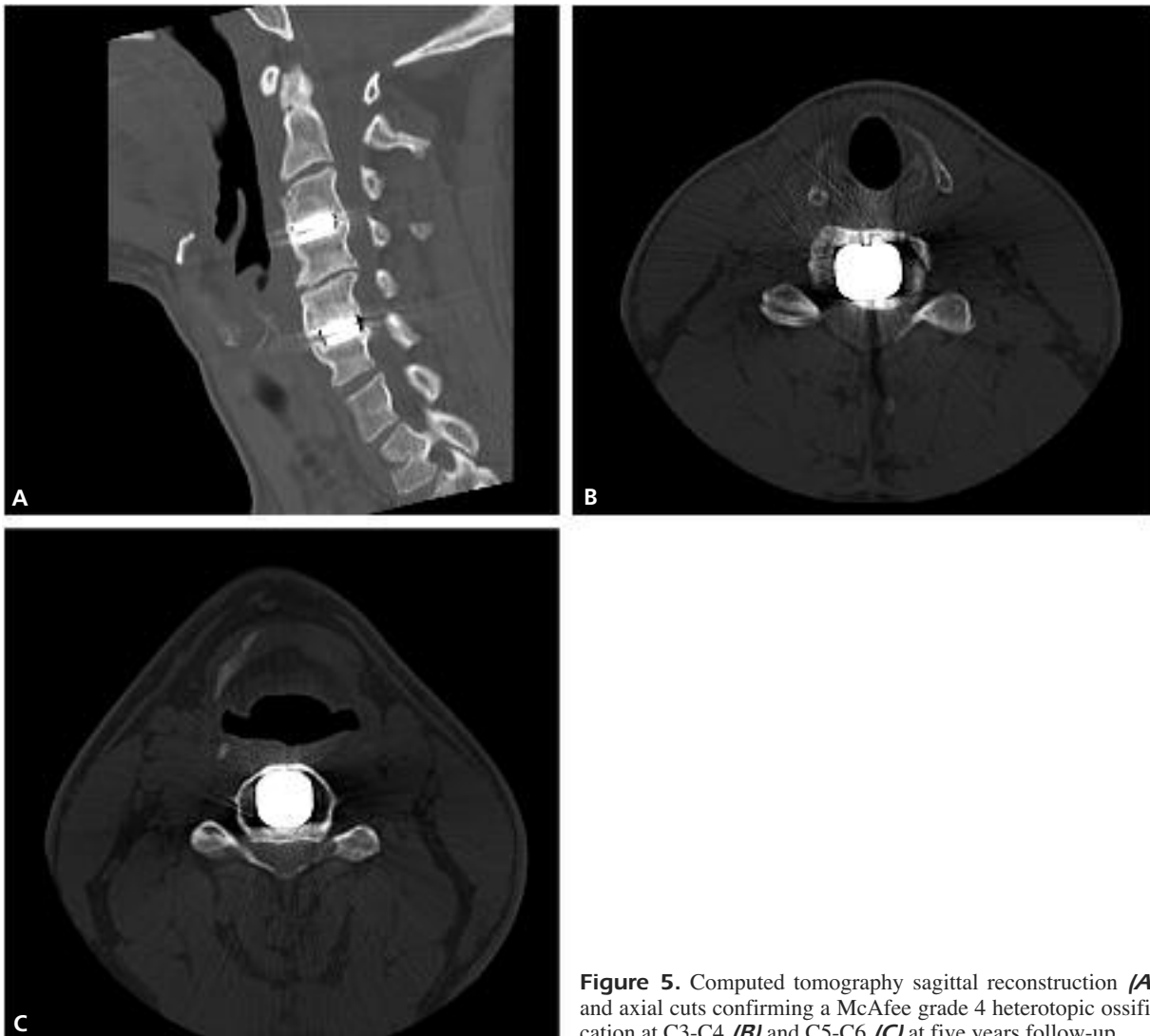

Figure 5. Computed tomography sagittal reconstruction (**A**) and axial cuts confirming a McAfee grade 4 heterotopic ossification at C3-C4 (**B**) and C5-C6 (**C**) at five years follow-up.

to the bone⁶³ are factors likely to induce HO. Su-chomel et al⁶⁷ also hypothesized that kyphotic position of the prosthesis can induce an abnormal motion pattern and chronic irritation of surrounding soft structures, with following HO formation.

HO in ADR patients has been documented at one-^{66,68-74} two-⁷⁵⁻⁷⁸, three^{26,79,80} and four⁶⁷ year follow-up intervals.

Several authors reported the use non-steroidal anti-inflammatory drugs (NSAID) after cervical TDR to prevent the onset of HO, with different results. The unclear benefit reported in some studies^{62,64,72,76,80} is partially counterbalanced by others^{66,71,78,81}. We did not give steroids to our patient.

Arthroplasty is a technique purportedly indicated to prevent loss of vertebral motion and fusion-induced adjacent segment disease; however, our experience with the present case suggests that unexpected, or undesirable, events (i.e. HO) can lead to the loss of expected benefits. Our patient did not have any contraindication to arthroplasty, neither he showed risk factors for HO. However, the unforeseen evolution with grade 4 HO made null our efforts to preserve motion in a young patient. We hypothesized that a hybrid construct (i.e. arthroplasty at C3-C4, C5-C6 and pseudoarthrosis at C4-C5) could result in a better option than a 3-level fusion, as also witnessed by our⁸² and others^{78,83} experience. Nonetheless, it is conceivable that even the extensive 3-level soft tissue dissection in a patient already operated may have induced or triggered the development of HO even on the anterolateral surface of the vertebral bodies, also as a possible consequence of longus colli muscles manipulation. A minimal degree of drilling for the spondylotic changes was performed and bone wax was always used to seal any open bone surface, trying to avoid HO.

Other papers reported the successful use of second-surgery arthroplasty in patients previously treated by ACDF^{25,68}; however, our experience suggests that the role of factors leading to HO, even at a later stage, needs further analysis.

Conclusions

Four conclusions can be drawn from our experience:

1. ASD can occur after ACD without fusion;
2. HO should always be considered by the surgeon planning to perform both TDR and standard, multilevel ACDF.

3. HO can occur even several years after the index procedure;
4. HO is an adverse event, which will need careful observation in the following years in order to better identify suitable candidates for such interesting technique.

Financial Disclosure

None of the Authors has any financial interest in the products cited in this study. No funding from grant-giving organizations or other sources has been or will be received for any aspect of this work.

Conflict of Interest

The Authors declare that there are no conflicts of interest.

References

- 1) BABA H, FURUSAWA N, IMURA S, KAWAHARA N, TSUCHIYA H, TOMITA K. Late radiographic findings after anterior cervical fusion for spondylotic myeloradiculopathy. *Spine* 1993; 18: 2167-2173.
- 2) BERTAGNOLI R, DUGGAL N, PICKETT GE, WIGFIELD CC, GILL SS, KARG A, VOIGT S. Cervical total disc replacement, part two: clinical results. *Orthop Clin North Am* 2005; 36: 355-362.
- 3) CHERUBINO P, BENAZZO F, BORROMEO U, PERLE S. Degenerative arthritis of the adjacent spinal joints following anterior cervical fusion: clinicoradiologic and statistical correlations. *Ital J Orthop Traumatol* 1990; 16: 533-543.
- 4) CHO SK, RIEW KD. Adjacent segment disease following cervical spine surgery. *J Am Acad Orthop Surg* 2013; 21: 3-11.
- 5) GOFFIN J, VAN LOON J, VAN CALENBERGH F, PLETS C. Long-term results after anterior cervical fusion and osteosynthetic stabilization for fractures and/or dislocations of the cervical spine. *J Spinal Disord* 1995; 8: 500-508; discussion 499.
- 6) GOFFIN J, GEUSENS E, VANTOMME N, QUINTENS E, WAERZEGGERS Y, DEPREITERE B, VAN CALENBERGH F, VAN LOON J. Long-term follow-up after interbody fusion of the cervical spine. *J Spinal Disord Tech* 2004; 17: 79-85.
- 7) GORE DR, SEPIC SB. Anterior cervical fusion for degenerated or protruded discs. A review of one hundred forty-six patients. *Spine* 1984; 9: 667-671.
- 8) GORE DR, SEPIC SB. Anterior discectomy and fusion for painful cervical disc disease. A report of 50 patients with an average follow-up of 21 years. *Spine* 1998; 23: 2047-2051.
- 9) HILIBRAND AS, CARLSON GD, PALUMBO MA, JONES PK, BOHLMAN HH. Radiculopathy and myelopathy at segments adjacent to the site of a previous anterior cervical arthrodesis. *J Bone Joint Surg Am* 1999; 81: 519-528.

- 10) HILIBRAND AS, ROBBINS M. Adjacent segment degeneration and adjacent segment disease: the consequences of spinal fusion? *Spine J* 2004; 4: 190S-194S.
- 11) Hilibrand AS, Yoo JU, Carlson GD, Bohlman HH. The success of anterior cervical arthrodesis adjacent to a previous fusion. *Spine* 1997; 22: 1574-1579.
- 12) HUNTER LY, BRAUNSTEIN EM, BAILEY RW. Radiographic changes following anterior cervical fusion. *Spine* 1980; 5: 399-401.
- 13) KATSUURA A, HUKUDA S, SARUHASHI Y, MORI K. Kyphotic malalignment after anterior cervical fusion is one of the factors promoting the degenerative process in adjacent intervertebral levels. *Eur Spine* 2001; 10: 320-324.
- 14) KULKARNI V, RAJSEKHAR V, RAGHURAM L. Accelerated spondylotic changes adjacent to the fused segments following central cervical corpectomy: magnetic resonance imaging study evidence. *J Neurosurg Spine* 2004; 1: 100: 2-6.
- 15) MATSUNAGA S, KABAYAMA S, YAMAMOTO T, YONE K, SAKOU T, NAKANISHI K. Strain on intervertebral discs after anterior cervical decompression and fusion. *Spine* 1999; 24:670-675.
- 16) NUNLEY PD, JAWAHAR A, CAVANAUGH DA, GORDON CR, KERR EJ 3RD, UTTER PA. Symptomatic adjacent segment disease after cervical total disc replacement: re-examining the clinical and radiological evidence with established criteria. *Spine J* 2013; 13: 5-12.
- 17) ROBERTSON JT, PAPADOPOULOS SM, TRAYNELIS VC. Assessment of adjacent-segment disease in patients treated with cervical fusion or arthroplasty: a prospective 2-year study. *J Neurosurg Spine* 2005; 3: 417-423.
- 18) WIGFIELD C, GILL S, NELSON R, LANGDON I, METCALF N, ROBERTSON J. Influence of an artificial cervical joint compared with fusion on adjacent-level motion in the treatment of degenerative cervical disc disease. *J Neurosurg Spine* 2002; 96(1 Suppl): 17-21.
- 19) WU W, THUOMAS KA, HEDLUND R, LESZNIOWSKI W, VAVRUCH L. Degenerative changes following anterior cervical discectomy and fusion evaluated by fast spin-echo MR imaging. *Acta Radiol* 1996; 37: 614-617.
- 20) POSPIECH J, STOLKE D, WILKE HJ, CLAES LE. Intradiscal pressure recordings in the cervical spine. *J Neurosurg* 1999; 44: 379-385.
- 21) WEINHOFER SL, GUYER RD, HERBERT M, GRIFFITH SL. Intradiscal pressure measurements above an instrumented fusion. A cadaveric study. *Spine* 1995; 20: 526-531.
- 22) WIGFIELD CC, SKRZYPIEC D, JACKOWSKI A, ADAMS MA. Internal stress distribution in cervical intervertebral discs: the influence of an artificial cervical joint and simulated anterior interbody fusion. *J Spinal Disord Tech* 2003; 16: 441-449.
- 23) CUMMINS BH, ROBERTSON JT, GILL SS. Surgical experience with an implanted artificial cervical joint. *J Neurosurg* 1998; 88: 943-948.
- 24) DUGGAL N, PICKETT GE, MITSIS DK, KELLER JL. Early clinical and biomechanical results following cervical arthroplasty. *Neurosurg Focus* 2004; 17: 62-68.
- 25) SEKHON LH, SEARS W, DUGGAL N. Cervical arthroplasty after previous surgery: results of treating 24 discs in 15 patients. *J Neurosurg Spine* 2005; 3: 335-341.
- 26) PIMENTA L, McAFEE PC, CAPPUCCINO A, BELLERA FP, LINK HD. Clinical experience with the new artificial cervical PCM (Cervitech) Disc. *Spine J* 2004; 4(6 Suppl): 315S-321S.
- 27) ROBERTSON JT, METCALF NH. Long-term outcome after implantation of the Prestige I disc in an end-stage indication: 4-year results from a pilot study. *Neurosurg Focus* 2004; 17: 69-71.
- 28) WIGFIELD CC, GILL SS, NELSON RJ, METCALF NH, ROBERTSON JT. The new Frenchay artificial cervical joint: results from a two-year pilot study. *Spine* 2002; 27: 2446-2452.
- 29) BARBAGALLO GM, CORBINO LA, PAPAVERO L, FRITZSCHE E, ALBANESE V. Anatomic midline marking during cervical arthroplasty with ProDisc-C: an alternative, simple, and reliable method: technical note. *J Spinal Disord Tech* 2009; 22: 610-614.
- 30) SMITH G, ROBINSON R. The treatment of certain cervical-spine disorders by anterior removal of the intervertebral disc and interbody fusion. *J Bone Joint Surg Am* 1958; 40: 607-624.
- 31) CLOWARD R. The anterior approach for removal of ruptured cervical disks. *J Neurosurg* 1958; 15: 602-617.
- 32) EMERY SE, BOHLMAN HH, MOLESTA MJ, JONES PK. Anterior cervical decompression and arthrodesis for the treatment of cervical spondylotic myelopathy. Two to seventeen-year follow-up. *J Bone Joint Surg Am* 1998; 80: 941-951.
- 33) KAISER MG, HAID RW JR, SUBACH BR, BARNES BR, RODTS GE JR. Anterior cervical plating enhances arthrodesis after discectomy and fusion with cortical allograft. *Neurosurgery* 2002; 50: 229-238.
- 34) MUMMANENI PV, HAID RW. The future in the care of the cervical spine: interbody fusion and arthroplasty. *J Neurosurg Spine* 2004; 2: 155-159.
- 35) CUATICO W. Anterior cervical discectomy without interbody fusion: An analysis of 81 cases. *Acta Neurochir (Wien)* 1981; 57: 269-274.
- 36) DUNSKER SB. Anterior cervical discectomy with and without fusion. *Clin Neurosurg* 1977; 24: 516-521.
- 37) GRISOLI F, GRAZIANI N, FABRIZI AP, PERAGUT AP, VINCEN-TELLI F, DIAZ-VASQUEZ P. Anterior discectomy without fusion for treatment of cervical lateral soft disc extrusion: a follow-up of 120 cases. *Neurosurg* 1989; 24: 853-859.
- 38) HIRSCH C. Cervical disc rupture. Diagnosis and therapy. *Acta Orthop Scand* 1960; 30: 172-186.
- 39) LAUS M, PIGNATTA G, ALFONSO C, MARTELLI C, GIUNTI A. Anterior surgery for the treatment of soft cervical disc herniation. *Chir Organi Mov* 1992; 77: 101-109.
- 40) LUNSFORD LD, BISSONETTE DJ, JANNETTA PJ, SHEPTAK PE, ZORUB DS. Anterior surgery for cervical disc disease: Part-1 treatment of lateral cervical disc herniation in 253 cases. *J Neurosurg* 1980; 53: 1-11.

- 41) MARTINS AN. Anterior cervical discectomy with and without interbody bone graft. *J Neurosurg* 1976; 46: 290-295.
- 42) MURPHY MG, GADO M. Anterior cervical discectomy without interbody bone graft. *J Neurosurg* 1972; 37: 71-74.
- 43) ROSENORN J, HANSEN EB, ROSENORN M. Anterior cervical discectomy with and without fusion. A prospective study. *J Neurosurg* 1983; 59: 252-255.
- 44) SAVOLAINEN S, RINNE J, HERNESNIEMI J. A prospective randomized study of the anterior single-level cervical disc operations with long-term follow-up: surgical fusion is unnecessary. *Neurosurgery* 1998; 43: 51-55.
- 45) WATTERS WC III, LEVINTHAL R. Anterior cervical discectomy with and without fusion: results, complications, and long-term follow-up. *Spine* 1994; 19: 2343-2347.
- 46) WILSON DH, CAMPBELL DD. Anterior cervical discectomy without bone graft. *J Neurosurg* 1977; 35: 551-555.
- 47) YAMAMOTO I, IKEDA A, SHIBUYA N, TSUGANE R, SATO O. Clinical long-term results of anterior discectomy without interbody fusion for cervical disc disease. *Spine* 1991; 16: 272-279.
- 48) LUNSFORD LD, BISSONETTE DJ, ZORUB DS. Anterior surgery for cervical disc disease: Part-2 treatment of cervical spondylotic myelopathy in 32 cases. *J Neurosurg* 1980; 53: 12-19.
- 49) ABD-ALRAHMAN N, DOKMAK AS, ABOU-MADAWI A. Anterior cervical discectomy (ACD) versus anterior cervical fusion (ACF), clinical and radiological outcome study. *Acta Neurochir (Wien)* 1999; 141: 1089-1092.
- 50) SAVOLAINEN S, RINNE J, HERNESNIEMI J. A prospective randomized study of the anterior single-level cervical disc operations with long-term follow-up: surgical fusion is unnecessary. *Neurosurgery* 1998; 43: 51-55.
- 51) DI ANGELO DJ, FOLEY KT, MORROW BR, SCHWAB JS, SONG J, GERMAN JW, BLAIR E. In vitro biomechanics of cervical disc arthroplasty with Prodisc-C total disc implant. *Neurosurg Focus* 2004; 17: 44-54.
- 52) LAXER E, MURREY D, NUSSMAN D, DUNCAN J, DARDEN B, CLAYTOR B. A cadaveric study comparing the effect of an artificial cervical disc versus anterior cervical simulated fusion on adjacent segment disc pressures (Abstract). *Proceedings of the 2005 Spinal Arthroplasty Society, New York, USA, SAS5*, p. 92.
- 53) ISHIHARA H, KANAMORI M, KAWAGUCHI Y, NAKAMURA H, KIMURA T. Adjacent segment disease after anterior cervical interbody fusion. *Spine J* 2004; 4: 624-628.
- 54) FONG SY, DUPLESSIS SJ, CASHA S, HURLBERT RJ. Design limitations of Bryan disc arthroplasty. *Spine J* 2006; 6: 233-241.
- 55) LAWRENCE BD, BRODKE DS. Posterior surgery for cervical myelopathy: indications, techniques and outcomes. *Orthop Clin North Am* 2012; 43: 29-40.
- 56) BERTAGNOLI R, YUE JJ, PFEIFFER F, FENK-MAYER A, LAWRENCE JP, KERSHAW T, NANIEVA R. Early results after ProDisc-C cervical disc replacement. *J Neurosurg Spine* 2005; 2: 403-410.
- 57) CORIC D, CASSIS J, CAREW JD, BOLTES MO. Prospective study of cervical arthroplasty in 98 patients involved in 1 of 3 separate investigational device exemption studies from a single investigational site with a minimum 2-year follow-up. *J Neurosurg Spine* 2010; 13: 715-721.
- 58) CORIC D, FINGER F, BOLTES P. Prospective randomized controlled study of the Bryan Cervical Disc: early clinical results from a single investigational site. *J Neurosurg Spine* 2006; 4: 31-35.
- 59) DU J, LI M, MENG H, HE Q, LUO Z. Early follow-up outcomes after treatment of degenerative disc disease with the discover cervical disc prosthesis. *Spine J* 2011; 11: 281-289.
- 60) SASSO RC, ANDERSON PA, RIEW KD, HELLER JG. Results of Cervical arthroplasty compared with anterior discectomy and fusion: four-year clinical outcomes in a prospective, randomized controlled trial. *J Bone Joint Surg Am* 2011; 93: 1684-1692.
- 61) PICKETT GE, SEKHON LH, SEARS WR, DUGGAL N. Complications with cervical arthroplasty. *J Neurosurg Spine* 2006; 4: 98-105.
- 62) BARTELS RH, DONK R. Fusion around cervical disc prosthesis: case report. *Neurosurgery* 2005; 57: E194.
- 63) EKELUND A, BROSIJO O, NILSSON OS. Experimental induction of heterotopic bone. *Clin Orthop Relat Res* 1991; 263: 102-112.
- 64) PARKINSON J, SEKHON LH. Cervical arthroplasty complicated by delayed spontaneous fusion. *J Neurosurg Spine* 2005; 2: 377-380.
- 65) BERTAGNOLI R. Heterotopic ossification at the index level after Prodisc-C surgery: what is the clinical relevance? Presented at the first Global Spine Congress, San Francisco, USA, 2009.
- 66) MEHREN C, SUCHOMEL P, GROCHULLA F, BARSA P, SOURKOVA P, HRADIL J, KORGE A, MAYER HM. Heterotopic ossification in total cervical artificial disc replacement. *Spine* 2006; 31: 2802-2806.
- 67) SUCHOMEL P, JURÁK L, BENES V 3RD, BRABEC R, BRADÁČ O, ELGAWHARY S. Clinical results and development of heterotopic ossification in total cervical disc replacement during a 4-year follow-up. *Eur Spine J* 2010; 19: 307-315.
- 68) CARDOSO MJ, ROSNER MK. Multilevel cervical arthroplasty with artificial disc replacement. *Neurosurgery Focus* 2010; 28: E19.
- 69) GOFFIN J, VAN CALENBERGH F, VAN LOON J, CASEY A, KEHR P, LIEBIG K, LIND B, LOGROSCINO C, SGRAMBIGLIA R, POINTILLART V. Intermediate follow-up after treatment of degenerative disc disease with the Bryan Cervical Disc Prosthesis: single-level and bi-level. *Spine* 2003; 28: 2673-2678.
- 70) LAFUENTE J, CASEY ATH, PETZOLD A, BREW S. The Bryan cervical discs prosthesis as an alternative to arthrodesis in the treatment of cervical

- spondylosis. *J Bone Surgery (Br)* 2005; 87-B: 508-512.
- 71) LEE JH, JUNG TG, KIM HS, JANG JS, LEE SH: Analysis of the incidence and clinical effect of the heterotopic ossification in a single-level cervical artificial disc replacement. *Spine J* 2010; 10: 676-682.
- 72) LEUNG C, CASEY ATH, GOFFIN J, KEHR P, LIEBIG K, LIND B, LOGROSCINO C, POINTILLART V. Clinical significance of heterotopic ossification in cervical disc replacement: a prospective multi center clinical trial. *Neurosurgery* 2005; 57: 759-763.
- 73) YI S, KIM KN, YANG MS, YANG JW, KIM H, HA Y, YOON DO H, SHIN HC. Difference in occurrence of heterotopic ossification according to prosthesis type in the cervical artificial disc replacement. *Spine* 2010; 35: 1556-1561.
- 74) TIAN W, HAN X, LIU B, LI Q, HU L, LI ZY, YUAN Q, HE D, XING YG. Clinical and radiographic results of cervical artificial disc arthroplasty: over three years follow-up cohort study. *Chinese Med J* 2010; 123: 2969-2973.
- 75) BEAURAIN J, BERNARD P, DUFOUR T, FUENTES JM, HOVORKA I, HUPPERT J, STEIB JP, VITAL JM, AUBOURG L, VILA T. Intermediate clinical and radiological results of cervical TDR (Mobi-C®) with up to 2 years of follow-up. *Eur Spine J* 2009; 18: 841-850.
- 76) HEIDECKE V, BURKERT W, BRUCKE M, RAINOV NG. Intervertebral disc replacement for cervical degenerative disease – clinical results and functional outcome at two years in patients implanted with the Bryan cervical disc prosthesis. *Acta Neurochir* 2008; 150: 453-459.
- 77) LEE SE, CHUNG CK, JAHNG TA. Early development and progression of heterotopic ossification in cervical total disc replacement. *J Neurosurg Spine* 2012; 16: 31-36.
- 78) RYU KS, PARK CK, JUN SC, HUH HY. Radiological changes of the operated and adjacent segments following cervical arthroplasty after a minimum 24-month follow-up: comparison between the Bryan and Prodisc-C devices. *J Neurosurg Spine* 2010; 13: 299-237.
- 79) SOLA S, HEBECKER R, KNOOP M, MANN S. Bryan cervical disc prosthesis--three years follow-up. *Eur Spine J* 2005; 14(Suppl 1): 38.
- 80) TU T, WU J, HUANG W, GUO W, WU CL, SHIH YH, CHENG H. Heterotopic ossification after cervical total disc replacement: determination by CT and effects on clinical outcomes. *J Neurosurg Spine* 2011; 14: 457-465.
- 81) HELLER JG, SASSO RC, PAPADOPOULOS SM, ANDERSON PA, FESSLER RG, HACKER RJ, CORIC D, CAUTHEN JC, RIEW DK. Comparison of BRYAN cervical disc arthroplasty with anterior cervical decompression and fusion: clinical and radiographic results of a randomized, controlled, clinical trial. *Spine (Phila Pa 1976)* 2009; 34: 101-107.
- 82) BARBAGALLO GM, ASSIETTI R, CORBINO L, OLINDO G, FOTI PV, RUSSO V, ALBANESE V. Early results and review of the literature of a novel hybrid surgical technique combining cervical arthrodesis and disc arthroplasty for treating multilevel degenerative disc disease: opposite or complementary techniques? *Eur Spine J* 2009; 18(Suppl 1): 29-39.
- 83) CARDOSO MJ, MENDELSON A, ROSNER MK. Cervical hybrid arthroplasty with 2 unique fusion techniques. *J Neurosurg Spine* 2011; 15: 48-54.