

Received:
09 November 2020

Revised:
20 April 2021

Accepted:
12 May 2021

© 2021 The Authors. Published by the British Institute of Radiology under the terms of the Creative Commons Attribution-NonCommercial 4.0 Unported License <http://creativecommons.org/licenses/by-nc/4.0/>, which permits unrestricted non-commercial reuse, provided the original author and source are credited.

Cite this article as:

Manganaro L, Nicolino GM, Dolciemi M, Martorana F, Stathis A, Colombo I, et al. Radiomics in cervical and endometrial cancer. *Br J Radiol* 2021; **94**: 20201314.

REVIEW ARTICLE

Radiomics in cervical and endometrial cancer

¹LUCIA MANGANARO, ²GABRIELE MARIA NICOLINO, ¹MIRIAM DOLCIAMI, ³FEDERICA MARTORANA, ^{3,4}ANASTASIOS STATHIS, ³ILARIA COLOMBO and ^{4,5}STEFANIA RIZZO, MD

¹Department of Radiological, Oncological and Pathological Sciences; University of Rome Sapienza (IT), Rome, Italy

²Post-graduate School in Radiodiagnosics, Università degli Studi di Milano, Via Festa del Perdono 7, Milan, Italy

³Oncology Institute of Southern Switzerland, San Giovanni Hospital, 6500 Bellinzona, (CH), Switzerland

⁴Facoltà di Scienze biomediche, Università della Svizzera italiana (USI), Via Buffi 13, 6900, Lugano (CH), Switzerland

⁵Istituto di Imaging della Svizzera Italiana (IIMI), Ente Ospedaliero Cantonale, Via Tesserete 46, Lugano (CH), Switzerland

Address correspondence to: PDdr Stefania Rizzo

E-mail: stefania.rizzo@eoc.ch

ABSTRACT

Radiomics is an emerging field of research that aims to find associations between quantitative information extracted from imaging examinations and clinical data to support the best clinical decision. In the last few years, some papers have been evaluating the role of radiomics in gynecological malignancies, mainly focusing on ovarian cancer. Nonetheless, cervical cancer is the most frequent gynecological malignancy in developing countries and endometrial cancer is the most common in western countries. The purpose of this narrative review is to give an overview of the latest published papers evaluating the role of radiomics in cervical and endometrial cancer, mostly evaluating association with tumor prognostic factors, with response to therapy and with prediction of recurrence and distant metastasis.

INTRODUCTION

Personalized medicine is paving the way towards tailored and individualized treatments based on the clinical and, more recently, genetic characteristics of cancer patients.

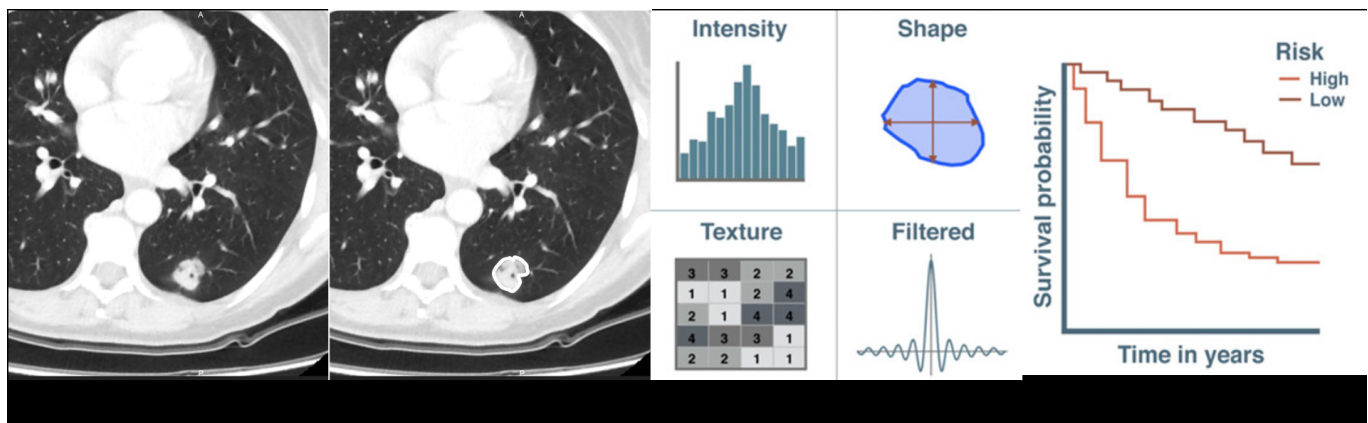
Traditionally, radiologists evaluate clinical images according to qualitative features, based on their training and experience in order to provide a diagnosis or an assessment of a clinical state.¹ Radiomics represents a recently introduced translational field of research aiming to find associations between quantitative information extracted from imaging examinations and clinical data to support the best clinical decision. So far, few studies have evaluated the associations between radiomics and prognosis of gynecological malignancies, such as cervical and endometrial cancer. The purpose of this narrative review is to give a quick overview on radiomics, to place into context the available data on radiomics in cervical and endometrial cancer.

Radiomics

The concept underlying the textural analysis is that, irrespectively of expressing a mass density (for CT), a Signal Intensity (for MR) or Standardized Uptake Value (for PET), the information contained in each voxel of a radiological image may reflect the underlying pathophysiology of the tumor tissue.

The radiomics workflow includes the following distinct steps: image acquisition and reconstruction; image segmentation; features extraction and qualification; analysis and model building^{2,3} (Figure 1). Image acquisition and reconstruction is the first step to extract values from the images, although it is not strictly related to radiomics. Image parameters, such as tube voltage, slice thickness, tube current and others should ideally not have an impact on the values used to infer the textural features. However, it has been demonstrated that some of these parameters affect textural features, and therefore preliminary analysis should help in selection of robust and reproducible features.⁴ Segmentation refers to the tracing of the borders within the radiomics features will be extracted. Segmentation can rely on manual, semi-automatic or automatic methods, being each one associated with its pros and cons, related to a balance between reproducibility and correspondence to the real margins of the lesion. Many authors consider manual segmentation by expert readers as ground truth. However, it suffers from high inter-reader variability and it is labor intensive, thus, it is not always feasible for radiomics analysis requiring very large data sets.⁵ As previously described,² common requirements for segmentation methods include as high automaticity as possible, with minimum operator interaction; time efficiency; accuracy and boundaries reproducibility. Among the most common

Figure 1. Main steps of a radiomics study.



segmentation algorithms, there are region-growing methods, requiring an operator to select a seed point within the volume of interest⁶; level set methods, representing a contour as the zero level set of a higher dimensional function (level set function); graph cut methods constructing an image-based graph⁷; active contours (snake) algorithms, working as stretched elastic bands. Although the existence of many different segmentation methods, there is still no universal segmentation algorithm that work well for all medical image applications. Indeed, some features may show stability and reproducibility by using one segmentation method and may not be the same by using another.

After segmentation, usually made in three dimensions, the next step is the extraction of the features. Traditional features are semantic, indicating a descriptive common lexicon (size, shape margins etc). Quantitative features, typical for radiomics studies, can show different levels of complexity, going from first order statistics features (e.g. mean, median, maximum, minimum, and uniformity or randomness of the values on the image, as well as the skewness and kurtosis of the histogram of values) to second-order statistics features, expressing intralesional heterogeneity such as the ones included in matrices (e.g. the grey level co-occurrence matrix, GLCM; the grey level run length matrix, GLRLM and so on) to higher order statistics features, generated by statistical methods after imposing filter grids on the image to extract repetitive or non-repetitive patterns (e.g. fractal analyses; Minkowski functionals; wavelets and so on). With all the features extracted, radiomics analysis usually includes dimensionality reduction and feature selection, and then association analysis with one or more specific outcome. The many different analysis approaches depend on the purpose of the study and the outcome category, ranging from statistical methods to data mining/machine learning approaches, such as random forests, neural networks, linear regression, logistic regression, least absolute shrinkage and selection operator and Cox proportional hazards regression.^{2,8,9}

Many studies evaluated the association between radiomics and prognosis in different tumors¹³.

In gynecological malignancies, some data exist in evaluation of texture analysis in ovarian cancer, demonstrating that some

quantitative metrics, capturing spatial imaging heterogeneity, may be related to short overall survival and incomplete surgical resection.¹⁰⁻¹⁴ Furthermore, Meier et al demonstrated that high inter site entropy might be related with shorter progression free survival.¹⁵ More recently, Beer et al¹⁶ have provided the first insights into the potential association between CT imaging traits, texture measures of tumor burden heterogeneity and the abundance of several tumor-associated proteins. The authors demonstrated that an integrated analysis of transcriptomic and proteomic data was able to identify four proteins associated with CT-based imaging traits.

METHODS AND MATERIALS

Starting in September 2020, a structured search using PubMed database was performed and included all relevant original articles and reviews, published in and after 2010. The search used the following key word combinations: [(uterus) OR (uterine) OR (cervix) OR (cervical) OR (endometrium) OR (endometrial)) AND ((tumour) OR (tumoral) OR (cancer) OR (neoplasm)) AND ((radiomic) OR (radiomics) OR (texture) OR (textural))]. Data extraction was independently performed by two reviewers (SR and LM) and any disagreement was discussed with a third reviewer (MD).

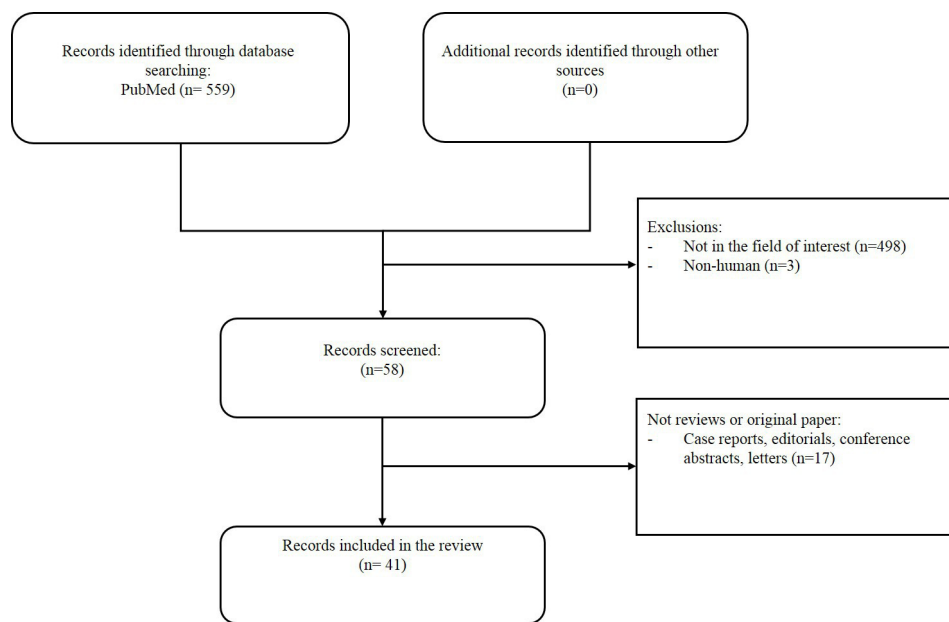
All papers published on human subjects were included. Citations and references of the retrieved studies were used as additional sources. Reviews, case reports, editorial comments, conference abstracts and short communications were excluded.

RESULTS

As shown in [Figure 2](#), the literature search found a total of 559 articles. Ultimately, 41 articles were deemed relevant and used as the literature basis of this review (cervical cancer, $n = 31$; endometrial cancer, $n = 10$). Regarding the selected studies on radiomics in cervical cancer imaging, 6 were prospective and 25 retrospective, including one multicentre; 21 applied radiomics to MR, 5 to PET/CT, 2 to both MR and PET/CT, 2 to CT and 1 to ultrasound ([Table 1](#)). Concerning endometrial cancer, 2 of the 10 selected studies were prospective and 8 were retrospective; 7 applied radiomics to MR and 3 to PET/CT ([Table 2](#)).

The flow chart of the selection process is shown in [Figure 2](#).

Figure 2. Flow-chart showing study selection.



Radiomics in cervical cancer

Cervical cancer (CC) is the fourth most common and cancer-related mortality cause in females, with the highest incidence in developing countries.⁵⁸

Although CC incidence is decreasing thanks to human papilloma virus screening and vaccination programs, it continues to be a major public health problem with over half a million new cases per year and around 300,000 deaths per year.^{59,60} Multiple treatment strategies are available, and the best therapeutic choice is mainly based on various prognostic risk factors.^{61,62} Surgery is the gold-standard for the management of early-stage cervical cancer (International Federation of Gynecology and Obstetrics-FIGO IA1-IIA2), while patients with locally advanced cervical cancer (LACC; FIGO stage IIB-IVA) usually require a multi-modality approach, with platinum-based concurrent chemoradiation therapy (CCRT) as standard treatment.^{63–65}

Despite the available treatment options, 5 year overall survival rate is about 66%, with significant differences according to FIGO stage, being 92% in early stages, 56% in LACC and 17% in metastatic disease.^{66,67}

Multiple diagnostic imaging modalities exist for the diagnosis and staging of CC including ultrasound, CT, MR, [¹⁸F]- fludeoxyglucose (FDG) PET, with the latter two playing an essential role in assessing local and distant disease spread and in evaluating response to treatment.

Initial studies on radiomics applied to CC were published in 2013–2016 and focused mainly on potential applications in nuclear medicine.^{17,18} In 2013 Yang et al¹⁸ firstly investigated the heterogeneity in the temporal behavior of intratumoral [¹⁸F]-FDG accumulation in patients with CC undergoing CCRT,

finding significant differences between patients with complete response and patients with partial response or non-responders.

From 2017 onwards, radiomics applied to CC has become increasingly popular, requiring reproducibility studies to assess inter- and intraobserver variability and robustness of features.^{19,68} Currently, radiomics has been applied as investigation tool to CC for identification of tumor prognostic factors, evaluation of response to therapy and prediction of tumor recurrence and distant metastasis.

Tumor prognostic factors

- Histology

Many prognostic factors in cervical cancer can be obtained from histologic examination (such as revised FIGO tumor stage at diagnosis, tumor size, depth of tumor invasion, lymphovascular space invasion-LVSI and histological subtype and grade) and they have all been a major subject of research in the radiomics field.^{20,61}

In 2017, Tsujikawa et al²¹ investigated the ability of texture analysis applied to PET/CT images in identifying differences in histological architecture of different CC subtypes. They found that among the 18 features extracted from PET/CT, the only variable capable of reliably discriminating between squamous cell carcinomas (SCCs) and non-squamous cell carcinomas (NSCCs) was the second-order feature *Correlation*, derived from NGLCM. In contrast, Wu et al²² aiming to predicting several prognostic factors in CC, applied radiomic analysis to multiparametric MR, which included T_2 weighted images (T_2 WI) with and without fat suppression (FS), diffusion-weighted images (DWI) and dynamic contrast enhanced (DCE) images. Referring to differentiation grade (G), they observed that all textural maps obtained from T_2 - and T_2 FS-WI, apparent diffusion coefficient (ADC)

Table 1. Main information about the articles included for assessment of radiomics in cervical cancer.

| Authors | Year | Study design | Number of patients | Imaging technique | Texture features | Main conclusions | Software |
|-------------------------------|------|--------------|--------------------|-------------------|---------------------------------|---|-------------------------------------|
| Mu et al ¹⁷ | 2015 | R | 42 | PET/CT | First, and higher order | Intratumor tracer uptake heterogeneity on baseline PET/CT is associated with tumor stage. | nd |
| Yang et al ¹⁸ | 2013 | R | 20 | PET/CT | First, and higher order | Intratumor uptake heterogeneity may help understanding tumor response to CCRT. | nd |
| Lin ¹⁹ | 2019 | R | 169 | MR | First, and higher order | Deep learning can perform accurate localization and segmentation of CC in DWI MR. | MR Radiomics Platform |
| Guan et al ²⁰ | 2017 | P | 70 | MR | First, and higher order | ADC first-order statistics and texture features proved relevant in clinical staging of CC. | nd |
| Tsujikawa et al ²¹ | 2017 | R | 83 | PET/CT | First, and higher order | PET/CT textural features may reflect the differences in histological architecture between CC subtypes. | CGITA MATLAB |
| Wu et al ²² | 2019 | R | 56 | MR | First, and higher order | ADC maps show the best performance for LN metastases; Ve maps show the best value for LVSI and tumor grade. | nd |
| Liu et al ²³ | 2018 | P | 160 | MR | First, and higher order | High-dimensional and quantitative image features are insensitive to tumor delineations. | MATLAB |
| Wormald et al ²⁴ | 2019 | P | 378 | MR | Second-order features | Textural features from ADC maps and T2-W images may predict recurrence in low-volume tumors. | MATLAB |
| Li et al ²⁵ | 2019 | R | 105 | MR | First, and higher order | T1CE MR-based radiomics nomogram may predict LVSL. | Python |
| Jiang et al ²⁶ | 2019 | R | 167 | MR | First, and higher order | Deep learning-based radiomics may predict vessel invasion. | Python |
| Li et al ²⁷ | 2020 | R | 62 | MR | Second-order features features. | Combination of DCE-MRI and texture analysis improved sensitivity in parametrial infiltration. | ITK-SNAP software and O.K. software |

(Continued)

Table 1. (Continued)

| Authors | Year | Study design | Number of patients | Imaging technique | Texture features | Main conclusions | Software |
|-----------------------------|------|--------------|--------------------|-------------------|-------------------------|--|-------------|
| Wang et al ²⁸ | 2020 | R | 137 | MR | First, and higher order | A radiomics nomogram performed well for the preoperative prediction of parametrial invasion in early CC. | MATLAB |
| Shen ²⁹ | 2017 | R | 170 | PET/CT | First, and higher order | LN metastases can be predicted by textural higher order features of homogeneity. | nd |
| Becker et al ³⁰ | 2017 | P | 23 | MR | First, and higher order | Texture features may predict histological tumor differentiation and nodal cancer stage. | MATLAB |
| Kan et al ³¹ | 2019 | R | 143 | MR | First, and higher order | MR radiomic signature can be used as a biomarker for preoperative assessment of LN. | MATLAB |
| Wang et al ³² | 2019 | R | 96 | MR | First, and higher order | A radiomics nomogram based on T2WI and DWI improved the prediction of LN. | MATLAB |
| Wu et al ³³ | 2019 | R | 189 | MR | First, and higher order | A radiomics model from intratumoral and peritumoral tissue of T2W can predict LN status in LACC. | PyRadiomics |
| Xiao et al ³⁴ | 2020 | R | 233 | MR | First, and higher order | A radiomics nomogram may facilitate the prediction of LN in patients with early-stage CC. | Python |
| Jin et al ³⁵ | 2020 | R | 172 | US | First, and higher order | A radiomic model predicted LN metastases based on preoperative ultrasound images. | LIFEX |
| Chen et al ³⁶ | 2020 | R | 150 | CT | First and higher order | A CT radiomic model, combining two radiomic features and the FIGO stage predicted the LN status in early stage CC. | nd |
| Ciolina et al ³⁷ | 2019 | R | 28 | MR | First, and higher order | TA applied to T2-W MR sequences may differentiate adenocarcinoma from SCC and may predict response to NACT in LACC | TexRAD |

(Continued)

Table 1. (Continued)

| Authors | Year | Study design | Number of patients | Imaging technique | Texture features | Main conclusions | Software |
|-----------------------------------|------|---------------|--------------------|-------------------|-----------------------------------|--|---------------|
| Sun <i>et al</i> ³⁸ | 2019 | R Multicentre | 275 | MR | First, and higher order | MR-based radiomic features may predict response to NACT in LACC. | MATLAB |
| Fang <i>et al</i> ³⁹ | 2020 | R | 120 | MR | First, and higher order | A radiomic model may predict treatment response before CCRT in patients with LACC. | MATLAB |
| Tian <i>et al</i> ⁴⁰ | 2020 | R | 277 | CT | First, and higher order | A CT-based radiomic combined model well predicted NACT response. | MATLAB |
| Reuzé <i>et al</i> ⁴¹ | 2017 | R | 118 | PET/CT | First, and higher order | Radiomic features may predict local recurrence of LACC. | nd |
| Meng <i>et al</i> ⁴² | 2017 | P | 36 | MR | First, and higher order | Pre- and mid-treatment whole-lesion ADC histogram and texture analysis may predict tumor recurrence of LACC treated with CCRT. | nd |
| Meng <i>et al</i> ⁴³ | 2018 | P | 34 | MR | First, and higher order | T2 and ADC textural may predict recurrence in LACC treated with CCRT. | IBEX software |
| Lucia <i>et al</i> ⁴⁴ | 2017 | R | 102 | PET/CT MR | First, and higher order | Radiomics features from FDG/PET and ADC maps may serve as independent prognostic factors for outcome in LACC. | nd |
| Lucia <i>et al</i> ⁴⁵ | 2018 | R | 190 | PET/CT MR | First, and higher | Validation of previously developed radiomics models in two independent external cohorts. | nd |
| Fang <i>et al</i> ⁴⁶ | 2020 | R | 248 | MR | First, and higher | A MR derived Rad-score can be used as a prognostic biomarker for patients with early-stage CC. | PyRadiomics |
| Takada <i>et al</i> ⁴⁷ | 2020 | R | 87 | MR | Morphology, histogram and texture | Recurrence could be predicted with high accuracy using expanded VOI for CC treated with definitive radiotherapy. | LIFEx |

ADC, Apparent diffusion coefficient; CC, Cervical cancer; CCRT, Concurrent chemo-radiotherapy; DWI, Diffusion weighted imaging; LACC, Locally advanced cervical cancer; LN, Lymph nodes; LVSI, Lymphovascular space invasion; MR, Magnetic Resonance; NACT, Neoadjuvant chemotherapy; PET/CT, Positron emission tomography/Computed tomography; PMI, Parametrial invasion; R, Retrospective; SCC, squamous cell carcinoma; TA, Texture analysis; VOI, volume of interest; *p*, Prospective.

from DWI, Ktrans, Ve and Vp from DCE images showed a statistically significant difference in distinguishing between G2 and G3 tumors, with Ve maps showing the best discriminating value. In 2018, Liu *et al*²³ evaluated ADC-based radiomic features in assessing the histopathological grade of cervical cancer, specifically looking for significant differences between features obtained

from two-dimensional (2D) center-slice vs three-dimensional (3D) whole-tumor volumetric measurement. They observed that 3D whole-tumor volumetric radiomic analysis had better performance than using the 2D central slice of the tumor in stratifying the histologic grade of cervical cancer.

Table 2. Main information about the articles included for assessment of radiomics in endometrial cancer.

| Authors | Year | Study design | Number of patients | Imaging technique | Texture features | Main conclusions | Software |
|---------------------------------|------|--------------|--------------------|-------------------|------------------------|---|-------------------------------------|
| Wang et al ⁴⁸ | 2019 | R | 170 | PEC/CT | First and higher order | SUVmax and SUVpeak had the highest diagnostic values for EAH, FC, and EC 1a. The addition of texture features provided information for differentiating EAH, FC, and EC 1a | Artificial Intelligent Kit software |
| Ueno et al ⁴⁹ | 2017 | R | 137 | MR | First order | The mathematical models that incorporated MR imaging-based texture features were associated with the presence of DMI, LVSI, and high-grade tumor | TexRAD |
| Ghosh et al ⁵⁰ | 2019 | P | 27 | MR | First order | Diffusion tensor histogram analysis can better evaluate DMI and tumor type | 3D Slicer |
| Stanzione et al ⁵¹ | 2020 | R | 54 | MR | First and higher order | A radiomics-powered machine learning model for DMI detection increased the radiologist performance from 82 to 100% | PyRadiomics |
| Ytre-Huage et al ⁵² | 2018 | P | 180 | MR | First order | MR texture parameters independently predicted DMI, high-risk histological subtype and reduced survival | TexRAD |
| De Bernardi et al ⁵³ | 2018 | R | 115 | PET/CT | First and higher order | The computation of imaging features on the primary tumour increases nodal staging detection sensitivity in PET/CT | CGITA software |
| Crivellaro et al ⁵⁴ | 2020 | R | 167 | PET/CT | First and higher order | PET/CT demonstrated high specificity (94%) in detecting nodal metastases | nd |
| Xu et al ⁵⁵ | 2019 | R | 200 | MR | First and higher order | A model based on radiomic and clinical features showed a good discrimination of positive LN, especially for normal-sized LN | Python (Version 3.6.5) |
| Yan et al ⁵⁶ | 2020 | R | 622 | MR | First and higher order | Higher diagnostic performance and clinical net benefits for a radiomics-aided model than for the radiologists alone | |
| Yan et al ⁵⁷ | 2020 | R | 717 | MR | First and Higher order | The radiomics nomogram exhibited good performance in the individual prediction of high-risk EC | Pyradiomics |

(Continued)

Table 2. (Continued)

| Authors | Year | Study design | Number of patients | Imaging technique | Texture features | Main conclusions | Software |
|---------|------|--------------|--------------------|-------------------|------------------|------------------|----------|
|---------|------|--------------|--------------------|-------------------|------------------|------------------|----------|

DMI, deep myometrial invasion; EAH, endometrial atypical hyperplasia; EC, Endometrial Carcinoma; FC, Field cancerization; LN, lymph nodes; LVSI, lymphovascular invasion; MR, Magnetic Resonance; PET/CT, Positron emission tomography/Computed tomography; R, retrospective; SUV, standardized uptake value; nd, not declared; p, prospective.

By applying texture analysis on T_2 WI images and ADC data of 378 patients with Stage I-II of CC, Wormald et al²⁴ found significant differences between the radiomics features, including dissimilarity, energy, cluster prominence, cluster shade, inverse variance, autocorrelation, between cervical tumors above and below the volume threshold of eligibility for trachelectomy.

Li et al²⁵ developed and internally validated an MR-based radiomics nomogram for predicting LVSI by combining red blood cell counts with the radiomic signature consisting of three features. More recently, by applying convolutional neural network-based radiomic methods on DCE- T_1 and T_2 WI MR images, Jiang et al²⁶ used dynamic contrast-enhanced T_1 - and T_2 WI of 167 MR of early-stage CC patients, to build and validate a deep learning-based radiomics model to predict vascular infiltration in early-stage CC.

- Parametrial invasion

Much attention has been given to parametrial invasion (FIGO Stage IIB) which represents a turning point in the differentiation between early and locally advanced disease with significant implications for the therapeutic management. Recently, Li et al²⁷ investigated the possibility of predicting parametrial invasion by using a combination of features extracted from DCE-MR (k-trans) and texture analysis (energy and entropy, belonging to the first-order statistics features). Contrast-enhanced T_2 WI MR of 105 patients, divided into training and validation cohort with a ratio of 2:1, were evaluated to select three features and one clinical characteristic to be included in a nomogram. Their nomogram was able to discriminate between LVSI and non-LVSI groups, with an AUC of 0.754 (95% confidence interval [CI], 0.6326–0.8745) in the training cohort, and of 0.727 (95% CI, 0.5449–0.9097) in the validation cohort. Wang et al²⁸ developed a radiomics nomogram, integrating the radiomics signatures obtained from combined T_2 WI and DWIs with patient's age and pathological grade, showing an excellent discrimination between patients with and without parametrial invasion.

- Lymph node status

The presence of pelvic and para-aortic lymph node metastases has a prognostic significance, and its detection is paramount to define the best treatment option. This is also highlighted in the 2018 revised FIGO classification system, which currently assigns Stage "IIIC" to females with positive pelvic or para-aortic lymph nodes.¹⁶ Standard diagnostic methods have several limitations in assessing lymph node status, especially in detecting micrometastases in normal-sized lymph nodes.⁶⁹ Also, systematic pelvic lymph node dissection presents major complications and is not

indicated in every patient.^{70,71} Therefore, a new non-invasive diagnostic method might help in this setting.

Shen et al²⁹ investigated the use of texture analysis on primary tumour [18 F]-FDG PET images in evaluating lymph node status, finding a significant association between positive pelvic or para-aortic lymph nodes and features from GLCM and total lesion glycolysis.

The first study investigating radiomics applied to MR in evaluating lymph node status in CC was published by Becker et al³⁰ in 2017. By extracting texture features from a polygonal ROI drawn on the primary lesion at baseline pelvic MR, they found that higher skewness or kurtosis (belonging to the first-order statistics features) in the main tumor were associated with lymph nodes involvement. Using a support-vector machines algorithm, belonging to higher order statistics features, Kan et al³¹ constructed a radiomic model on a study cohort of 100 patients, then validated on a cohort of 43 patients able to predict nodal status in patients with early-stage CC using features extracted after manual segmentation from T_2 WI and enhanced T_1 WI. Accordingly, Wang et al³² used similar methods, based on support-vector machine on manually segmented T_2 WI and DWI, in a cohort of 96 patients including a validation group, to demonstrate that a radiomics nomogram integrating the radiomics signature with clinicopathologic risk factors showed a significant improvement over the nomogram based only on clinicopathologic risk factors in the primary cohort (C-index, 0.893 vs 0.616; $p = 4.311 \times 10^{-5}$) and validation cohort (C-index, 0.922 vs 0.799; $p = 3.412 \times 10^{-2}$). Wu et al³³ performed a study including 189 patients, divided into training ($n = 126$) and validation ($n = 63$) cohorts. The authors proposed a decision tree for predicting nodal disease that combines a radiomic model, obtained from T_2 WI of both intratumoral and peritumoral tissue, with the standard morphological evaluation of the lymph nodes on MR. In 2020, Xiao et al³⁴ evaluated 233 patients, divided into a primary cohort ($n = 155$) and a validation cohort ($n = 78$) to develop a radiomic nomogram (obtained by manual delineation of a two-dimensional ROI on the primary tumor), by incorporating the radiomics signature with the MR-reported lymph nodes status and FIGO stage. This model was able to facilitate the prediction of nodal disease in patients with early-stage CC.

Recently, some reports have also shown that there are radiomic features able to predict the lymph node status from ultrasound and from CT images of the primary lesion.^{35,36}

Evaluation of response to therapy

Patients with LACC are not suitable for surgery and the standard treatment of care is platinum-based CCRT. Although this

treatment has led to a significant improvement in locoregional control and overall survival, approximately 40% of patients with LACC experience disease relapse. The large difference in response to therapy is likely linked to clinical and pathologic prognostic factors (such as FIGO stage, tumor size, histological type or grading, parametrial and LVS invasion, nodal status) and also on the phenotypic and genomic tumor characteristics that cannot be revealed by the standard diagnostic methods and their heterogeneity not depicted by random sampling or biopsy.^{63,72}

From 2018, prediction of therapy response and survival has stimulated great interest in radiomics research. In a study of Ciolina et al³⁷ the kurtosis (belonging to the first-order statistics features), extracted from the primary tumor of 28 patients in T_2 WI and ADC maps of baseline MR, was indicated as a predictor of tumor response to platinum-based neoadjuvant chemotherapy (NACT), showing a significantly higher value in responding patients. Sun et al³⁸ retrospectively reviewed 275 LACC patients, divided into training and testing sets with a 2:1 ratio, treated with NACT, that underwent pretreatment MR. By combining features extracted from intratumoral zone of T_1 - and T_2 WI and peritumoral zone of T_2 WI, they constructed a radiomic model, able to accurately predict the response to therapy (AUC of 0.998). Similarly, Fang et al³⁹ studied a cohort of 120 patients (allocated equally into training or test sets), and, by applying three kind of machine learning models, developed a radiomic model based on features extracted from sagittal T_2 WI, axial enhanced T_1 WI and ADC data, which showed good performance in predicting response to CCRT in patients with LACC. Tian et al⁴⁰ performed a retrospective study on 277 LACC patients treated with NACT, divided into training ($n = 221$) and validation ($n = 56$) cohorts. By analyzing multiple texture features obtained from pretreatment CT examination, they selected six significant features to build a radiomic signature which, combined with the patient's age and FIGO stage, showed a high predictive value in evaluating the response to therapy.

Prediction of recurrence and distant metastasis

Local recurrence and distant metastases are the most frequent causes of therapeutic failure and death from CC. Microscopic residual disease represents the most important risk factor and is mostly undetectable with current diagnostic techniques, explaining the high rate of failure after treatment of about 35% in patients with LACC.^{62,73} New reliable diagnostic tools able to predict recurrence and distant metastasis at an early stage are needed, in order to guide therapeutic choice in advance.

In 2017, Reuzé et al⁴¹ investigated the ability of texture analysis applied to baseline [18 F]-FDG PET images of 118 patients, divided into two groups according to the PET scanner used, to predict recurrence in LACC patients treated with CCRT and brachytherapy. Eight radiomics features were statistically significant predictors of local relapse in both groups. Meng et al⁴² enrolled prospectively 36 females with advanced squamous CC to explore the value of whole-lesion ADC histogram and texture analysis in predicting tumor recurrence. The authors demonstrated that pre- and mid-treatment whole lesion ADC histogram and texture analysis hold great potential in predicting tumor recurrence. The following year, the same group prospectively

included 34 patients to explore the application of texture parameters extracted from ADC maps and T_2 WI to predict tumor recurrence of patients with advanced cervical cancers treated with CCRT. The authors demonstrated that the support vector machine classifier using ADC textural parameters performed best in predicting recurrence, while the combination with T_2 WI textural parameters added little value in prognosis.⁴³

Lucia et al in a multicentric study included 102 patients, divided into training ($n = 69$) and test ($n = 33$) groups, to determine if radiomics features from PET/CT and MR could contribute to predict prognosis in cervical cancer. In their multivariate analysis, the authors identified a feature belonging to the GLRLM from PET and a feature belonging to the GLCM from ADC maps of MR as independent prognostic factors. These two features showed significantly higher prognostic power than clinical parameters, as evaluated in the testing cohort with accuracy of 94% for predicting recurrence and 100% for predicting lack of locoregional control (vs ~50–60% for clinical parameters).⁴⁴ In a subsequent study, the same group successfully validated a previously developed PET/MR radiomics predictive model in two independent external cohorts, demonstrating images for prediction of disease-free survival and locoregional control in LACC.⁴⁵ Fang et al⁴⁶ extracted multiple radiomics features from T_2 WI and enhanced T_1 WI on baseline MR in 248 patients, divided into training cohort ($n = 166$) and validation cohort ($n = 66$), with early-stage (IB–IIA) cervical cancer, developing a Rad-score able to predict DFS, where higher Rad-scores were significantly associated with worse DFS in the training and validation cohorts ($p < 0.001$ and $p = 0.011$, respectively). Finally, Takada et al⁴⁷ performed MR radiomics analysis to identify the most appropriate volume of interest (VOI) setting in prediction of prognosis in patients with CC treated with definitive radiotherapy. In a study cohort of 87 patients, the authors constructed a model by extracting features from the VOI drawn within the tumor, and then mechanically expanding the VOI to +4 mm and +20 mm. They demonstrated that VOI expansion improved AUC-ROCs compared with the predictive models of VOI tumor (0.59 and 0.67 in T_2 WI and ADC, respectively), and that the AUC-ROCs of the models with imaging features from expanded VOI +4 mm in T_2 WI and VOI +4 mm and VOI +8 mm in ADC were 0.82, 0.82, and 0.86, respectively.⁴⁷

Radiomics in endometrial cancer

Endometrial cancer (EC) represents the sixth most frequent tumor type among female individuals.⁷⁴ EC is usually classified into two major types (I and II), based upon microscopic appearance, clinical behavior, and epidemiology. Types I (endometrioid adenocarcinomas), account for about 80% of endometrial carcinomas, are well differentiated, have a favorable prognosis (overall survival >85% at five years) and are estrogen responsive. Types II tumors account for 10–20% of EC, include high grade endometrioid tumors and non-endometrioid tumours (serous, clear-cell, mucinous, squamous, transitional cell, mesonephric, carcinosarcoma, and undifferentiated). These tumors have a poor prognosis (overall survival 55% at 5 years) and are not clearly associated with estrogen stimulation.^{75–78} More recently, a molecular reclassification of endometrial tumors has been

proposed. In fact, genomic features of the disease strongly influence its clinical behavior and prognosis.⁷⁷ Endometrial cancer treatment includes surgery, radiation, standard chemotherapy and hormonal treatment. Single agent immunotherapy is now an option for patients whose disease harbors microsatellite instability (MSI) and immune-check point inhibitors in combination with antiangiogenic represent a promising treatment for microsatellite stable tumors.⁷⁸⁻⁸¹

Tumor prognostic factors

- Histology

Endometrial atypical hyperplasia (EAH) is caused by continuous estrogen stimulation in the endometrium without progesterone antagonism, resulting in changes in endometrial cell morphology and clonal hyperplasia of endometrial glands and stroma. EAH is known as a precancerous lesion for type I EC.⁴⁸

EAH with field cancerization (FC) and Stage 1A EC have been evaluated by radiomics research. Wang et al analyzed 170 patients, including 57 cases of EAH, 45 cases of FC, and 68 cases of Stage 1A EC.⁴⁸ They found moderate positive correlations between the PET standardized uptake values and postoperative pathological features with correlation coefficient of 0.663, 0.651, and 0.651, respectively ($p < 0.001$). To differentiate between the diagnosis of EAH and FC, maximum standard uptake value -SUVmax displayed the largest AUC of 0.857 (sensitivity, 82.2%; specificity, 84.2%), whereas to differentiate between the diagnoses of FC and Stage 1A EC, the SUVpeak displayed the largest AUC of 0.715 (sensitivity, 67.6%; specificity, 77.8%). Thus, the authors concluded that SUVmax and SUVpeak had the highest diagnostic values for EAH, FC, and Stage 1A EC, and that the addition of texture features may provide valuable information for differentiating EAH, FC, and Stage 1A EC.⁴⁸

- Deep myometrial invasion

Ueno et al⁴⁹ evaluated the associations between MR radiomics features and deep myometrial invasion (DMI). The authors extracted 11 features associated with DMI from pelvic MR scans of 137 patients who underwent surgery, demonstrating that mathematical models incorporating the significant MR based texture features for DMI in cancers larger than 1 cm, achieved equivalent accuracy to that of subspecialty radiologists. However, these results were not validated on independent cohorts and the small number of patients may have resulted in overfitting of the models. Ghosh et al⁵⁰ focused on the evaluation of DMI and tumor type, using diffusion tensor imaging sequences to assess the lesion's mean fractional anisotropy, belonging to higher order statistics features. They showed sensitivity and specificity of 94 and 88% respectively to predict DMI. In their small cohort ($n = 27$), the authors decided to get the features only from ADC maps. Stanzone et al⁵¹ investigated a radiomic model which could increase radiologists' performance in interpreting correctly DMI. The authors made a three-dimensional segmentation of the endometrial lesion and extracted a large number of radiomic features from a small cohort of patients ($n = 54$), concluding that the radiologists performance is higher with the radiomics support.⁵¹

Ytre-Hauge et al prospectively analyzed texture parameters from pre-operative MR of 180 patients, to assess if they were associated with the known prognostic factors.⁵² The authors manually drew two-dimensional regions of interest on the slice displaying the largest cross-sectional tumor area. They showed that high tumor entropy in ADC maps independently predicted DMI (OR 3.2, $p < 0.001$), whereas high mean of positive pixels in post contrast T_1 WI independently predicted high-risk histological subtype (OR 1.01, $p = 0.004$).

- Lymph node status

The presence of positive lymph nodes is a well-known negative prognostic factor in EC. Since extended lymphadenectomy may be associated to high rates of early and late post-operative complications, radiologists have tried to support the surgeons in pre-operative evaluation of lymph nodes involvement.^{11,77,78} However, in recent years the advent of the use of sentinel node at surgery, has made the pre-operative assessment of lymph nodes less stringent. Nevertheless, the interpretation of lymph nodes at imaging is still under debate, and some radiomics studies have evaluated this topic.⁷⁸ In 2018 De Bernardi et al⁵³ retrospectively analyzed 115 [¹⁸F]-FDG PET scans of patients affected by EC with different grading and staging. They showed in two different cohorts, used as training and validation sets, how the computation of imaging features on the primary tumor increased the nodal staging detection sensitivity of [¹⁸F]-FDG PET.

Crivellaro et al⁵⁴ analyzed 167 patients with EC who underwent surgical staging after [¹⁸F]-FDG PET and used histology as reference. Radiomics features were computed inside tumor contours using standard Image Biomarker Standardization Initiative (IBSI) for features extraction. They demonstrated a significant association between the presence of lymph node metastases and 64 radiomics features. Among these, volume density was the most predictive one ($p = 0.001$, AUC = 0.77, cut-off 0.35).

Among authors that evaluated the prediction of nodal metastases by MR based radiomics, Xu et al developed and compared four different predictive models, one based on clinical features only, one based on radiomic features only and two based on mixed radiomics and clinical features.⁵⁵ Additionally, performance on MR reports of two specialized radiologists was included in the final comparison. One of the models based on both clinical and radiomic features showed, no difference in diagnostic prediction of nodal involvement for patients with enlarged nodes as expected, but it showed relevant increased sensibility for normal and small-sized nodes ($3 < n < 8$ mm and $n < 3$ mm), especially when compared with radiologists alone performance.⁵⁵

Yan et al⁵⁶ studied a large cohort of 622 patients from five different centers, divided into one training set and two validation sets, with the purpose of improving the preoperative assessments of pelvic lymph node metastasis. They showed that in low risk patients, radiologists can detect positive nodes with increased sensibility, with an integrated discrimination index ranging from 0.21 to 0.24. Furthermore, the authors suggested that the radiomics co-occurrence matrix plots of pelvic lymph node metastases

and the immunohistochemical indexes were correlated with estrogen and progesterone receptors, P53, and Ki-67.⁵⁶

- *Assessment for high-risk EC*

According to the European Society for Medical Oncology (ESMO) guidelines, different clinical and pathological features correlate with the risk of disease recurrence, representing well-defined prognostic factors for patients with EC.⁸⁰ High-risk EC are those tumors with at least one of the following characteristics: deep myometrial invasion, high grade tumor, non-endometrioid histological subtype (serous and clear cell), linfovascular space invasion, extrauterine spread or nodal involvement. Yan et al⁵⁷ studied a cohort of 717 EC patients with the purpose of developing a radiomics nomogram to predict high-risk EC (referring to EC needing lymphadenectomy), preoperatively. Their nomogram achieved good net benefit by clinical decision curve analysis for high-risk EC and the author concluded that their radiomics nomogram exhibited good performance in the individual prediction of high-risk EC, therefore it might be used to plan the surgical management of EC patients.⁸²

Considering the advancements in molecular reclassification of EC, Veeraraghavan et al have recently evaluated whether radiomic features from contrast-enhanced CT can identify DNA mismatch repair deficient (MMR-D) and/or tumor mutational burden-high (TMB-H) tumors.⁸³ The authors included 150 patients, whose EC were evaluated for molecular subtypes and TMB. Patients were divided into a training dataset ($n = 105$) and a validation dataset ($n = 45$). Integrated radiomic-clinical classification distinguished MMR-D from copy number (CN)-low-like and CN-high-like ECs with an area under the receiver operating characteristic curve of 0.78 (95% CI 0.58–0.91). The model further differentiated TMB-H from TMB-low (TMB-L) tumors with an AUC of 0.87 (95% CI 0.73–0.95). The authors conclude that radiomics may provide an adjunctive tool for the assessment of tumor molecular profile, especially given its potential advantage in the setting of intratumor heterogeneity.

Ytre-Hauge et al in their prospective evaluation of 180 MR demonstrated that high kurtosis in post-contrast T1-WI was a good predictor of reduced recurrence as well as progression free survival (HR 1.5, $p < 0.001$), after adjusting for tumor volume and histological risk at biopsy.⁵²

DISCUSSION

In the last few years, radiomics is emerging as a tool able to help radiologists in more precise diagnoses and in predicting prognosis for different tumors. The studies included in this review demonstrate that a wide range of imaging techniques and methods have assessed the role of radiomics in identification of tumour prognostic factors, evaluation of response to therapy and prediction of recurrence and distant metastases in CC. Indeed, for the same imaging technique (mainly MR), different sequences have been evaluated; likewise, conclusions on significant results have been

based on different features categories included, frequently evaluated with different statistical methods, ranging from descriptive statistics to machine learning methods. Furthermore, not all the results described as significant have been validated in external cohorts or prospectively. This variability of methods and results makes it difficult to draw definitive conclusions about the current role of radiomics in prognostication of CC. Therefore, the main further steps before full clinical application of radiomics in predicting prognosis of CC, should consider the choice of robust, reliable and reproducible, radiomics features; to homogenize nomenclature and analysis methods; to include not only larger populations for building models, but also internal and external validation cohorts, or even prospective validations, to test the power of the models.

Likewise, many research articles have assessed the role of radiomics in evaluation of tumor prognostic factors in EC, demonstrating for example great promise for the use of models including clinical and radiomics features to predict positive lymph nodes, especially in small lymph nodes and in populations considered at low risk. Furthermore, the results pertaining the identification of high-risk groups are promising, but the mentioned models are not directly applicable to other cohorts and need further validation. However, although an increasing number of research articles demonstrate that radiomics may provide valuable information in prediction of prognosis for patients with cervical cancer and endometrial cancer, many issues for reproducibility and subsequent applicability in clinical practice, arise.

Indeed, there are still many limitations and disadvantages to be considered before implementing radiomics models into clinical practice. For example, segmentation of a lesion using manual methods require the delineation of the tumor margins on each single slice where the lesion is visible, in order to construct a three-dimensional structure. This process can be even more time-consuming if the radiomics features must be extracted from more than one acquisition (as from morphological and functional MR sequences). Furthermore, the repeatability and robustness of radiomics features would need dedicated studies, possibly including phantom experiments. As demonstrated by this review, different studies rely on extraction of features performed by using different software, some of which are commercially available, whereas others are not and are home tailored. Considering also that many studies used small populations to build their prognostic models, and that frequently they lacked validation cohorts to confirm the value of the models, it is clear that efforts to homogenize nomenclature, methods and analyses are needed to make consistent comparisons and conclusions across studies.

In conclusion, attempts should focus on current challenges of radiomics analyses, in order to shorten the way to a full clinical applicability of radiomics scores and models in prognostication of CC and EC.

REFERENCES

- Nougaret S, Tardieu M, Vargas HA, Reinhold C, Vande Perre S, Bonanno N, et al. Ovarian cancer: an update on imaging in the era of radiomics. *Diagn Interv Imaging* 2019; **100**: 647–55. doi: <https://doi.org/10.1016/j.diii.2018.11.007>
- Rizzo S, Botta F, Raimondi S, Origgi D, Fanciullo C, Morganti AG, et al. Radiomics: the facts and the challenges of image analysis. *Eur Radiol Exp* 2018; **2**: 36. doi: <https://doi.org/10.1186/s41747-018-0068-z>
- Gillies RJ, Kinahan PE, Hricak H. Radiomics: images are more than pictures, they are data. *Radiology* 2016; **278**: 563–77. doi: <https://doi.org/10.1148/radiol.2015151169>
- Berenguer R, Pastor-Juan MDR, Canales-Vázquez J, Castro-García M, Villas MV, Mansilla Legorburu F, et al. Radiomics of CT features may be Nonreproducible and redundant: influence of CT acquisition parameters. *Radiology* 2018; **288**: 407–15. doi: <https://doi.org/10.1148/radiol.2018172361>
- Kumar V, Gu Y, Basu S, Berglund A, Eschrich SA, Schabath MB, et al. Radiomics: the process and the challenges. *Magn Reson Imaging* 2012; **30**: 1234–48. doi: <https://doi.org/10.1016/j.mri.2012.06.010>
- Hojjatoleslami SA, Kittler J. Region growing: a new approach. *IEEE Trans Image Process* 1998; **7**: 1079–84. doi: <https://doi.org/10.1109/83.701170>
- Xu N, Bansal R, Ahuja N. Object segmentation using graph cuts based active contours. *IEEE* 2003; **42**: 46–53.
- Rogers W, Thulasi Seetha S, Refaee TAG, Lieverse RIY, Granzier RWY, Ibrahim A, et al. Radiomics: from qualitative to quantitative imaging. *Br J Radiol* 2020; **93**: 20190948. Epub 2020 Feb 26. doi: <https://doi.org/10.1259/bjr.20190948>
- Peeken JC, Wiestler B, Combs SE. Image-Guided Radiooncology: the potential of Radiomics in clinical application. *Recent Results Cancer Res* 2020; **216**: 773–94. doi: https://doi.org/10.1007/978-3-030-42618-7_24
- Botta F, Raimondi S, Rinaldi L, Bellerba F, Corso F, Bagnardi V, et al. Association of a CT-based clinical and radiomics score of non-small cell lung cancer (NSCLC) with lymph node status and overall survival. *Cancers* 2020; **12**: E143231 05 2020. doi: <https://doi.org/10.3390/cancers12061432>
- Rizzo S, Radice D, Femia M, De Marco P, Origgi D, Preda L, et al. Metastatic and non-metastatic lymph nodes: quantification and different distribution of iodine uptake assessed by dual-energy CT. *Eur Radiol* 2018; **28**: 760–9. doi: <https://doi.org/10.1007/s00330-017-5015-5>
- Hotker AM, Mazaheri Y, Wibmer A, et al. Differentiation of clear cell renal cell carcinoma from other renal cortical tumors by use of a quantitative multiparametric MRI approach. *American Journal of Roentgenology*. Vol 208. *American Roentgen Ray Society* 2017;: W85–91.
- Vargas HA, Veeraraghavan H, Micco M, Nougaret S, Lakhman Y, Meier AA, et al. A novel representation of inter-site tumour heterogeneity from pre-treatment computed tomography textures classifies ovarian cancers by clinical outcome. *Eur Radiol* 2017; **27**: 3991–4001. doi: <https://doi.org/10.1007/s00330-017-4779-y>
- Rizzo S, Botta F, Raimondi S, Origgi D, Buscarino V, Colarieti A, et al. Radiomics of high-grade serous ovarian cancer: association between quantitative CT features, residual tumour and disease progression within 12 months. *Eur Radiol* 2018; **28**: 4849–59. doi: <https://doi.org/10.1007/s00330-018-5389-z>
- Meier A, Veeraraghavan H, Nougaret S, Lakhman Y, Sosa R, Soslow RA, et al. Association between CT-texture-derived tumor heterogeneity, outcomes, and BRCA mutation status in patients with high-grade serous ovarian cancer. *Abdom Radiol* 2019; **44**: 2040–7. doi: <https://doi.org/10.1007/s00261-018-1840-5>
- Beer L, Sahin H, Bateman NW, Blazic I, Vargas HA, Veeraraghavan H, et al. Integration of proteomics with CT-based qualitative and radiomic features in high-grade serous ovarian cancer patients: an exploratory analysis. *Eur Radiol* 2020; **30**: 4306–16. doi: <https://doi.org/10.1007/s00330-020-06755-3>
- Mu W, Chen Z, Liang Y, Shen W, Yang F, Dai R, et al. Staging of cervical cancer based on tumor heterogeneity characterized by texture features on (18)F-FDG PET images. *Phys Med Biol* 2015; **60**: 5123–39. doi: <https://doi.org/10.1088/0031-9155/60/13/5123>
- Yang F, Thomas MA, Dehdashti F, Grigsby PW. Temporal analysis of intratumoral metabolic heterogeneity characterized by textural features in cervical cancer. *Eur J Nucl Med Mol Imaging* 2013; **40**: 716–27. doi: <https://doi.org/10.1007/s00259-012-2332-4>
- Lin Y-C, Lin C-H, Lu H-Y, Chiang H-J, Wang H-K, Huang Y-T, et al. Deep learning for fully automated tumor segmentation and extraction of magnetic resonance radiomics features in cervical cancer. *Eur Radiol* 2020; **30**: 1297–305. doi: <https://doi.org/10.1007/s00330-019-06467-3>
- Guan Y, Li W, Jiang Z, Zhang B, Chen Y, Huang X, et al. Value of whole-lesion apparent diffusion coefficient (ADC) first-order statistics and texture features in clinical staging of cervical cancers. *Clin Radiol* 2017; **72**: 951–8. doi: <https://doi.org/10.1016/j.crad.2017.06.115>
- Tsujikawa T, Rahman T, Yamamoto M, Yamada S, Tsuyoshi H, Kiyono Y, et al. ¹⁸F-FDG PET radiomics approaches: comparing and clustering features in cervical cancer. *Ann Nucl Med* 2017; **31**: 678–85. doi: <https://doi.org/10.1007/s12149-017-1199-7>
- Wu Q, Shi D, Dou S, Shi L, Liu M, Dong L, et al. Radiomics analysis of multiparametric MRI Evaluates the pathological features of cervical squamous cell carcinoma. *J Magn Reson Imaging* 2019; **49**: 1141–8. doi: <https://doi.org/10.1002/jmri.26301>
- Liu Y, Zhang Y, Cheng R, Liu S, Qu F, Yin X, et al. Radiomics analysis of apparent diffusion coefficient in cervical cancer: a preliminary study on histological grade evaluation. *J Magn Reson Imaging* 2019; **49**: 280–90. doi: <https://doi.org/10.1002/jmri.26192>
- Wormald BW, Doran SJ, Ind TE, D'Arcy J, Petts J, deSouza NM. Radiomic features of cervical cancer on T2-and diffusion-weighted MRI: prognostic value in low-volume tumors suitable for trachelectomy. *Gynecol Oncol* 2020; **156**: 107–14. doi: <https://doi.org/10.1016/j.ygyno.2019.10.010>
- Li Z, Li H, Wang S, Dong D, Yin F, Chen A, et al. MR-Based Radiomics nomogram of cervical cancer in prediction of the Lymph-Vascular space invasion preoperatively. *J Magn Reson Imaging* 2019; **49**: 1420–6. doi: <https://doi.org/10.1002/jmri.26531>
- Jiang X, Li J, Kan Y, Yu T, Chang S, Sha X, et al. Mri based Radiomics approach with deep learning for prediction of vessel invasion in early-stage cervical cancer. *IEEE/ACM Trans Comput Biol Bioinform* 2020; **PP03** Jan 2020. doi: <https://doi.org/10.1109/TCBB.2019.2963867>
- Li X-X, Lin T-T, Liu B, Wei W. Diagnosis of cervical cancer with parametrial invasion on Whole-Tumor dynamic contrast-enhanced magnetic resonance imaging combined with Whole-Lesion texture analysis based on T2- weighted images. *Front Bioeng Biotechnol* 2020; **8**: 590. doi: <https://doi.org/10.3389/fbioe.2020.00590>
- Wang T, Gao T, Guo H, Wang Y, Zhou X, Tian J, et al. Preoperative prediction of parametrial invasion in early-stage

- cervical cancer with MRI-based radiomics nomogram. *Eur Radiol* 2020; **30**: 3585–93. doi: <https://doi.org/10.1007/s00330-019-06655-1>
29. Shen W-C, Chen S-W, Liang J-A, Hsieh T-C, Yen K-Y, Kao C-H. [18F]Fluorodeoxyglucose Positron Emission Tomography for the Textural Features of Cervical Cancer Associated with Lymph Node Metastasis and Histological Type. *Eur J Nucl Med Mol Imaging* 2017; **44**: 1721–31. doi: <https://doi.org/10.1007/s00259-017-3697-1>
 30. Becker AS, Ghafoor S, Marcon M, Peruchio JA, Wurnig MC, Wagner MW, et al. MRI texture features may predict differentiation and nodal stage of cervical cancer: a pilot study. *Acta Radiol Open* 2017; **6**: 205846011772957. doi: <https://doi.org/10.1177/2058460117729574>
 31. Kan Y, Dong D, Zhang Y, Jiang W, Zhao N, Han L, et al. Radiomic signature as a predictive factor for lymph node metastasis in early-stage cervical cancer. *J Magn Reson Imaging* 2019; **49**: 304–10. doi: <https://doi.org/10.1002/jmri.26209>
 32. Wang T, Gao T, Yang J, Yan X, Wang Y, Zhou X, et al. Preoperative prediction of pelvic lymph nodes metastasis in early-stage cervical cancer using radiomics nomogram developed based on T2-weighted MRI and diffusion-weighted imaging. *Eur J Radiol* 2019; **114**: 128–35. doi: <https://doi.org/10.1016/j.ejrad.2019.01.003>
 33. Wu Q, Wang S, Chen X, Wang Y, Dong L, Liu Z, et al. Radiomics analysis of magnetic resonance imaging improves diagnostic performance of lymph node metastasis in patients with cervical cancer. *Radiother Oncol* 2019; **138**: 141–8. doi: <https://doi.org/10.1016/j.radonc.2019.04.035>
 34. Xiao M, Ma F, Li Y, Li Y, Li M, Zhang G, et al. Multiparametric MRI-based Radiomics nomogram for predicting lymph node metastasis in early-stage cervical cancer. *J Magn Reson Imaging* 2020; **52**: 885–96. doi: <https://doi.org/10.1002/jmri.27101>
 35. Jin X, Ai Y, Zhang J, Zhu H, Jin J, Teng Y, et al. Noninvasive prediction of lymph node status for patients with early-stage cervical cancer based on radiomics features from ultrasound images. *Eur Radiol* 2020; **30**: 4117–24. doi: <https://doi.org/10.1007/s00330-020-06692-1>
 36. Chen J, He B, Dong D, Liu P, Duan H, Li W, et al. Noninvasive CT radiomic model for preoperative prediction of lymph node metastasis in early cervical carcinoma. *Br J Radiol* 2020; **93**: 20190558. doi: <https://doi.org/10.1259/bjr.20190558>
 37. Ciolina M, Vinci V, Villani L, Gigli S, Saldari M, Panici PB, et al. Texture analysis versus conventional MRI prognostic factors in predicting tumor response to neoadjuvant chemotherapy in patients with locally advanced cancer of the uterine cervix. *Radiol Med* 2019; **124**: 955–64. doi: <https://doi.org/10.1007/s11547-019-01055-3>
 38. Sun C, Tian X, Liu Z, Li W, Li P, Chen J, et al. Radiomic analysis for pretreatment prediction of response to neoadjuvant chemotherapy in locally advanced cervical cancer: a multicentre study. *EBioMedicine* 2019; **46**: 160–9. doi: <https://doi.org/10.1016/j.ebiom.2019.07.049>
 39. Fang M, Kan Y, Dong D, Yu T, Zhao N, Jiang W, et al. Multi-Habitat based Radiomics for the prediction of treatment response to concurrent chemotherapy and radiation therapy in locally advanced cervical cancer. *Front Oncol* 2020; **10**: 563. doi: <https://doi.org/10.3389/fonc.2020.00563>
 40. Tian X, Sun C, Liu Z, Li W, Duan H, Wang L, et al. Prediction of response to preoperative neoadjuvant chemotherapy in locally advanced cervical cancer using multicenter CT-based radiomic analysis. *Front Oncol* 2020; **10**: 77. doi: <https://doi.org/10.3389/fonc.2020.00077>
 41. Reuzé S, Orhac F, Chargari C, Nioche C, Limkin E, Riet F, et al. Prediction of cervical cancer recurrence using textural features extracted from 18F-FDG PET images acquired with different scanners. *Oncotarget* 2017; **8**: 43169–79. doi: <https://doi.org/10.18632/oncotarget.17856>
 42. Meng J, Zhu L, Zhu L, Xie L, Wang H, Liu S, et al. Whole-lesion ADC histogram and texture analysis in predicting recurrence of cervical cancer treated with CCRT. *Oncotarget* 2017; **8**: 92442–53. doi: <https://doi.org/10.18632/oncotarget.21374>
 43. Meng J, Liu S, Zhu L, Zhu L, Wang H, Xie L, et al. Texture analysis as imaging biomarker for recurrence in advanced cervical cancer treated with CCRT. *Sci Rep* 2018; **8**: 11399. doi: <https://doi.org/10.1038/s41598-018-29838-0>
 44. Lucia F, Visvikis D, Desseroit M-C, Miranda O, Malhaire J-P, Robin P, et al. Prediction of outcome using pretreatment ¹⁸F-FDG PET/CT and MRI radiomics in locally advanced cervical cancer treated with chemoradiotherapy. *Eur J Nucl Med Mol Imaging* 2018; **45**: 768–86. doi: <https://doi.org/10.1007/s00259-017-3898-7>
 45. Lucia F, Visvikis D, Vallières M, Desseroit M-C, Miranda O, Robin P, et al. External validation of a combined PET and MRI radiomics model for prediction of recurrence in cervical cancer patients treated with chemoradiotherapy. *Eur J Nucl Med Mol Imaging* 2019; **46**: 864–77. doi: <https://doi.org/10.1007/s00259-018-4231-9>
 46. Fang J, Zhang B, Wang S, Jin Y, Wang F, Ding Y, et al. Association of MRI-derived radiomic biomarker with disease-free survival in patients with early-stage cervical cancer. *Theranostics* 2020; **10**: 2284–92. doi: <https://doi.org/10.7150/thno.37429>
 47. Takada A, Yokota H, Watanabe Nemoto M, Horikoshi T, Matsushima J, Uno T. A multi-scanner study of MRI radiomics in uterine cervical cancer: prediction of in-field tumor control after definitive radiotherapy based on a machine learning method including peritumoral regions. *Jpn J Radiol* 2020; **38**: 265–73. doi: <https://doi.org/10.1007/s11604-019-00917-0>
 48. Makker V, Taylor MH, Aghajanian C, Oaknin A, Mier J, Cohn AL, et al. Lenvatinib plus pembrolizumab in patients with advanced endometrial cancer. *J Clin Oncol* 2020; **38**: 2981–92. doi: <https://doi.org/10.1200/JCO.19.02627>
 49. Wang T, Sun H, Guo Y, Zou L. ¹⁸F-FDG PET/CT Quantitative Parameters and Texture Analysis Effectively Differentiate Endometrial Precancerous Lesion and Early-Stage Carcinoma. *Mol Imaging* 2019; **18**: 1536012119856965. doi: <https://doi.org/10.1177/1536012119856965>
 50. Ueno Y, Forghani B, Forghani R, Dohan A, Zeng XZ, Chamming's F, et al. Endometrial carcinoma: MR imaging-based texture model for preoperative risk stratification—A preliminary analysis. *Radiology* 2017; **284**: 748–57. doi: <https://doi.org/10.1148/radiol.2017161950>
 51. Ghosh A, Singh T, Singla V, Bagga R, Srinivasan R, Khandelwal N. DTI histogram parameters correlate with the extent of myoinvasion and tumor type in endometrial carcinoma: a preliminary analysis. *Acta Radiol* 2020; **61**: 675–84. doi: <https://doi.org/10.1177/0284185119875019>
 52. Stanzione A, Cuocolo R, Del Grosso R, Nardiello A, Romeo V, Travaglio A, et al. Deep myometrial infiltration of endometrial cancer on MRI: a Radiomics-Powered machine learning pilot study. *Acad Radiol* 2021; **28**(2): 30118–5S1076-. doi: <https://doi.org/10.1016/j.acra.2020.02.028>
 53. Ytre-Hauge S, Dybvik JA, Lundervold A, Salvesen Øyvind O, Krakstad C, Fasmer KE, et al. Preoperative tumor texture analysis on MRI predicts high-risk disease and reduced survival in endometrial cancer. *J Magn Reson Imaging* 2018; **48**: 1637–47. doi: <https://doi.org/10.1002/jmri.26184>
 54. De Bernardi E, Buda A, Guerra L, et al. Radiomics of the primary tumour as a tool to improve ¹⁸F-FDG-PET sensitivity in detecting nodal metastases in endometrial cancer. *EJNMMI Res* 2018; **8**: 1–9.

55. Crivellaro C, Landoni C, Elisei F, Buda A, Bonacina M, Grassi T, et al. Combining positron emission tomography/computed tomography, radiomics, and sentinel lymph node mapping for nodal staging of endometrial cancer patients. *Int J Gynecol Cancer* 2020; **30**: 378–82. doi: <https://doi.org/10.1136/ijgc-2019-000945>
56. Xu X, Li H, Wang S, et al. Multiplanar MRI-based predictive model for preoperative assessment of lymph node metastasis in endometrial cancer. *Front Oncol* 2019; **9**: 1–11.
57. Yan BC, Li Y, Ma FH, Zhang GF, Feng F, Sun MH, et al. Radiologists with MRI-based radiomics AIDS to predict the pelvic lymph node metastasis in endometrial cancer: a multicenter study. *Eur Radiol* 2021; **31**: 411–422. <https://doi.org/10.1007/s00330-020-07099-8>. doi: <https://doi.org/10.1007/s00330-020-07099-8>
58. Arbyn M, Weiderpass E, Bruni L, de Sanjosé S, Saraiya M, Ferlay J, et al. Estimates of incidence and mortality of cervical cancer in 2018: a worldwide analysis. *Lancet Glob Health* 2020; **8**: e191–203. doi: [https://doi.org/10.1016/S2214-109X\(19\)30482-6](https://doi.org/10.1016/S2214-109X(19)30482-6)
59. Bray F, Ferlay J, Soerjomataram I, Siegel RL, Torre LA, Jemal A, et al. GLOBOCAN estimates of incidence and mortality worldwide for 36 cancers in 185 countries. *CA Cancer J Clin* 2018; **2018**: 394–424.
60. Brisson M, Kim JJ, Canfell K, Drolet M, Gingras G, Burger EA, et al. Impact of HPV vaccination and cervical screening on cervical cancer elimination: a comparative modelling analysis in 78 low-income and lower-middle-income countries. *Lancet* 2020; **395**: 575–90. doi: [https://doi.org/10.1016/S0140-6736\(20\)30068-4](https://doi.org/10.1016/S0140-6736(20)30068-4)
61. Marth C, Landoni F, Mahner S, McCormack M, Gonzalez-Martin A, Colombo N, et al. Cervical cancer: ESMO clinical practice guidelines for diagnosis, treatment and follow-up. *Ann Oncol* 2017; **28**(suppl_4): iv72–83. doi: <https://doi.org/10.1093/annonc/mdx220>
62. Bhatla N, Berek JS, Cuello Fredes M, et al. Revised FIGO staging for carcinoma of the cervix uteri. *Int J Gynecol Obstet* 2019; **145**: 129–35.
63. Cohen PA, Jhingran A, Oaknin A, Denny L. Cervical cancer. *Lancet* 2019; **393**: 169–82. doi: [https://doi.org/10.1016/S0140-6736\(18\)32470-X](https://doi.org/10.1016/S0140-6736(18)32470-X)
64. Menderes G, Black J, Schwab CL, Santin AD. Immunotherapy and targeted therapy for cervical cancer: an update. *Expert Rev Anticancer Ther* 2016; **16**: 83–98. doi: <https://doi.org/10.1586/14737140.2016.1121108>
65. Chung HC, Ros W, Delord J-P, Perets R, Italiano A, Shapira-Frommer R, et al. Efficacy and safety of pembrolizumab in previously treated advanced cervical cancer: results from the phase II KEYNOTE-158 study. *J Clin Oncol* 2019; **37**: 1470–8. doi: <https://doi.org/10.1200/JCO.18.01265>
66. Petrella F, Diotti C, Rimessi A, Spaggiari L. Pulmonary metastasectomy: an overview. *J Thorac Dis* 2017; **9**(Suppl 12): S1291–8. doi: <https://doi.org/10.21037/jtd.2017.03.175>
67. Cancer.org American Cancer Society; Cervical Cancer Stages.. Available from: <https://www.cancer.org/cancer/cervical-cancer/detection-diagnosis-staging/survival.html> [Accessed on 25 September 2020].
68. Schick U, Lucia F, Dissaux G, Visvikis D, Badic B, Masson I, et al. MRI-derived radiomics: methodology and clinical applications in the field of pelvic oncology. *Br J Radiol* 2019; **92**: 20190105. doi: <https://doi.org/10.1259/bjr.20190105>
69. Manganaro L, Lakhman Y, Bharwani N, Gui B, Gigli S, Vinci V, et al. Staging, recurrence and follow-up of uterine cervical cancer using MRI: updated guidelines of the European Society of urogenital radiology after revised FIGO staging 2018. *Eur Radiol* 2021; **14 Apr** 2021. doi: <https://doi.org/10.1007/s00330-020-07632-9>
70. Balcacer P, Shergill A, Litkouhi B. MRI of cervical cancer with a surgical perspective: staging, prognostic implications and pitfalls. *Abdom Radiol* 2019; **44**: 2557–71. doi: <https://doi.org/10.1007/s00261-019-01984-7>
71. Matsuura Y, Kawagoe T, Toki N, Tanaka M, Kashimura M. Long-standing complications after treatment for cancer of the uterine cervix--clinical significance of medical examination at 5 years after treatment. *Int J Gynecol Cancer* 2006; **16**: 294–7. doi: <https://doi.org/10.1111/j.1525-1438.2006.00354.x>
72. Rose PG, Java J, Whitney CW, Stehman FB, Lanciano R, Thomas GM, et al. Nomograms predicting progression-free survival, overall survival, and pelvic recurrence in locally advanced cervical cancer developed from an analysis of identifiable prognostic factors in patients from NRG oncology/gynecologic Oncology Group randomized trials of chemoradiotherapy. *J Clin Oncol* 2015; **33**: 2136–42. doi: <https://doi.org/10.1200/JCO.2014.57.7122>
73. Mackay HJ, Wenzel L, Mileskin L. Nonsurgical management of cervical cancer: locally advanced, recurrent, and metastatic disease, survivorship, and beyond. *Am Soc Clin Oncol Educ Book* 2015;: e299–309. doi: https://doi.org/10.14694/EdBook_AM.2015.35.e299
74. Siegel RL, Miller KD, Jemal A. Cancer statistics. *CA Cancer J Clin* 2018; **2018**: 7–30.
75. Bokhman JV. Two pathogenetic types of endometrial carcinoma. *Gynecol Oncol* 1983; **15**: 10–17. doi: [https://doi.org/10.1016/0090-8258\(83\)90111-7](https://doi.org/10.1016/0090-8258(83)90111-7)
76. Setiawan VW, Yang HP, Pike MC, McCann SE, Yu H, Xiang Y-B, et al. Type I and II endometrial cancers: have they different risk factors? *J Clin Oncol* 2013; **31**: 2607–18. doi: <https://doi.org/10.1200/JCO.2012.48.2596>
77. Rizzo S, Femia M, Buscarino V, Franchi D, Garbi A, Zanagnolo V, et al. Endometrial cancer: an overview of novelties in treatment and related imaging keypoints for local staging. *Cancer Imaging* 2018; **18**: 45. doi: <https://doi.org/10.1186/s40644-018-0180-6>
78. , Kandath C, Schultz N, Cherniack AD, Akbani R, Liu Y, et al. Cancer Genome Atlas Research Network Integrated genomic characterization of endometrial carcinoma. *Nature* 2013; **497**: 67–73. doi: <https://doi.org/10.1038/nature12113>
79. Colombo N, Preti E, Landoni F, Carinelli S, Colombo A, Marini C, et al. Endometrial cancer: ESMO clinical practice guidelines for diagnosis, treatment and follow-up. *Ann Oncol* 2013; **24 Suppl 6**(Suppl 6): vi33–8. doi: <https://doi.org/10.1093/annonc/mdt353>
80. FDA. FDA approves first cancer treatment for any solid tumor with a specific genetic feature.. Available from: <https://www.fda.gov/news-events/press-announcements/fda-approves-first-cancer-treatment-any-solid-tumor-specific-genetic-feature> [Accessed October 10, 2020].
81. Colombo N, Creutzberg C, Amant F, et al. ESMO-ESGO-ESTRO consensus conference in endometrial cancer. *Ann Oncol* 2016; **27**: 16–41.
82. Yan BC, Li Y, Feng Hua MA, et al. Preoperative assessment for high-risk endometrial cancer by developing an MRI- and Clinical-Based Radiomics nomogram: a multicenter study. *J Magn Reson Imaging* 2020;: 1–11.
83. Veeraraghavan H, Friedman CF, DeLair DF, Ninčević J, Himoto Y, Bruni SG, et al. Machine learning-based prediction of microsatellite instability and high tumor mutation burden from contrast-enhanced computed tomography in endometrial cancers. *Sci Rep* 2020; **10**: 17769. doi: <https://doi.org/10.1038/s41598-020-72475-9>