

Neurocysticercosis in a 23-year-old Chinese man

Authors' Contribution:
Study Design A
Data Collection B
Statistical Analysis C
Data Interpretation D
Manuscript Preparation E
Literature Search F
Funds Collection G

EF **Rosa Fontana Del Vecchio**
AEF **Marilia Rita Pinzone**
ADE **Giuseppe Nunnari**
ADE **Bruno Cacopardo**

Division of Infectious Diseases, Department of Clinical and Molecular Biomedicine,
Garibaldi Nesima Hospital, University of Catania, Catania, Italy

Corresponding Author: Giuseppe Nunnari, e-mail: gennunari@hotmail.com
Conflict of interest: None declared

Patient: Male, 23
Final Diagnosis: Neurocysticercosis
Symptoms: Diplopia • fever • headache • insomnia • neck stiffness • vomiting
Medication: Albendazole
Clinical Procedure: —
Specialty: Neurology

Objective: Challenging differential diagnosis

Background: Neurocysticercosis is a brain infection caused by the larval stage of the tapeworm *Taenia (T.) solium*. It is the most important parasitic disease of the human central nervous system and represents the most common cause of acquired epilepsy in developing countries.

Case Report: Here, we report the case of a 23-year-old Chinese man who presented to the emergency department with a 7-day history of helmet headache radiating to the nuchal region and associated with vomiting, confusion, and fever. Cerebrospinal fluid (CSF) was clear, with increased pressure, lymphocytic pleocytosis, decreased glucose, and increased protein levels. Bacterial antigen detection test on CSF was negative, as were CSF bacterial and fungal cultures. Despite broad-spectrum antibiotic and antiviral therapy, the patient still complained of insomnia, diplopia, headache, neck stiffness, and pain in the sacral region. A second LP was performed and CSF had the same characteristics as the first LP. A brain and spinal cord MRI revealed widespread arachnoiditis and small septated cysts with CSF-like signal in the cisterna magna, within the fourth ventricle, and at the level of L3–L4. Cysticercus-specific immunoglobulin G antibodies were detected by ELISA in the CSF. The patient received albendazole (15 mg/kg/day) and dexamethasone (5 mg/day) for 4 weeks, with progressive resolution of neurological symptoms.

Conclusions: This case shows that, even if rare, neurocysticercosis may be responsible for meningeal symptoms and should be included in the differential diagnosis, especially in patients from endemic countries.

MeSH Keywords: *Taenia solium* • Meningitis • Neurocysticercosis – diagnosis • Neurocysticercosis – physiopathology

Full-text PDF: <http://www.amjcaserep.com/download/index/idArt/889807>



1460



—



1



13

Background

Neurocysticercosis (NCC) is a brain infection caused by the larval stage of the tapeworm *Taenia (T.) solium* [1–3]. It is the most important parasitic disease of the human central nervous system (CNS) and represents the most common cause of acquired epilepsy in developing countries. *T. solium* requires 2 hosts to complete its life cycle: humans, the final hosts; and pigs, the intermediate hosts. In the intermediate host, the larval stage of the tapeworm (cysticercus) is embedded in muscles and subcutaneous tissues and sometimes in liver, lungs, and brain. Humans usually become infected by ingesting undercooked pork containing *T. solium* cysticerci (taeniasis). An adult worm may develop in the small bowel of the definitive host and produce segments (proglottids) containing many eggs, which are shed on defecation and may be ingested by the intermediate hosts. Humans may accidentally act as intermediate hosts (cysticercosis), by ingesting food contaminated by *T. solium* eggs. Autoinfection may also occur [1–3]. Cysticerci may be found in the muscles and subcutaneous tissues, liver, lung, and brain. NCC is the leading cause of adult-onset epilepsy in areas of the world where this parasitic infection is endemic, particularly in Latin America, Asia (India, China, and Korea) and Africa (South Africa, Togo, Madagascar, Zimbabwe and Burundi, which are all non-Muslim countries) [4,5]. In developed countries, imported cases have increased in parallel to the increased number of migrants and international travel [6,7]. Patients with NCC often experience a long asymptomatic period and can present with a variety of neurological manifestations, including focal neurological deficits and seizures. Cysticerci commonly localize in the brain parenchyma (parenchymal NCC), but they can also develop within ventricles and subarachnoid spaces (extraparenchymal NCC) [2]. In the CNS, viable cysticerci are in a vesicular stage, characterized by a transparent membrane, clear vesicular fluid, and normal invaginated scolex. Cysticerci may remain viable for several years or may undergo progressive degeneration as a consequence of the host immunological response. In the colloidal stage, the vesicular fluid becomes turbid and the scolex shows signs of hyaline degeneration. In the granular stage, parasites are no longer viable, the cyst wall is thickened, and the scolex is transformed into mineralized granules. In the final stage, parasites appear as calcified nodules. Parenchymal NCC is predominantly associated with non-refractory epileptic syndromes and has a reasonably good prognosis. In contrast, extraparenchymal NCC is more difficult to diagnose and more complex to treat, usually showing a progressive course and significantly higher mortality. Hydrocephalus often develops due to mechanical obstruction of the ventricles or the basal cisterns, either by the cysts themselves or by the inflammatory response (ependymitis and/or arachnoiditis). In the racemose variety, which is characterized by abnormal growth of cystic membranes with

degeneration of the parasite head (scolex), the prognosis is poor and patients typically die due to intracranial hypertension, even after ventricular shunting, because the parasite membranes or inflammatory cells and proteins frequently block the shunt [2].

Here, we present a case of extraparenchymal NCC in a 23-year-old Chinese man. We also summarize the diagnostic and therapeutic approach to NCC.

Case Report

In November 2009 a 23-year-old Chinese man presented to the emergency department with a 7-day history of helmet headache radiating to the nuchal region and associated with vomiting, confusion, and fever. Physical examination showed modest neck stiffness, lateral decubitus position, and hyperexcitable tendon reflexes. Babinski and Lasègue signs were negative bilaterally. The patient underwent brain and cervical spine CT scan, which was unremarkable. LP revealed CSF with increased pressure, lymphocytic pleocytosis, decreased glucose, and increased protein levels. Bacterial antigen detection test on CSF was negative, as were CSF bacterial and fungal cultures. CSF acid-fast bacilli smear and culture were negative. Broad-spectrum parenteral therapy with acyclovir, cefotaxime, chloramphenicol, mannitol, and dexamethasone was started. In the following days the patient still complained of insomnia, diplopia, headache, neck stiffness, and pain in the sacral region. Eye and ENT exams were unremarkable. Therefore, a second LP was performed. CSF had the same characteristics as the first LP. The following blood test results were all negative: antibodies against *Herpes simplex* virus types 1 and 2, HIV, hepatitis A, B, and C viruses, Widal's and Wright's serodiagnosis, VDRL and TPHA, QuantiFERON-TB, Western blot test for Lyme disease, and parasitological stool exam. A brain and spinal cord MRI was performed (Figure 1), revealing widespread arachnoiditis and small septated cysts with CSF-like signal in the cisterna magna, within the fourth ventricle, and at the level of L3–L4. These findings were likely due to arachnoiditic adhesions. Differential diagnosis included toxoplasmosis, fungal abscess, primary or metastatic brain tumour, vasculitis, tuberculoma, and neurocysticercosis. However, the patient had no evidence of immunodeficiency and no predisposing factors for immunocompromise. CSF cultures for *Mycobacterium tuberculosis* and QuantiFERON-TB were negative. Cysticercus-specific immunoglobulin G antibodies were detected by ELISA in the CSF. The patient received albendazole (15 mg/kg/day) and dexamethasone (5 mg/day) for 4 weeks, with progressive resolution of neurological symptoms. A second MRI performed 6 months later confirmed the regression of the lesions.

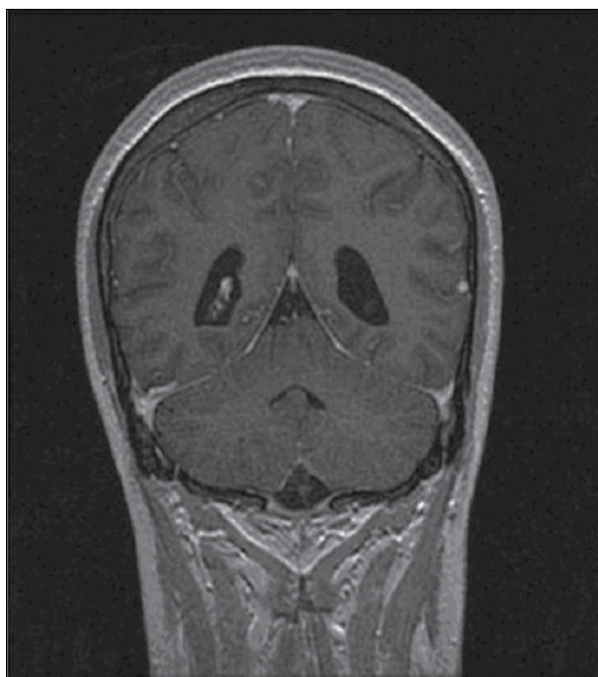


Figure 1. Coronal T1-weighted MRI showing the presence of a septum within the fourth ventricle and diffuse arachnoid enhancement in the medulla oblongata, pons and cerebellar hemispheres.

Discussion

Diagnosis of NCC is often challenging because symptoms are nonspecific and neuroimaging findings are not always pathognomonic. The clinical picture of NCC is variable and includes seizures, focal neurological signs, and intracranial hypertension, depending on the extent and localization of the cysts. The differential diagnosis of multiple cystic cerebral lesions includes abscesses, tubercles, metastasis, and glioblastoma. Parasitic CNS infections and subacute cerebrovascular events should also be considered. Del Brutto et al. [2] proposed diagnostic criteria for NCC based on neuroimaging studies, serologic tests, epidemiology, and clinical history. Major criteria include neuroimaging studies consistent with NCC (e.g. cystic lesions or large calcifications), positive serum immunoblot for the detection of anticysticercal antibodies, and resolution of intracranial cystic lesions after therapy with albendazole or praziquantel. Minor criteria include clinical manifestations suggestive for NCC, positive CSF ELISA for detection of anticysticercal antibodies or cysticercal antigens, and presence of cysticercosis outside the CNS. Epidemiologic criteria include residence in or extensive travel to an endemic area or exposure to a tapeworm carrier. Definitive diagnosis is based on the presence of 2 major plus 1 minor and 1 epidemiologic criterion; diagnosis is considered probable in patients who have 1 major plus 2 minor criteria, in those who have 1 major plus 1 minor and 1 epidemiologic criteria, and in those who have 3 minor plus 1 epidemiologic criteria [2].

The treatment of NCC is complex and should take into account several factors, including the size, location, and viability of cysts, as well as the degree of the host immune response to parasites. Praziquantel and albendazole are cysticidal drugs, with a 60–85% killing activity against *T. solium* parenchymal cysticerci. A dosage of 15 mg/kg of albendazole for 4 weeks was initially adopted, but later reduced to 15 days and then to 1 week [2]. Albendazole also destroys subarachnoid and ventricular cysts and has been associated with higher parasitocidal effects than praziquantel [8,9]. However, the majority of published studies are uncontrolled case series and there is no consensus on the most appropriate dose and timing of these antiparasitic drugs. Studies evaluating the clinical benefits of antiparasitic therapy have yielded conflicting results: some authors reported a significant modification in the natural history of NCC, but others did not find significant differences [10–12]. However, a recent meta-analysis indicated that the administration of cysticidal drugs was associated with a reduction in the rate of generalized seizures in patients with vesicular cysticerci, better resolution of both colloidal and vesicular cysticerci, and a lower risk of seizure recurrence in patients with colloidal cysticerci [13]. Antiparasitic treatment may lead to exacerbation of neurological symptoms, due to the death of parasites. Steroids are usually used to control cerebral inflammation. Antiepileptic drugs may be required to control seizures secondary to NCC [2]. The management of extraparenchymal NCC is even more challenging and surgical treatment may be required in some cases. In patients with intracranial hypertension, a shunt should be placed before starting therapy with antiparasitic drugs and steroids. Neuroendoscopy may be an effective therapeutic option to remove approachable ventricular cysts [2]. Our patient was successfully treated with a 30-day course of albendazole and dexamethasone. However, the standard of care is unclear and a highly individualized approach is recommended to define the most appropriate therapeutic option.

Conclusions

Even if rare, NCC may be responsible for meningeal symptoms and should be included in the differential diagnosis, especially in patients from endemic countries. Diagnosis is often difficult because clinical manifestations are unspecific and highly variable, immunological tests are not standardized, and neuroimaging findings are not always pathognomonic. Treatment of neurocysticercosis is controversial and depends on several factors, including the type of disease, the location and number of cysts, symptoms, and complications. Prospective studies are warranted to establish the most appropriate management of NCC.

Conflicts of interest

None declared.

References:

1. Sinha S, Sharma BS: Neurocysticercosis: A review of current status and management. *J Clin Neurosci*, 2009; 16(7): 867–76
2. García HH, Evans CA, Nash TE et al: Current Consensus Guidelines for Treatment of Neurocysticercosis. *Clin Microbiol Rev* 2002;15(4): 747–56.
3. Del Brutto OH. Neurocysticercosis: A Review. *Scientific World Journal*, 2012; 2012: 159821
4. Fleury A, García JM, Aguerrebere PV et al: Neurocysticercosis, a persisting health problem in Mexico. *PLoS Negl Trop Dis*, 2010; 4(8): e805
5. Winkler AS: Neurocysticercosis in sub-Saharan Africa: a review of prevalence, clinical characteristics, diagnosis, and management. *Pathog Glob Health*, 2012; 106(5): 261–74
6. Del Brutto OH: Neurocysticercosis in Western Europe: a re-emerging disease? *Acta Neurol Belg*, 2012; 112(4): 335–43
7. Sorvillo F, Wilkins P, Shafir S, Eberhard M: Public health implications of cysticercosis acquired in the United States. *Emerg Infect Dis*, 2011; 17(1): 1–6
8. Sotelo J, Del Brutto OH, Penagos P et al: Comparison of therapeutic regimen of anticycercal drugs for parenchymal brain cysticercosis. *J Neurol*, 1990; 237(2): 69–72
9. Takayanagui OM, Jardim E: Therapy for neurocysticercosis: comparison between albendazole and praziquantel. *Arch Neurol*, 1992; 49(3): 290–94
10. Mitchell WG, Crawford TO: Intraparenchymal cerebral cysticercosis in children: diagnosis and treatment. *Pediatrics*, 1988; 82(1): 76–82
11. Carpio A, Kelvin EA, Bagiella E et al: Effects of albendazole treatment on neurocysticercosis: a randomised controlled trial. *J Neurol Neurosurg Psychiatry*, 2008; 79(9): 1050–55
12. Baranwal AK, Singhi PD, Singhi SC, Khandelwal N: Seizure recurrence in children with focal seizures and single small enhancing computed tomographic lesions: prognostic factors on long-term follow-up. *J Child Neurol*, 2001; 16(6): 443–45
13. Del Brutto OH, Roos KL, Coffey CS, Garcia HH: Meta-analysis: cysticidal drugs for neurocysticercosis: albendazole and praziquantel. *Ann Intern Med*, 2006; 145(1): 43–51