

**International PhD Program in Neuropharmacology**

**XXVII Cycle**

# **Diabetic retinopathy and Type 3 Diabetes – Role of Homocysteine**

---

**Doctorate Thesis**

**Giulia Malaguarnera**

Coordinator: Prof. Salvatore Salomone

Tutor: Prof. Teresio Avitabile

Co-Tutor: Prof. Maria Francesca Cordeiro



Department of Biomedical and Biotechnological Sciences. University of Catania -  
Medical School



## Index

<b>Abstract .....</b>	<b>4</b>
1. General Introduction .....	5
1.1 Preface.....	5
1.2 DIABETIC RETINOPATHY .....	7
1.3 ALZHEIMER DISEASE .....	13
1.4 HOMOCYSTEINE.....	17
1.5 Present Study.....	21
Chapter 1 .....	22
Chapter 2 .....	40
Chapter 3 .....	61
2. General Discussion and Conclusions.....	92
3. References .....	97

## **Abstract**

Homocysteine is a sulphur amino acid converted to methionine to a remethylation pathway and to cysteine via transulphuration pathway. Its level in the blood increase with age and are associated with several pathologies: cancer, autoimmune disease, cardiovascular and neurodegenerative disorders.

The present thesis has focused on the study of the relationship between elevated levels of homocysteine and the deficiency of his metabolites, focusing on folate, in the severity of diabetic retinopathy (non- proliferative and proliferative).

Then it had been investigated whether retinal Hcy is associated with retinal neurodegeneration. Histopathological, molecular, and biochemical abnormalities have commonalities in Diabetes and Alzheimer's Disease (AD), which has lead to AD recently termed as "Type 3 Diabetes". Therefore, the present study has focused to evaluate the role of homocysteine in animal models of Type 2 Diabetes (Goto-Kakizaki (GK) rats) and Alzheimer Disease (TASTPM transgenic mice).

# 1. General Introduction

## 1.1 Preface

Diabetic retinopathy (DR) is a chronic, progressive, potentially sight-threatening disease of the retinal microvasculature, associated with diabetes mellitus. DR is widely considered to be a neurovascular disease: retinal neurodegeneration is present before any microcirculatory abnormalities can be detected in ophthalmoscopic examination. The major cells in the neuronal component of the retina consist of retinal ganglion cells and glial cells, both of which have been found to be compromised. Several biochemical pathways have been proposed to link hyperglycemia and microvascular complications. These include polyol accumulation, formation of advanced glycation end products (AGEs) oxidative stress and activation of protein Kinase C.

The underlying causes of diabetic retinopathy have not yet been elucidated, although tight control of hyperglycemia and of other risk factors can retard its development and progression.

As well as diabetic retinopathy, neurodegeneration in the retina had been found in the eyes of Alzheimer's disease patients, even in the early stage of the pathology. Researchers in the past decades, have found common pathways in the elderly patients with Diabetes and Alzheimer's disease (AD), suggesting the hypothesis that AD is the "type 3 diabetes".

Several studies indicated that hyperhomocysteinemia is associated not only with an increased risk for thrombosis and stroke, but also both with diabetes and Alzheimer's disease.

A growing number of evidences indicate increased levels of excitotoxic metabolites, including glutamate, branched chain amino acids and homocysteine. Moreover, early in the disease also folic acid and vitamin B6 and B12, potential metabolites capable of damaging neurons, are decreased.

Understanding the relationship between plasma homocysteine, folate status, vitamin B6, B12 and diabetic retinopathy depends in our realization of the multifaceted issues in progression of development of neurodegeneration in the retina.

## **1.2 DIABETIC RETINOPATHY**

### **1.2.1 Epidemiology**

Diabetic retinopathy is a worldwide public health problem. DR, a frequent complication of both type 1 and type 2 diabetes, is the fifth most common cause of blindness in the United States (Klein et al., 1997), where the annual direct medical costs for management of this neurovascular pathology are estimated at 492 million and indirect costs attributable to loss of patient quality of life and reduced work productivity are likely to be higher (Rein et al., 2006). Retinopathy is the most common microvascular complication of diabetes resulting in blindness for over 10.000 people with diabetes per year. There is evidence that retinopathy begins to develop at least 7 years before the clinical diagnosis of type 2 diabetes (Harris, Cowie, & Howie, 1993). Epidemiological studies have described the natural history of diabetic retinopathy. Some retinopathy occurs in virtually all type 1 and 60% of type 2 diabetic patients affected  $\geq 20$ , although severe proliferative retinopathy is more frequent in type 1 diabetes. Disease incidence is the number of new cases of a particular disease occurring over a defined time period.

The incidence of type 2 diabetes in particular has risen dramatically driven by longevity combined with sedentary lifestyles and increasing levels of obesity (Boyle, Thompson, Gregg, Barker, & Williamson, 2010). In 2004 Wild S suggested that the most important demographic change to diabetes prevalence

across the world appears to be increase in the proportion of people >65 years of age (Wild, Roglic, Green, Sicree, & King, 2004).

Many studies have demonstrated the prevalence of diabetic retinopathy in 7% positive patients (Bek et al., 2009; Spijkerman et al., 2003). Beulens (Beulens et al., 2009) reported that baseline retinopathy levels ( ETDRS  $\geq$  20) of 1602 patients with type 2 diabetes in the ADVANCE study was 40.1 % indicating a high prevalence of the early features of microvascular damage.

Even if many people with diabetes may not develop vision-threatening stages of DR in the short term (Zavrelova et al., 2011). It is likely that increases in the number and longevity of people with diabetes will impact the public health burden of DR over time. Few population-based studies have reported the incidence of diabetic retinopathy. In the WESDR in the USA , the overall 10 years incidence of retinopathy was 74% and in people with retinopathy at baseline, 64% developed more severe retinopathy and 17% progressed to develop proliferative retinopathy. About 20% ( 14-25% ) of those with type 2 diabetes developed macular oedema during a 10-year follow-up. Additionally, both the prevalence and incidence of proliferative retinopathy were lowered in people with a recent diagnosis of diabetes

In 2009, Wong conducted a systematic review of rates of progression in diabetic retinopathy during different time periods. The authors concluded that since 1985, lower rates of progression to PDR and severe visual loss were being reported by



the studies included in the review. These findings may reflect an increased awareness of retinopathy risk factors; earlier identification and initiation of care for patients with retinopathy, and improve medical management of glucose, blood pressure and serum lipids.

### **1.2.2 Clinical features**

Diabetic retinopathy (DR) is a microvascular disease. Recognizing features of non-proliferative retinopathy enables to predict an individual's risk of future new vessel formation and to recommend a safe review interval. The first clinical signs of diabetic retinopathy are a consequence of isolated capillary occlusion, with adjacent non-occluded capillaries forming saccular or fusiform swellings called microaneurysms. The capillary circulation is only visible on fluorescein angiography. Proliferative diabetic retinopathy is the angiogenic response of the retina to extensive capillary closure. New vessels grow at the interface of perfused and non perfused retina and are described as new vessels on the disc or new vessels elsewhere. In proliferative retinopathy, new vessels grow on a platform of glial cells. If the new vessels component predominates vitreous haemorrhage is the predominant feature.

DR evolves asymptotically until visual loss develops, over an average of 15 years. In the 1996, Mizutani and colleagues demonstrated that diabetes lead to accelerated death in situ of both retinal pericytes and endothelial cells and it precedes histological evidence of retinopathy (Mizutani, Kern, & Lorenzi,

1996). Damage in the retinal neurons (photoreceptors, bipolar, horizontal, amacrine and ganglions), glia (Muller cells and astrocytes), microglia and pigment epithelial cells (Abu El-Asrar, Dralands, Missotten, & Geboes, 2007; Barber et al., 1998; Decanini et al., 2008; Kern & Barber, 2008; Krady et al., 2005) show that neurodegeneration is an important component of diabetic retinopathy.

The mechanisms of diabetes-induced damage to retinal cells is correlated with excessive circulating levels of glucose, lipids, hormones, amino acids and inflammatory molecules (Ahsan, 2014). Diabetes-induced dysregulated levels of excitotoxic metabolites, altered neurotrophic support/signaling and oxidative stress are among the potential causes of neurodegeneration (Ola, Nawaz, Khan, & Alhomida, 2013).

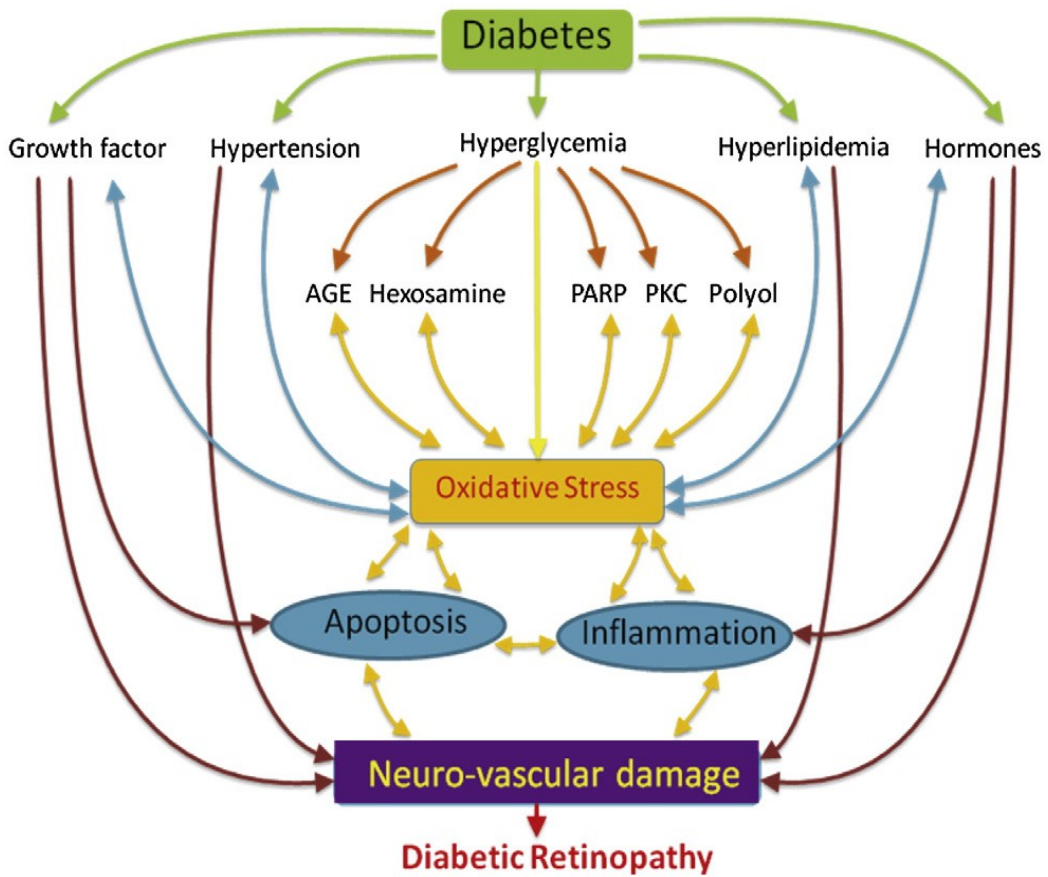
Presence of retinopathy, even in its mildest form is associated with a doubling or tripling of risk of stroke, coronary heart disease and heart failure, independent of cardiovascular risk factors. These findings suggest that the presence of retinopathy is a sign of widespread end-organ microcirculatory damage in people with diabetes, and that there is the need for improvement in careful cardiovascular monitoring and follow-up for patients with diabetic retinopathy. Recognition of the potential roles for the processes implicated in the pathophysiological mechanisms has led to development of new therapeutic agents, several of which have been or are being testing in clinical trials.

### **1.2.3 Risk factors**

Emerging evidence supports a genetic component for diabetic retinopathy. In the past 5 years, in studies of populations of other ethnic origins, investigators reported a heritable tendency for severe diabetic retinopathy that was not fully accounted for by lifestyle or environmental factors.

In the WESDR (Wisconsin Epidemiologic Study of Diabetic Retinopathy) results, diabetes duration after menarche, a marker of puberty onset, was associated with a 30% excess risk of retinopathy compared with diabetes duration before menarche. Similarly, pregnancy is associated with worsening diabetic retinopathy.

Several conditions contribute to the problem of loss of vision in diabetes, including diabetic and hypertensive retinopathy and increased risks of retinal vascular occlusion. The risk factors for diabetic retinopathy are non-modifiable and modifiable. The non-modifiable are: genetic factors, gender and duration of diabetes. The modifiable are: glycaemia, blood pressure and lipid levels. DR is associated with many other systemic and lifestyle factors, including nephropathy, obesity, carotid arterial disease, pregnancy, renal impairment, smoking, alcohol consumption and haematological markers of anaemia, hypothyroidism, inflammation, and endothelial dysfunction.



Ola M.S et al 2012

**Figure 1. General features for diabetes-induced neurovascular damage in DR.** Diabetes induces a number of mediators including growth factors, hormones, and inflammatory biomarkers that activate a wide range of biochemical pathways responsible for the progression

## **1.3 ALZHEIMER DISEASE**

### **1.3.1 Epidemiology**

An estimated 24 million people worldwide have dementia, the majority of whom are thought to have Alzheimer's disease (AD). The Delphi study estimated that there were 24,3 million people with dementia in the world in 2001, and predicted that this would rise to 42,3 million in 2020 and 81,1 million by 2040 (Ferri et al., 2005). Currently, the prevalence is estimated to amount to 24 million and predicted to quadruple by the year 2050. In the US alone, Alzheimer disease (AD) is associated with estimated healthcare costs of \$172 billion per year. Most people with AD are diagnosed at age 65 years or older. People younger than 65 years can also develop the disease, although this is much rarer. While age is the greatest risk factor, AD is not a normal part of aging, and advanced age alone is not sufficient to cause the disease.

### **1.3.2 Pathogenesis**

AD is characterized by cognitive decline associated with the presence of  $\beta$ -amyloid ( $A\beta$ ) in plaques, intracellular aggregates of tau protein, forming neurofibrillary tangles (NFT) and progressive neuronal loss (Salomone, Caraci, Leggio, Fedotova, & Drago, 2012). Additional changes include reactive microgliosis and widespread loss of neurons, white matter and synapses. The exact mechanisms leading to these changes remain to be determined (Reitz & Mayeux, 2014).

The notion that AD is a neurodegenerative disorder may have begun with a paper by Roth in 1955, who observed that AD results from a neurodegenerative process and can be distinguished from vascular dementia by the different mental changes (ROTH, 1955). The amyloid cascade hypothesis suggests that deposition of amyloid  $\beta$  ( $A\beta$ ) triggers neuronal dysfunction and death in the brain. In the original hypothesis, the total amyloid load was thought to have a toxic effect, but recent studies focused on more specific alterations in  $A\beta$  processing, such as the cleavage of amyloid precursor protein (APP) into  $A\beta$  peptides ( $A\beta_{1-40}$  and  $A\beta_{1-42}$ ) and the importance of  $A\beta$  oligomers (small aggregates of two to 12 peptides) (Ballard et al., 2011).

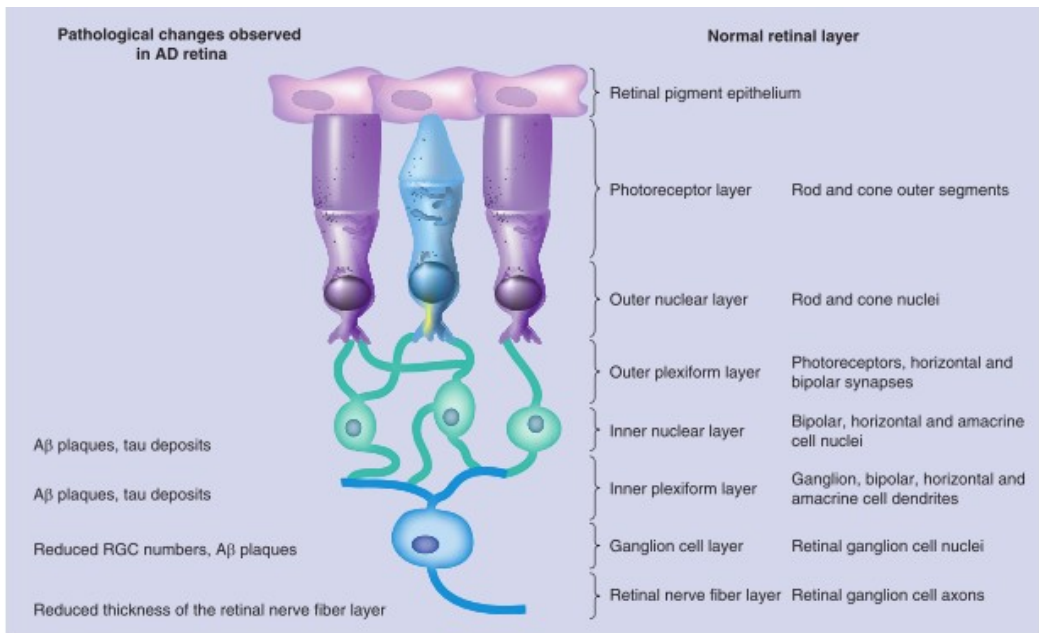
There is now substantial and growing evidence from studies of epidemiology, pharmacology, neuroimaging, clinical medicine, microscopic anatomy, and cellular-molecular biology to suggest that sporadic AD is a vascular disorder caused by impaired cerebral perfusion (de la Torre, 2004).

### **1.3.3 AD and eye**

At present, Alzheimer's disease can only be definitively diagnosed post mortem, although methods for improving diagnosis are also moving forward. Many studies are indicating that ocular manifestations of Central Nervous System (CNS) disorders often precede symptoms in the brain (London, Benhar, & Schwartz, 2013). Similarities between the eye and the brain in terms of anatomy, embryonic development (retina and optic nerve are extension of diencephalon),

and interaction with the immune system may explain why characteristics of brain neurodegenerative disease are manifest within the eye.

Therefore, eye investigations and ocular imaging techniques may be useful to assist in the early diagnosis. Non invasive techniques such as optical coherence tomography (OCT), analysis of fundi, confocal scanning laser, laser Doppler and visual field (VF) examination permit to detect retinal changes in AD patients. In particular, studies demonstrated that in AD there is a significant reduction in peripapillary RNFL thickness (in mild cognitive impairment, MCI), loss of RGCs (retinal ganglion cells), pattern electroretinogram changes, 39-43% greater cup-disc ratio than control group with the same age, significantly narrower venous blood column diameter and reduced blood flow rate and other consistently changes in the retinal vasculature (Dehabadi, Davis, Wong, & Cordeiro, 2014). Moreover, using a pass/fail screening criteria for VF had been reported significant difference between AD, MCI patients and healthy control (Risacher et al., 2013). Finally, also animal models have shown accumulation of A $\beta$ , APP, phosphorylated tau, hallmarks of apoptosis, inflammation, nuclear and mitochondrial degenerative changes in the retina layers.



Dehabadi et al. 2014

**Figure 2. Schematic representation of human retinal structure and changes seen in the human Alzheimer's disease retina**



## 1.4 HOMOCYSTEINE

### 1.4.1 Metabolism

Homocysteine (Hcy) is a sulphur amino acid with a free thiol group (-SH) that in the blood it is easily oxidized in disulphide (-S-S) group, forming homocystine. Hcy is converted from methionine through S-adenosyl methionine in a reversible reaction of the methylation pathway and it can be catabolised to cysteine by cystathionine- $\beta$ -synthase in the trans-sulphuration pathway (irreversible reaction). In the metabolism of Hcy, water-soluble vitamins, vitamin B<sub>6</sub>, vitamin B<sub>12</sub> and folate play vital role as co-enzymes for the enzymes cystathionine- $\beta$ -synthase, methyl transferase and methylene tetrahydrofolate reductase, respectively (Ramakrishnan, Sulochana, Lakshmi, Selvi, & Angayarkanni, 2006). A minor pathway to convert the homocysteine in methionine is by methylation of betaine, oxidation product of choline (Figure 2).

Methionine is activated via the action of methionine adenosyltransferase to generate S-adenosylmethionine (SAM), the ubiquitous methyl donor in a vast array of intracellular transmethylation reactions, such as the synthesis of many compounds, including creatine, phosphatidylcholine, and neurotransmitters. SAM-derived methylation also exerts a regulatory role in the control of gene expression. Posttranslational modification of histones via methylation can function to either condense or relax chromatin, whereas the methylation is present in DNA gene silencing. Although SAM-dependent transmethylation

exists in most tissues, the full homocysteine metabolism is mostly in the liver and thus it has a major influence on methyl group supply for other tissues as well as circulating homocysteine concentrations (Schalinske & Smazal, 2012).

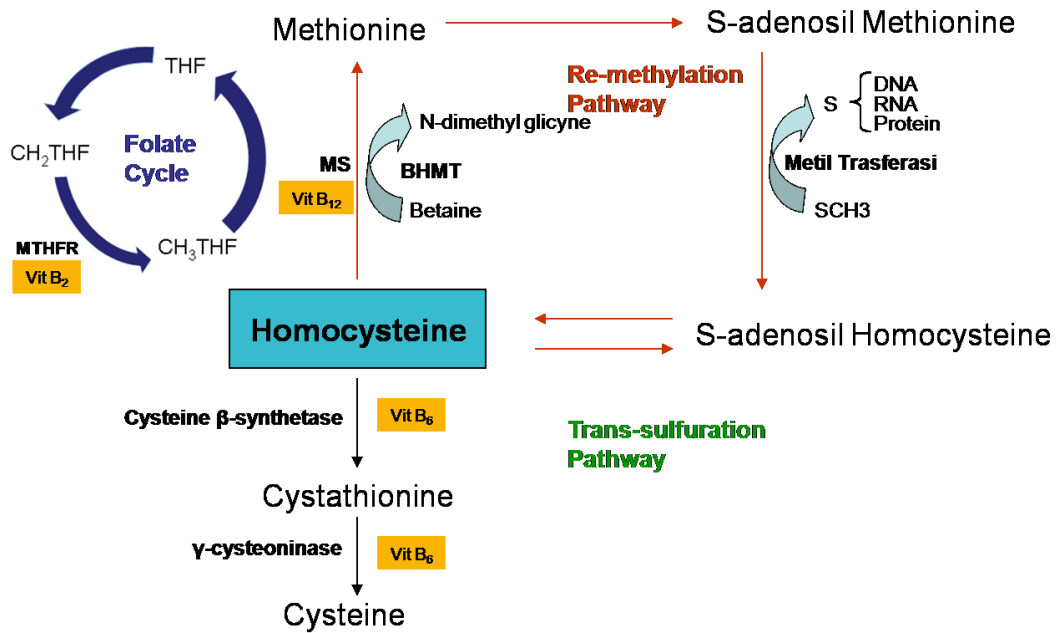


Figure 3. Homocysteine metabolism.

### 1.4.2 Dysfunction in disease

Numerous nutritional (including folate, vitamin B<sub>12</sub> and B<sub>6</sub> deficiency), hormonal, and genetic factors that are characterized by elevations in circulating homocysteine concentrations are also associated with specific pathological conditions, including cardiovascular disease, cancer development, autoimmune diseases, metabolic disorders and neurodegenerative disease.

A population-based study, with a 5-year follow-up, indicated that hyperhomocysteinemia is a risk factor for overall mortality in type 2 diabetic patients, independent of major cardiovascular risk factors (Hoogeveen et al., 2000). The role of homocysteine in eye disease is complex. Observational studies have shown that several eye conditions in the general population, such as some forms of glaucoma and age-related macular degeneration, are associated with raised plasma homocysteine concentrations (Wright, Martin, & Dodson, 2008). High level of homocysteine had been found in plasma, aqueous and vitreous of diabetic patients (Lim et al., 2012).

*In vitro* and *in vivo* studies have shown that homocysteine is a potent excitatory neurotransmitter that binds to the NMDA (N-methyl-D-aspartate) receptor and leads to cytoplasmic calcium influx, cellular apoptosis and endothelial dysfunction (McCully, 2009). High level of homocysteine, due to the diet poor in folate and vitamin B<sub>6</sub> and B<sub>12</sub> or to genetic deficiency in Cystathionine- $\beta$ -synthase (Cbs +/-), had been associated with damage to the blood brain barrier,

reduction of the expression of Glucose Transporter-1 and cerebrovascular eNOS (endothelial nitric oxide synthase) activity, enhanced mitochondrial ROS (reactive oxygen species), damaged vessels, lipid peroxidation and impaired learning and memory performance (Obeid & Herrmann, 2006). Moreover, higher level of Amyloid beta oligomers, A $\beta$ -40 and A $\beta$ -42, had been found in the brain of Cbs +/-; APP and PS1 mice (Pacheco-Quinto et al., 2006) and primary cortical neurons treated with Hcy (10-100  $\mu$ M) (Inna I Kruman et al., 2000).

Since the first paper reporting the elevation of Hcy in AD patients in 1990, increasing numbers of studies have been conducted to explore the relationship between HHcy and the risk of AD. Evidences from human and animal studies have converged to suggest that moderate elevation of Hcy in aged population is a potential risk factor for AD (Zhuo, Wang, & Praticò, 2011).

## 1.5 Present Study

The present thesis has focused on:

- Study the relationship between elevated levels of homocysteine in the severity of diabetic retinopathy. Elucidate the role of the deficiency in folic acid and red blood cells folate in patients with proliferative and non proliferative diabetic retinopathy
- Investigate whether retinal Hcy is associated with retinal neurodegeneration in animal models of AD (TASTPM transgenic mice) and T2DM (Goto-Kakizaki (GK) rats).

# Chapter 1

## **Homocysteine serum levels in diabetic patients with non proliferative, proliferative and without retinopathy**

Giulia Malaguarnera<sup>1</sup>, Caterina Gagliano<sup>2</sup>, Maria Giordano<sup>3</sup>, Salvatore Salomone<sup>1-4</sup>, Marco Vacante<sup>3</sup>, Claudio Bucolo<sup>1-4</sup>, Filippo Caraci<sup>1-4-5</sup>, Michele Reibaldi<sup>2</sup>, Filippo Drago<sup>1-4</sup>, Teresio Avitabile<sup>2</sup>, Massimo Motta<sup>3</sup>

<sup>1</sup> International PhD programme in Neuropharmacology, University of Catania

<sup>2</sup> Department of Ophthalmology, University of Catania

<sup>3</sup> Research Center “The Great Senescence” University of Catania, Italy

<sup>4</sup> Department of Clinical and Molecular Biomedicine, Section of Pharmacology and Biochemistry, University of Catania, Viale Andrea Doria 6, 95125 Catania, Italy.

<sup>5</sup>IRCCS, Oasi Maria S.S.-Institute for Research on Mental Retardation and Brain Aging, Troina (EN),

Address Correspondence

to Giulia Malaguarnera,

International PhD programme in Neuropharmacology, University of Catania

Phone number +39 95 7262008

Fax number +39 95 7262011

[E-mail: giulia.malaguarnera@live.it](mailto:giulia.malaguarnera@live.it)

## **Abstract**

**BACKGROUND:** Homocysteine has been associated with extracellular matrix changes. The diabetic retinopathy is a neurovascular complication of diabetes mellitus and it is the leading cause of vision loss among working adults worldwide. This study investigated the role of homocysteine in the progression of the diabetic retinopathy.

**METHODS:** We measured the plasma levels of homocysteine in 63 diabetic type 2 patients with non proliferative retinopathy (NPDR), 62 with proliferative diabetic retinopathy (PDR), 50 healthy subjects used as control group and 75 randomly selected patients.

**RESULTS:** Randomly selected patients showed significant differences in homocysteine levels compared to PDR ( $p<0.001$ ), NPDR ( $p<0.001$ ) and controls ( $p<0.05$ ); PDR showed differences compared to randomly selected patients ( $p<0.001$ ), NPDR ( $p<0.001$ ), healthy controls ( $p<0.001$ ) and diabetics without retinopathy ( $p<0.001$ ); NPDR showed differences compared to randomly selected patients ( $p<0.001$ ), PDR ( $p<0.001$ ), healthy controls ( $p<0.001$ ) and diabetics without retinopathy ( $p<0.001$ ); controls showed differences compared to randomly selected patients ( $p<0.05$ ), PDR ( $p<0.001$ ), NPDR ( $p<0.001$ ), and diabetics without retinopathy ( $p<0.001$ );



diabetics without retinopathy showed differences compared to PDR ( $p < 0.001$ ) and controls ( $p < 0.001$ ).

**CONCLUSION:** In our study higher plasma levels of homocysteine have been found in diabetic with proliferative diabetic retinopathy compared to both those NPDR and diabetics without retinopathy.

**Keywords:** Homocysteine (Hcy), proliferative diabetic retinopathy (PDR), non proliferative diabetic retinopathy, diabetes mellitus

## **1. Introduction**

Type 2 diabetes is increasing in modern societies [1]. TDM2 is a metabolic disease characterized by elevation of blood glucose concentrations, lipid abnormalities and vascular complications. Diabetes is a major cause of both microvascular (rethinopathy, nephropathy and neuropathy) and macrovascular diseases (cardiovascular diseases and non-traumatic lower extremity amputations), affecting, therefore, nearly every organ in the body.

Chronic exposure to elevate glucose and fatty acid concentrations can cause damage in different types of cells by a variety of mechanisms (glucolipototoxicity) [2]. Diabetes related and traditional risk factors including hyperglycemia, hyperinsulinemia, obesity, hypertension, hypertriglyceridemia, hypercholesterolemia and smoking are noted to increase the risk of cardiovascular disease in patients with diabetes [3]. The diabetic retinopathy

(DR) is a neurovascular complication of diabetes mellitus and it is the leading cause of vision loss among working adults worldwide. DR is a multifactorial progressive disease of the retina where the pathogenesis of the disease is extremely complex involving many different cells, molecules, and factors [4]. Hyperglycemia, hyperlipidemia, dysregulated hormones levels and growth factors induce a cascade of biochemical and physiological changes leading to the neurovascular damage in the retina through oxidative stress, inflammation and apoptosis [5].

Homocysteine is a sulfur containing aminoacid derived from methionine metabolism. Elevation in plasma homocysteine are common in the general population, particularly in the elderly. [6, 7]

Various studies indicate that mild elevations of homocysteine in plasma are associated with an increased risk for occlusive vascular disease, thrombosis and stroke.

Emerging data strongly imply that homocysteine may interact with a variety of systems, resulting in different outcomes. Interaction with endothelial cells may result in the impairment of the plasminogenic nature on account of increased thrombogenic properties. On the other hand, interaction with components in the vascular smooth muscle cells may result in enhanced proliferation of these cells and will result in an increased atherogenic tendency [8, 9].

Beside these factors, plasma total homocysteine have seen reported to associate with cardiovascular disease and increased risk of stroke, atherosclerosis, peripheral vascular disease and ischemic heart disease [10, 11].

There are fewer reports on the relationship between plasma homocysteine and diabetic retinopathy. The aim of our study was to evaluate plasma tHcy levels in diabetic patients with and without retinopathy in order to investigate the role of tHcy in the progression of the diabetic retinopathy.

## **2. Methods and Materials**

### **2.1 Patients**

This study was carried out on patients with type 2 DM regularly attending the outpatient clinic at Cannizzaro Hospital in Catania. We enrolled 175 diabetic consecutive patients (81 females, 84 males; mean age  $65.2 \pm 11.8$  years, mean duration of diabetes  $7.6 \pm 5.4$  years). The exclusion criteria were: 1) Patients who were already on lipid lowering drugs or glitazones; 2) Females taking oral contraceptive pills or hormone replacement therapy; 3) Familial hypercholesterolemia; 4) Hypothyroidism; 5) Patients with chronic liver disease; 6) Patients with kidney disease. Assessment of DR was performed by ophthalmoscopy and or biomicroscopy through dilated pupils by a retinal specialist, and fluorescein angiography was obtained when indicated. Examination of the retina was done through dilated pupils to determine the level of non-proliferative DR or proliferative DR or diabetes without retinopathy.

The DR is characterized by retinal microvascular signs that indicate the progression of the disease: from non-proliferative diabetic retinopathy (NPDR) to proliferative diabetic retinopathy (PDR), leading to macular oedema (DMO), and the commonest cause of blindness in diabetic patients. Group 1: the control groups were 80 randomly selected healthy subjects under 65 years of age (42 males and 38 females) aged 24-64 years (mean  $44.6 \pm 10.5$  years) composed of blood donors and randomly selected volunteers working at the University of Catania; Group 2: 75 randomly – selected patients (34 males and 40 females) ages 30-85 years (mean age  $60 \pm 9.2$  years) 50% of whom were institutionalized in Catania. According to the random selection criteria, no biochemical or hematological analysis were performed in groups 1 and 2.

## **2.2 Methods**

Venous blood samples were drawn from patients and all examinations were performed at 8.00 h after an overnight fast. The samples were allowed to clot and serum was separated from the erythrocytes by centrifugation at  $4^{\circ} \text{C}$  and at  $1500 \times g$  for 15 min. Total cholesterol, triglycerides and fasting plasma glucose were enzymatically measured (Roche/Hitachi 912 analyzer; Roche Diagnostics, Switzerland). Serum creatinine levels (upper reference limit  $120 \mu\text{mol/l}$ ) were assayed with routine laboratory method. The intra and interassay CVs were 0.9 and 2.7% respectively. The fasting plasma glucose concentrations were assayed using the glucose-oxidase method with intra- and interassay CVs

of 0.8% and 2.1%, respectively. Clinical chemistry tests were performed in the medical center laboratory using standard methods. Fasting blood samples were taken at enrolment from participants. The blood withdrawals were centrifuged at 2500 g for 15 min and plasma was separated and stored at -80 °C (until analysis). A part of each sample was used in order to measure tHcy concentration, according to the method of Asaki and Sako<sup>14</sup>. Fasting plasma levels of homocysteine were considered normal between 5 and 15 µmol/l (Graeme and Eikelbaum). The intra and interassay CVs were 1.4 and 3.2% respectively. High density lipoprotein cholesterol (HDL-c) was measured enzymatically in the supernatant after precipitation of apolipoprotein B-containing lipoproteins by phosphotunstate/MgCl<sub>2</sub>. Low-density lipoprotein (LDL) level was calculated by using the Friedwald's formula<sup>15</sup>. Measurement of HbA1c was made by high-performance liquid chromatography (Menarini Diagnostics, Italy). Anthropometric measurements including weight, height and waist and hip measurements were obtained using standardized techniques. Height was measured with a tape to the nearest centimeter. Subjects were requested to stand upright without shoes with their back against the wall, heels together and eyes directed forward. Weight was measured with a traditional spring balance that was kept on a firm horizontal surface. Subjects were asked to wear light clothing and weight was recorded to the nearest 0.5 Kg. Body mass index (BMI) was calculated by using the formula: weight [Kg/height (m<sup>2</sup>)]. Waist circumference was measured by using a non-stretchable

measuring tape. The subjects were asked to stand erect in a relaxed position with both feet together on a flat surface; one layer of clothing was accepted. Waist girth was measured as the smallest horizontal girth between the costal margins and the iliac crest at minimal respiration. Hip was taken as the greatest circumference (the widest protrusion of the hip) on both the sides; measurements were made to the nearest centimeter. Waist-to-hip ratio was calculated by dividing the waist circumference (cm) by the hip circumference (cm). Examination of the retina was done through dilated pupils to determine the level of non-proliferative DR, proliferative DR by qualified ophthalmologists (T.A; C.G.).

### **3. Statistical analysis**

The results are presented as mean  $\pm$  standard deviation. The following two-tailed tests at the  $p \leq 0.05$  level of significance were used to evaluate the study: the Mann-Whitney U-test was used in the case of two independent samples and the Spearman's rank correlation coefficient test was used to test for univariate relationships between variables. In order to evaluate the independent effects of covariates on Hcy concentration, a stepwise multiple linear regression analysis was performed.

## 4. Results

In our study 62 out of 175 enrolled patients had DR (Table 1). As regards diabetic management, 38 were on dietary treatment, 88 on metformin treatment, and 49 on insulin treatment.

### *Laboratory parameters*

Subjects with DR had higher glycated hemoglobin levels ( $P < 0.001$ ) and fasting plasma glucose ( $P < 0.001$ ) compared to both subjects with NPDR and without DR.

Significant differences were observed when comparing subjects with PDR vs subjects with NPDR in total cholesterol ( $p < 0.05$ ), LDL ( $p < 0.001$ ), and triglycerides ( $p < 0.05$ ). The comparison between PDR and subjects without DR showed differences in LDL ( $p < 0.05$ ), and triglycerides ( $p < 0.05$ ) (Table 2a). As regards creatinine levels, randomly selected patients showed significant differences compared to PDR and controls ( $p < 0.001$ ); PDR showed differences compared to randomly selected patients ( $p < 0.001$ ), healthy controls ( $p < 0.001$ ) and diabetics without retinopathy ( $p < 0.05$ ); NPDR showed differences compared to randomly selected patients ( $p < 0.05$ ) and healthy controls ( $p < 0.001$ ); controls showed differences compared to all other groups ( $p < 0.001$ ); diabetics without retinopathy showed differences compared to PDR ( $p < 0.05$ ) and controls ( $p < 0.001$ ). For homocysteine levels, randomly

selected patients showed significant differences compared to PDR ( $p<0.001$ ), NPDR ( $p<0.001$ ) and controls ( $p<0.05$ ); PDR showed differences compared to randomly selected patients ( $p<0.001$ ), NPDR ( $p<0.001$ ), healthy controls ( $p<0.001$ ) and diabetics without retinopathy ( $p<0.001$ ); NPDR showed differences compared to randomly selected patients ( $p<0.001$ ), PDR ( $p<0.001$ ), healthy controls ( $p<0.001$ ) and diabetics without retinopathy ( $p<0.001$ ); controls showed differences compared to randomly selected patients ( $p<0.05$ ), PDR ( $p<0.001$ ), NPDR ( $p<0.001$ ), and diabetics without retinopathy ( $p<0.001$ ); diabetics without retinopathy showed differences compared to PDR ( $p<0.001$ ) and controls ( $p<0.001$ ).

#### *Sensitivity, specificity, predictive value, odds ratio*

The values of sensitivity for both PDR and NPDR groups were 64% vs 63%, specificity 70% vs 70%, Predictive value of positive test 69% vs 54%, Predictive value of negative test 65% vs 50%, Efficiency of the test 67% vs 51%, prevalence 52% vs 51%. The odds ratio values were respectively 4.24 vs 1.16 (Table 3).

## **5. Discussion**

Numerous factors may have an effect on progression of diabetic retinopathy. In our study higher plasma levels of homocysteine have been



found in diabetic with proliferative diabetic retinopathy compared to both those non proliferative DR and diabetics without retinopathy. A previous study found moderate hyperhomocysteinemia to be a stronger cardiovascular risk factor in patients with type 2 diabetes than in non-diabetic subjects, suggesting that synergistic effects of diabetes and excessive circulating homocysteine, accelerate the development of atherosclerosis [12]. Homocysteine is toxic to the vascular endothelium and therefore induces thrombosis and thus may play a role in aggravating the hypoxic state such as that seen in diabetic retinopathy by further closure of the capillary bed. An increase in plasma and in vitreous concentration of Hcy in proliferative diabetic retinopathy has been described [13, 14, 15]. Recent study indicates that DNA methylation is an important player in both DNA repair and gene stability. There is growing evidence that histone modification and DNA methylation play an important role in the development of DR. It has been suggested that the inactivation of DNA repair pathways, which leads to an increased mutation rate and chromosomal instability, can initiate and accelerate the proliferative process [16]. In patients with diabetes mellitus the odds ratio for hyperhomocysteinemia were 4.24 and 1.16 in PDR and NPDR respectively. Increasing evidence suggested that the proliferation rate of cells would cause an elevation of circulating tHcy or an increase in the concentration of cells would deplete folate and inactivate the methionine synthase catalyzed remethylation reaction. This potential link between the microvascular changes that occur in diabetic retinopathy and

hyperhomocysteinemia may be useful as a predictor for retinopathy. Diabetic retinopathy is one of the micro-vascular complications of diabetes which may not have symptoms in the early stages. Control of these complications depends on proper management and monitoring of retinal status and blood glucose levels after the early detection of retinopathy, but may progress to a sight-threatening stage if left untreated.

Homocysteine and diabetes may exert an interactive negative impact on vascular events. Homocysteine and diabetes increase oxidative stress and reduce nitric oxide formation and may cause endothelial dysfunction [17, 18, 19]. Homocysteine enhances smooth muscle proliferation and affects the extracellular matrix. Thus elevated homocysteine level may act as a pathogenetic link or an instrument through which various risk factors may exert their deleterious effect on the promotion of diabetic retinopathy.

Thus, understanding and characterizing the Hcy role in the pathogenesis of diabetic retinopathy could help in identifying novel target to combat this blinding disease which is the major cause of blindness in adults.

### **Acknowledgment**

G.M has been supported by the International Ph. D. program in Neuropharmacology, University of Catania. None of the authors had any relevant personal or financial conflict of interests.

## References

1. P. Hossain, B. Kavar, M. El Nahas, “ Obesity and diabetes in the developing world--a growing challenge.” *N Engl J Med*. Vol. 356, no. 3, pp. 213-5, 2007.
2. L. Rampello, I. Vecchio, G. Battaglia, G. Malaguarnera, L.Rampello. “Diabetic neuropathy. Elements of epidemiology and pathophysiology”, *Acta medica Mediterranea*, Vol. 3, pp. 219, 2012
3. S.M. Grundy, I.J. Benjamin, G.L. Burke, et al., “Diabetes and cardiovascular disease: a statement for healthcare professionals from the American Heart Association.” *Circulation*. Vol. 100, no. 10, pp.1134-46, 1999.
4. D.R. Matthews, I.M. Stratton, S.J. Aldington, R.R. Holman, E.M. Kohner, “ UK Prospective Diabetes Study Group. Risks of progression of retinopathy and vision loss related to tight blood pressure control in type 2 diabetes mellitus: UKPDS 69”, *Arch Ophthalmol*, vol. 122, no. 11, pp. 1631-40, 2004
5. G. Malaguarnera, C. Gagliano, C. Bucolo, et al., “Lipoprotein(a) serum levels in diabetic patients with retinopathy”, *Biomed Res Int*, vol. 2013, pp. 943505, 2013.

6. M. Malaguarnera, R. Ferri , R. Bella, G. Alagona, A. Carnemolla, G. Pennisi, "Homocysteine vitamin B12 and folate in vascular dementia and in Alzheimer disease", *Clin Chem Lab Med*, vol. 42, no. 9, pp. 1032-5, 2004.
7. M. Malaguarnera, G. Pistone, M. Motta, E. Vinci, G. Oreste, G. Avellone, S. Musumeci S, "Elevated plasma total homocysteine in centenarians", *Clin Chem Lab Med*. Vol. 42, no. 3, pp. 307-10, 2004.
8. M. Dalton, J.S. Williams, "How best to approach point-of-care testing.", *CAP Today*, vol. 11, no. 12, pp. 46-8, 50, 1997.
9. H. Wang, M. Yoshizumi, K. Lai, J.C. Tsai, M.A. Perrella, E. Haber, M.E. Lee, "Inhibition of growth and p21ras methylation in vascular endothelial cells by homocysteine but not cysteine", *J Biol Chem*, Vol. 272, no. 40, pp. 25380-5, 1997.
10. J. Selhub J, P.F. Jacques, A.G. Bostom et al. "Association between plasma homocysteine concentrations and extracranial carotid-artery stenosis", *N Engl J Med*, Vol. 332, no. 5, pp. 286-91, 1995.
11. B.M. Coull, M.R. Malinow, N. Beamer, Sexton G, Nordt F, de Garmo P. "Elevated plasma homocyst(e)ine concentration as a possible independent risk factor for stroke", *Stroke*, Vol. 21, no. 4, pp. 572-6, 1990
12. E.K. Hoogeveen, P.J. Kostense, P.E. Eysink, et al. "Hyperhomocysteinemia is associated with the presence of retinopathy in

- type 2 diabetes mellitus: the Hoorn study”, *Arch Intern Med.* Vol. 160, no.19, pp. 2984-90, 2000
13. Aydemir O, Türkçüoğlu P, Güler M, et al. “Plasma and vitreous homocysteine concentrations in patients with proliferative diabetic retinopathy”, *Retina*, vol. 28, no. 5, pp. 741-3, 2008.
  14. Goldstein M, Leibovitch I, Yeffimov I, et al. “Hyperhomocysteinemia in patients with diabetes mellitus with and without diabetic retinopathy”, *Eye*, vol. 18, no. 5, pp. 460-5, 2004.
  15. Cho HC, “The Relationship among Homocysteine, Bilirubin, and Diabetic Retinopathy”, *Diabetes Metab. Journal*, vol. 35, no. 6, pp. 595-601, 2011
  16. G.N. Welch, J. Loscalzo, “Homocysteine and atherothrombosis”, *N Engl J Med*, vol. 38, no. 15, pp.1042-50, 1998
  17. Marrazzo G<sup>1</sup>, Bosco P, La Delia F, et al. “Neuroprotective effect of silibinin in diabetic mice”, *Neurosci Lett*, vol. 504, no.3, pp. 252-6, 2011
  18. Marrazzo G, Barbagallo I, Galvano F, et al. “Role of dietary and endogenous antioxidants in diabetes”, *Crit Rev Food Sci Nutr.*, vol. 54, no. 12, pp. 1599-616, 2011

Table 1. Demographic characteristics of the study population

Patients with type II diabetes Mellitus (n=175)	
Female/Male	81/84
Age (years)	65.2±11.8
Smokers/No smokers)	78/87
BMI (Kg/m <sup>2</sup> )	26.1±3.2
Waist circumference (cm)	94.1±8.71
Hip circumference (cm)	96.7±8.25
Waist-to-hip ratio	0.97±0.08
Systolic blood pressure (mmHg)	138.6±13.4
Diastolic blood pressure (mmHg)	81.8±8.7

Table 2a. Laboratory parameters of subjects included in the study

Parameter	PDR 62	NPDR 63	Without DR 50
Cholesterol total (mmol/l)	6.11±1.02	5.71±1.04**	5.88±1.07*
HDL (mmol/l)	1.39±0.34	1.31±0.33*	1.38±0.37*
LDL (mmol/l)	4.35±0.37	4.09±0.31***	4.19±0.30**
Triglycerides (mmol/l)	1.86±0.62	1.56±0.64**	1.58±0.51**
Fasting plasma glucose (mg/dl)	172±26	135±28***	147±24***
HbA1c (%)	8.8±0.6	7.2±0.7***	6.4±0.8***

Comparison between PDR and other groups : P=NS\*; P<0.05\*\*; P<0.001\*\*\*

Table 2b. Laboratory parameters of subjects included in the study

	Randomly selected patients n=75	PDR n=62	NPDR n=63	Controls (healthy subjects) n=80	Diabetic without retinopathy n=50
Creatinine (mg/dl)	84±18.4 <sup>CE§§</sup> §†	96±16.2 <sup>***D§§</sup> §††	91.8±15.7 <sup>**A§</sup> §§†	64±12.4 <sup>***CF</sup> †††	87±13.7 <sup>*BD§</sup> §§
Hcy (μmol/l)	10.2±4.7 <sup>CF§</sup> §†	18.2 ± 5.6 <sup>***F§§§†††</sup>	14.4 ± 6.7 <sup>***C§§§†</sup>	7.8 ± 6.4 <sup>**CF†††</sup>	12.1±6.8 <sup>*CD§</sup> §§

Comparison between randomly selected patients and other groups : P=NS\*; P<0.05\*\*; P<0.001\*\*\*

Comparison between PDR and other groups: P=NS<sup>A</sup>; P<0.05<sup>B</sup>; P<0.001<sup>C</sup>

Comparison between NPDR and other groups: P=NS<sup>D</sup>; P<0.05<sup>E</sup>; P<0.001<sup>F</sup>

Comparison between controls and other groups: P=NS<sup>§</sup>; P<0.05<sup>§§</sup>; P<0.001<sup>§§§</sup>

Comparison between diabetic without retinopathy and other groups: P=NS<sup>†</sup>; P<0.05<sup>††</sup>; P<0.001<sup>†††</sup>

## Chapter 2

### **Folate status in type 2 diabetic patients with and without retinopathy**

Giulia Malaguarnera<sup>1</sup>, Caterina Gagliano<sup>2</sup>, Salvatore Salomone<sup>1-4</sup>, Maria Giordano<sup>3</sup>, Claudio Bucolo<sup>1-4</sup>, Antonino Pappalardo<sup>3</sup>, Filippo Caraci<sup>5</sup>, Filippo Drago<sup>1-4</sup>, Teresio Avitabile<sup>2</sup>, Massimo Motta<sup>3</sup>.

<sup>1</sup> International PhD programme in Neuropharmacology, University of Catania

<sup>2</sup> Department of Ophthalmology, University of Catania

<sup>3</sup> Department of Medical and Pediatric Sciences, University of Catania, Italy

<sup>4</sup> Department of Clinical and Molecular Biomedicine, Section of Pharmacology and Biochemistry, University of Catania

<sup>5</sup> Department of Educational Sciences, University of Catania, Catania, Italy; IRCCS Associazione Oasi Maria S.S., Institute for Research on Mental Retardation and Brain Aging, 94018 Troina, (EN) Italy.



## **Address Correspondence**

to Giulia Malaguarnera,

International PhD programme in Neuropharmacology, University of Catania, Viale  
Andrea Doria 6, 95125 Catania, Italy.

Phone number +39 95 7262008

Fax number +39 95 7262011

E-mail: [giulia.malaguarnera@live.it](mailto:giulia.malaguarnera@live.it)

## **Abstract**

**Background:** Folate deficiency is associated with cardiovascular disease, megaloblastic anemia and with hyperhomocysteinemia. This study has been undertaken to investigate the role of folate status during the progression of the diabetic retinopathy.

**Methods:** We measured the plasma levels of homocysteine, folic acid and red cell folate in 70 diabetic type 2 patients with non proliferative retinopathy (NPDR), 65 with proliferative diabetic retinopathy (PDR) in 96 without diabetic retinopathy, 80 healthy subjects used a control group and 80 randomly selected patients.

**Results:** We found higher plasma levels of homocysteine in NPDR group compared to the control group ( $p < 0.001$ ) and in the PDR group compared to control group ( $p < 0.001$ ) and NPDR ( $p < 0.01$ ). The severity of DR was associated with lower folic acid and red cell folate levels, and a significant difference was observed between PDR and NPDR groups ( $p < 0.05$ ).

**Conclusion:** The folate status could play a role in the development and progression of diabetic retinopathy.

**Keywords:** Homocysteine (Hcy), proliferative diabetic retinopathy (PDR), non proliferative diabetic retinopathy, diabetes mellitus

## **Introduction**

Type 2 diabetes mellitus is a metabolic disorder characterized by hyperglycaemia resulting from insulin resistance and relative insulin deficiency. Coexisting disorders, including obesity, hypertension and dyslipidemia, contribute to the severity of type 2 diabetes [1].

Interventions to reduce blood glucose significantly lower the risk of microvascular and macrovascular disease [2] [3] [4] [5].

A number of nutritional, hormonal and genetic factors may result in metabolic disruption of these interrelated pathways that is associated with various pathological conditions, including cardiovascular diseases and neurodegenerative diseases [6].

Folate is a water-soluble  $\beta$ -vitamin critical for health as a cofactor in a multitude of single-carbon transfer reaction. The folate is an essential vitamin for humans and is obtained from the diet, especially from fruits and vegetables. Folate is required for nucleotide and methionine biosynthesis [7].

Folic acid requires reduction to tetrahydrofolate and needs 1-carbon substitution to commence its task as 1-carbon donor for methylation and DNA-RNA synthesis. During passage of small amounts of folic acid through the gut cells and liver

reduction and l-carbon substitution is complete, and 5- methyltetrahydrofolate is by far the most predominant form entering the systemic circulation.

Folate transport across epithelia and into systemic tissues occurs via the reduced folate carrier, the folate reception family, and the recently discovered proton-coupled folate transporter [8].

Nutritional deficiencies, particularly those involving B groups vitamins and folate, important cofactors of homocysteine metabolism, are commonly related with high circulating levels of Hcy.

Therefore, changes in folate status may influence the DNA stability and integrity are affect the methylation patterns in some tissues and predispose it to development of DR.

However, very little evidence is currently available to suggest that folate deficiency alone leads diabetic retinopathy.

In this study we investigate the folate status in patients with diabetic retinopathy.

## **Methods and Patients**

### **Patients**

A total of 231 diabetic were consecutively recruited from people attending our department at Cannizzaro Hospital. The mean age was  $63.4 \pm 10.2$  years. In this

group there were 111 women and 120 men. The mean duration  $8.2 \pm 4.6$  years. 80 control subjects (42 men and 38 women) were recruited from the clinical and laboratory staff and blood donors. None of the controls had a known history of macroangiopathy, nephropathy, retinopathy or neuropathy.

Diabetes was diagnosed and classified according to the World Health Organization criteria.

Patients with familial hypercholesterolemias, with hypothyroidism, with chronic liver disease, with advanced renal disease, with malignancies were excluded.

None of the patients were taking lipid lowering drugs or glitazones, folate, oral contraceptive pills or hormone replacement therapy.

All participants included in this analysis had an eye examination and completed a questionnaire which collected ocular and medical history.

## **Methods**

A trained phlebotomist drew 20 mL blood from each research patients after overnight fast.

Six evacuated blood collection tubes were obtained: three tubes with a serum separator and three with EDTA (ethylenediaminetetracetic acid as anticoagulant).

For the red blood cell folate assay 0.100 ml whole blood was added to 2 mL 0.2 % ascorbic acid before storage. Next, the tubes were placed on ice and centrifugated at  $2900 \times g$  10 minutes at  $4^{\circ}\text{C}$ . The blood was separated into plasma and samples were stored at  $-45^{\circ}\text{C}$  until the analysis. Fasting plasma glucose was measured in

fresh specimens with a hexokinase reagent kit. Fasting plasma triglyceride and total cholesterol levels were measured enzymatically and the HDL cholesterol fraction was measured after precipitation of LDLs and VLDs with dextran sulphate magnesium. Low-density lipoprotein (LDL) level was calculated by using the Friedwald's formula [15]. Serum creatinine levels (upper reference limit 120  $\mu\text{mol/l}$ ) were assayed with routine laboratory method.

Plasma tHcy concentrations were determined using an immunoassay. Folate concentration in plasma and RBC folate in whole blood hemolysate sample were measured using Quantaphase radioassay Kit (Bio-Rad Laboratories).

Measurement of HbA1c was made by high-performance liquid chromatography (Menarini Diagnostics, Italy). All assays were completed in duplicate. For the folate assessments the intra-assay coefficient of variation was 3.7%, whereas the inter-assay coefficient of variation was 6.4%.

### **Clinical Assessment**

Clinical Assessment consisted of anthropometric measurements, which included height, weight, body mass index (BMI) and waist to hip ratio. Measurements of heart rate, systolic blood pressure, and diastolic blood pressure were also obtained. The systolic and diastolic blood pressure levels were measured in the right arm by standard methods with the participants in a relaxed sitting position, using a mercury sphygmomanometer.

### **Assessment of diabetic retinopathy**

The presence and severity of diabetic retinopathy were assessed from ophthalmoscopy and/or biomicroscopy through dilated pupils and fluorescein angiography when indicated. Retinopathy was classified as absent, non proliferative and proliferative.

### **Statistical analysis**

Statistical analyses were performed using SPSS 15.0 (Chicago IL). All data are presented as mean  $\pm$  standard deviation. Continuous variables were compared using the two-sample t-test or Mann Whitney U test, were applicable.

To verify the diagnostic value of both serum folate and red blood folate, receiver operating characteristic (ROC) curves were plotted and the area under the curve (AUC) was calculated.

To evaluate the diagnostic performance of each biochemical marker to discriminate about diagnosis, the sensibility, the specificity and the positive (PPV) and negative (NPV) predictive value of different tests were calculated.

### **Results**

In our study 135 out of 231 enrolled patients had DR (Table 1). The patients are divided into three groups: patients with proliferative diabetic retinopathy, with non-proliferative diabetic retinopathy and without retinopathy. As regards diabetic

management, 64 were on dietary treatment, 117 on metformin treatment, and 50 on insulin treatment.

### *Laboratory parameters*

Subjects with PDR had higher glycated haemoglobin levels compared with patients without retinopathy ( $P<0.01$ ) and fasting plasma glucose compared to subjects with NPDR ( $p<0.05$ ).

No significant differences were observed comparing subjects with PDR vs subjects with NPDR in total cholesterol, LDL, and triglycerides. (Table 2a).

As regards creatinine levels, randomly selected patients showed significant differences compared to PDR and controls ( $p<0.001$ ); PDR also showed differences compared to randomly selected patients ( $p<0.001$ ), NPDR ( $p<0.05$ ) and diabetics without retinopathy ( $p<0.05$ ); NPDR showed differences compared to randomly selected patients ( $p<0.05$ ) and healthy controls ( $p<0.001$ ); controls showed differences compared to all other groups ( $p<0.001$ ); diabetics without retinopathy showed differences compared to PDR and controls ( $p<0.001$ ).

For plasmatic folic acid, randomly selected patients showed significant differences compared to PDR and NPDR ( $p<0.001$ ); PDR showed differences of plasmatic folic acid deficiency compared to randomly selected patients ( $p<0.001$ ), NPDR ( $p<0.05$ ), healthy controls ( $p<0.001$ ) and diabetics without retinopathy ( $p<0.001$ ); NPDR showed differences compared to randomly selected patients ( $p<0.001$ ), PDR ( $p<0.05$ ), healthy controls ( $p<0.001$ ) and diabetics without retinopathy



( $p < 0.05$ ); plasmatic folic acid healthy controls showed differences compared to PDR ( $p < 0.001$ ), NPDR ( $p < 0.001$ ), and diabetics without retinopathy ( $p < 0.05$ ); for red cell folate deficiency, randomly selected showed significant differences compared PDR ( $p < 0.001$ ) and NPDR ( $p < 0.001$ ). PDR showed reduced red cell folate compared to randomly selected subjects ( $p < 0.001$ ), NPDR, controls and patients without diabetic retinopathy ( $p < 0.001$ ) (tab.2b).

We found that both plasmatic folic acid and red cell folate in these patients were not associated with smoke and BMI. It was found an association with age, gender and severity of retinopathy. Besides plasmatic folic acid is inversely with homocysteine ( $p < 0,05$ ); red cell folate is related with HbA1c ( $p < 0,01$ ) and inversely with homocysteine ( $p < 0,01$ ). The correlation between plasmatic and red cell folate were significant ( $p < 0,05$ ).

The values of sensitivity of folate deficiency for PDR, NPDR and without retinopathy groups were respectively 81%, 78% and 76%. The specificity were respectively 85%, 73% and 54%. Predictive value of positive test were 81%, 64% and 41%. Predictive value of negative test is 85%. The Odds ratio (OR) of PF and RBCF were in Diabetic without retinopathy respectively 2.2 and 3.6 in NPDR 16.6 and 30.4, in PDR 30.9 and 57.75.

## **Discussion**

Numerous factors have shown as having an effect on the development and progression of diabetic retinopathy [9-14]. The results of the present study show

that lower levels of both folic acid plasmatic and red blood cell folate were observed in patients with diabetes irrespective of the presence of retinopathy. However the association between Plasma Folate is higher in proliferative retinopathy than non proliferative retinopathy and in without retinopathy. High levels of plasma homocysteine are toxic to the vascular endothelium and induce thrombosis via the formation of free radicals.

Any alteration in folate metabolism leads to deficiency of methyltetrahydrofolate, thereby impairing remethylation of homocysteine. Plasma folate is a marker for recent folate intake, as concentrations change after the intake of folate and is quite limited in determining folate status. RBC represents a long term marker as the red blood cell folate pool turns over slowly and represents folate stores. Concentration levels change slowly as folate is incorporated to RBCs, accumulated only during erythropoiesis and RBCs have a half-life of 120 days. Kinetic studies have shown that the half-life of red cell folate closely matches the half-life of red blood cells, 60 days [15]. In contrast, circulating PF changes rapidly after intake [16]. In our study the diabetic patients with both PDR and NPDR shows a significant deficiency in folic acid plasmatic and in red cell folate compared with healthy subjects and randomly selected patients and diabetic without retinopathy.

Folic acid plays an important role in the re-methylation (methionine – folate cycle) of homocysteine and is thus capable of lowering elevated levels of homocysteine.

Red blood cell folate and plasma folate levels are widely accepted direct biochemical indicators of folate status. Therefore we included RBC folate, since it is recognized as an indicator of folate stores in the body.

The high sensitivity and specificity of folate deficiency for PDR versus both NPDR and without retinopathy represents an important predictive value on diabetic retinopathy. Serum folate concentrations fluctuate rapidly with recent changes in folate intakes and with temporary changes in folate metabolism even when body stores remain stable. Serum folate alone does not differentiate between what may be a transitory reduction in folate intake or chronic folate deficiency accompanied by depleted folate stores and functional changes. Consequently, misclassification of folate levels may have occurred.

In our study low levels of PF and RBF shows a significant inverse correlation with Hcy. The main mechanisms of hyperhomocysteinemia for the development of atherothrombosis are endothelial injury, platelet activation, and oxidative modification of low density lipoproteins [16-18].

Increasing evidence suggested that the proliferation rate of cells would cause an elevation of circulating tHcy or an increase in the concentration of cells would deplete folate and inactivate the methionine synthase catalyzed remethylation reaction.

Deficiency or impairment of folate metabolism is associated with HHcy, hypomethylation (the decreased on carbon unit transfer to purines and pyrimidines

for DNA repair and biosynthesis), DNA damage, and impaired cell proliferation, malignancies and impaired e NO production. Recent work indicates that DNA methylation is an important player in both DNA repair and gene stability. Low folate levels was related to DNA damage and global DNA hypomethylation.

It has been suggested that the inactivation of DNA repair pathways, which leads to an increased mutation rate and chromosomal instability, can initiate and accelerate the proliferative process [19].

Thus, understanding and characterizing the epigenetic regulators and their role in the pathogenesis of diabetic retinopathy could help in identifying novel target to combat this blinding disease which is the major cause of blindness in adults.

Deficiencies in the cofactors folate, pyridoxine and vitamin B12 have been demonstrated to elevate plasma Hcy.

Red folate blood is strong related to HbA1C. Analysis of folate in red cells is considered to be a strong indicatory of folate adequacy because it reflects intracellular status and is not influenced by recent or transient changes in dietary folate intake. Tissue folate status is assessed by measurement of total folate concentration in blood because available assays are unable to differentiate between the various circulatory forms.

The potential link between the microvascular changes that occur in diabetic retinopathy and folate deficiency may be useful as a predictor for retinopathy. Diabetic retinopathy is one of the micro-vascular complications of diabetes which may not have symptoms in the early stages. Control of these complications

depends on proper management and monitoring of retinal status and blood glucose levels after the early detection of retinopathy, but may progress to a sight-threatening stage if left untreated. Base on this data folate status could play a role in the development and progression of diabetic retinopathy. The recovery or delay of diabetic retinopathy by folate supplement treatment could help their hypothesis.

### **Acknowledgment**

G.M has been supported by the International Ph. D. program in Neuropharmacology, University of Catania.

### **Conflict of interests**

The authors declare that they have no conflict of interest.

## References

1. Mehlsen J, Erlandsen M, Poulsen PL, et al. Identification of independent risk factors for the development of diabetic retinopathy requiring treatment. *Acta Ophthalmol.* 2011; 89: 515-21.
2. Madsen-Bouterse SA, Kowluru RA. Oxidative stress and diabetic retinopathy: pathophysiological mechanisms and treatment perspectives. *Rev Endocr Metab Disord.* 2008; 9: 315-27.
3. Rampello L, Vecchio I, Malaguarnera G, et al. Diabetic neuropathy. Diagnosis. *Acta Medica Mediterranea.* 2012; 28: 133.
4. Zhang W, Liu H, Al-Shabrawey M, et al. Inflammation and diabetic retinal microvascular complications. *J Cardiovasc Dis Res.* 2011; 2: 96-103.
5. Mujumdar VS, Aru GM, Tyagi SC. Induction of oxidative stress by homocyst(e)ine impairs endothelial function. *J Cell Biochem.* 2001; 82: 491-500.
6. Marrazzo G, Barbagallo I, Galvano F, et al. Role of dietary and endogenous antioxidants in diabetes. *Crit Rev Food Sci Nutr.* 2014;54:1599-616.
7. Stover PJ. Physiology of folate and vitamin B12 in health and disease. *Nutr Rev.* 2004; 62: s3-12.
8. Zhao J, Cao SI, Zheng XI, et al. Folate receptor-mediated antitumor drugs. *Yao Xue Xue Bao.* 2009;44:109-14.

9. Malaguarnera M, Vacante M, Russo C, et al. Lipoprotein(a) in cardiovascular diseases. *Biomed Res Int*. 2013;2013:650989.
10. Miller A, Mujumdar V, Palmer L, et al. Reversal of endocardial endothelial dysfunction by folic acid in homocysteinemic hypertensive rats. *Am J Hypertens*. 2002
11. Miller A, Mujumdar V, Shek E, et al. Hyperhomocyst(e)inemia induces multiorgan damage. *Heart Vessels*. 2000; 15: 135-43.
12. Veeranna V, Zalawadiya Sk, Niraj A, et al. Homocysteine and reclassification of cardiovascular disease risk. *J Am Coll Cardiol*. 2011; 58: 1025-33.
13. Galvano F, Malaguarnera M, Vacante M et al. The physiopathology of lipoprotein (a). *Front Biosci (Schol Ed.)* 2010 1;2:866-75
14. Malaguarnera G, Gagliano C, Bucolo C et al. Lipoprotein(a) serum levels in diabetic patients with retinopathy. *BioMed Int Research*. 2013;2013:943505
15. Pietrzik K, Lamers Y, Brämswig S, et al. Calculation of red blood cell folate steady state conditions and elimination kinetics after daily supplementation with various folate forms and doses in women of childbearing age. *Am J Clin Nutr*. 2007; 86: 1414-9.
16. Prinz-Langenohl R, Brönstrup A, Thorand B, et al. Availability of food folate in humans. *J Nutr*. 1999; 129: 913-6.

17. Ozkan Y, Ozkan E, Simşek B. Plasma total homocysteine and cysteine levels as cardiovascular risk factors in coronary heart disease. *Int J Cardiol.* 2002; 82: 269-77.
18. Lynch SM. Assessment of student pharmacists' knowledge concerning folic acid and prevention of birth defects demonstrates a need for further education. *J Nutr.* 2002; 132: 439-42.
19. Malaguarnera G, Gagliano C, Giordano M, et al Homocysteine serum levels in diabetic patients with non proliferative, proliferative and without retinopathy *Biomed Res Int.* 2014; 2014:191497



Table 1. Demographic characteristics of the study population

Patients with type II diabetes Mellitus (n=231)	PDR 65	NPDR 70	WR 96
Female/Male	30/35	40/30	41/55
Age (years)	65.8 ± 10.4	64.1±10.8	56.8±10.2
Smokers/No smokers)	45/20	56/14	67/32
BMI (Kg/m <sup>2</sup> )	26.1±3.2	26.4±3.9	27.4±38
Waist circumference (cm)	94.1±8.71	95.0±7.4	94.2±7.6
Hip circumference (cm)	96.7±8.25	96.8±7.44	96.1±79.7
Waist-to-hip ratio	0.97±0.08	0.9±0.9	0.97±0.06
Systolic blood pressure (mmHg)	138.6±13.4	138.2±14.1	144.1±8.2
Diastolic blood pressure (mmHg)	81.8±8.7	84.7±7.9	84.1±8.1

Table 2a. Laboratory parameters of subjects included in the study

Parameter	PDR 65	NPDR 70	Without DR 96
Cholesterol total (mmol/l)	6.02±0.98	5.96±0.96*	5.94±0.87*
HDL (mmol/l)	1.44±0.37	1.40±0.41*	1.39±0.39*
LDL (mmol/l)	4.29±0.39	4.28±0.38*	4.27±0.34*
Triglycerides (mmol/l)	1.84±0.58	1.72±0.59*	1.74±0.67*
Fasting plasma glucose (mg/dl)	168.8±31.4	155.1±30.2**	160.4±30.7*
HbA1c (%)	8.1±0.8	7.9±0.7*	6.9±0.8***

Comparison between PDR and other groups: P=NS\*; P<0.05 \*\*; P<0,001\*\*\*

Table 2b. Laboratory parameters of subjects included in the study

	PDR n=65	NPDR n=70	Diabetics without retinopathy n=96	Controls (healthy subject) n=80
Creatinine (mg/dl)	99.2±18.2 <sup>***E§§§†††</sup>	91.4±16.4 <sup>***B§§§†</sup>	90.1±18.2 <sup>*CD§§§</sup>	76.2±13.2 <sup>CF†††</sup>
Hcy (µmol/l)	18.8 ± 5.6 <sup>***E§§§†††</sup>	15.6 ± 6.0 <sup>***B§§§†</sup>	12.4±7.2 <sup>*CE§§§</sup>	7.9 ± 6.7 <sup>CF†††</sup>
Folic acid nmol/L	4.6± 1.9 <sup>***E§§§†††</sup>	5.4± 2.4 <sup>***B§§§††</sup>	6.9 ± 3.6 <sup>*CE§§</sup>	8.4± 3.9 <sup>CF††</sup>
Red cell folate nmol/L	168.5±24.1 <sup>***F§§§††††</sup>	196.6±31.8 <sup>***C§§§†</sup>	204.4± 6.9 <sup>*CD§§</sup>	221± 41.8 <sup>CF††</sup>

Comparison between PDR and other groups: P=NS<sup>A</sup>; P<0.05<sup>B</sup>; P<0.001<sup>C</sup>

Comparison between NPDR and other groups: P=NS<sup>D</sup>; P<0.05<sup>E</sup>; P<0.001<sup>F</sup>

Comparison between controls and other groups: P=NS<sup>§</sup>; P<0.05<sup>§§</sup>; P<0.001<sup>§§§</sup>

Comparison between diabetic without retinopathy and other groups: P=NS<sup>†</sup>;  
P<0.05<sup>††</sup>; P<0.001<sup>†††</sup>

Table 3. Sensitivity, specificity, predictive value, odds ratio in diabetic patients

	PDR proliferative diabetic retinopathy	NPDR non proliferative diabetic retinopathy
Sensitivity	64%	63%
Specificity	70%	70%
Predictive value of positive test	69%	54%
Predictive value of negative test	65%	50%
Efficiency of the test	67%	51%
Prevalence	52%	51%
Odds ratio	4.24	1.16
Likelihood ratio for positive test	2,13	2,1
Likelihood ratio for negative test	1,94	1,1

## Chapter 3

### Role of Homocysteine in Retinal Neurodegeneration

Giulia Malaguarnera<sup>1,2,3</sup>, Shereen Nizari<sup>1</sup>, Lisa A. Turner<sup>1</sup>, James Brodie<sup>1</sup>, Benjamin Davis<sup>1</sup>, Li Guo<sup>1</sup>, Eduardo M. Normando<sup>1</sup>, Claudio Bucolo<sup>2-3</sup>, Filippo Drago<sup>2-3</sup>, Francesca Cordeiro<sup>1-4</sup>

Affiliations:

<sup>1</sup>Glaucoma and Retinal Neurodegeneration Group, Department of Visual Neuroscience, UCL Institute of Ophthalmology, London EC1V 9EL, UK,

<sup>2</sup> International PhD programme in Neuropharmacology, University of Catania

<sup>3</sup> Department of Clinical and Molecular Biomedicine, Section of Pharmacology and Biochemistry, University of Catania, Viale Andrea Doria 6, 95125 Catania, Italy.

<sup>4</sup>The Western Eye Hospital, Imperial College Healthcare Trust, London NW1 5QH, UK.

---

Address for Correspondence

To Prof. M. Francesca Cordeiro,

Department of Visual Neuroscience,

UCL Institute of Ophthalmology,

11-43 Bath Street,

London

EC1V 9EL, UK

Tel. +44 (0)20 7608 6938

Fax. +44 (0)20 7608 6939

Email: [m.cordeiro@ucl.ac.uk](mailto:m.cordeiro@ucl.ac.uk)

---

## **Abstract**

Epidemiological studies have linked type 2 diabetes mellitus (T2DM) with an increased risk of Alzheimer's Disease (AD). Histopathological, molecular, and biochemical abnormalities are in common with these two major disease, rising the hypothesis that the AD is the diabetes type3. Several well-defined neurodegenerative conditions that affect the brain have manifestations in the eye, and ocular symptoms often precede conventional diagnosis of such CNS disorders. High level of Homocysteine (Hcy), a sulfur amino acid, in the plasma had been associated with both AD and T2DM. The aim of our study was to investigate whether the Hcy could affect the retinal neurodegeneration in animal models of AD, TASTPM mice, and T2DM, Goto-Kakizaki (GK) rats.

**Keywords:** Homocysteine (Hcy), Diabetic retinopathy, Alzheimer's Disease, Goto-Kakizaki (GK) rats, TASTPM mice, Retinal neurodegeneration, Beta-Amyloid (A $\beta$ ), Amyloid Precursor Protein (APP), caspase-3, COX-1.

## **Introduction**

An estimated 24 million people worldwide have dementia, the majority of whom are thought to have Alzheimer's Disease (AD) (Ballard et al., 2011). Several studies have explored sensory deficiencies in AD, particularly

---

correlations between disease progression and visual dysfunction (Rizzo, Anderson, Dawson, & Nawrot, 2000). Careful study of retinal pathology and function in AD eyes has suggested that local tissue damage plays an important role, with relevant comparisons to common causes of vision loss and blindness. Researchers have shown many manifestations of AD to be detectible in the retinae of human and transgenic models of AD (Dehabadi et al., 2014).

According to the World Health Organization, 347 million people worldwide have diabetes. Type 2 Diabetes Mellitus (T2DM) occurs with aging and it is characterized by high blood glucose levels resulting from increased hepatic glucose production, impaired insulin production and peripheral insulin resistance, which closely resembles brain insulin resistance described in AD patients (Butterfield, Di Domenico, & Barone, 2014)

Both AD and T2DM are multifactorial degenerations of central nervous system (CNS) tissue, in which age is a primary risk factor. Pathologically, they all feature progressive deposition of protein aggregates, including extracellular amyloid  $\beta$  ( $A\beta$ ) plaques and intracellular microtubule inclusions containing hyperphosphorylated tau protein (pTau). Additional common features include prominent glial reactivity, neuroinflammation, and increased metabolic and oxidative stress. Importantly, despite many years of intense research, in each case the damage-triggering mechanism continues to be



---

debated. Retinal neurodegeneration is an early event in the pathogenesis of Diabetic Retinopathy (DR) (Simó & Hernández, 2012). Type 2 diabetes (T2DM) is characterized by insulin resistance, defective insulin secretion, loss of  $\beta$ -cell mass with increased  $\beta$ -cell apoptosis and islet amyloid. The islet amyloid is derived from islet amyloid polypeptide (IAPP, amylin), a protein co-expressed and co-secreted with insulin by pancreatic  $\beta$ -cells. In common with other amyloidogenic proteins, IAPP has the propensity to form membrane permeant toxic oligomers. Growing evidence suggests that these toxic oligomers, rather than the extracellular amyloid form of these proteins, are responsible for loss of neurons in neurodegenerative diseases (Moreira, Santos, Seiça, & Oliveira, 2007).

We previously had demonstrated that high plasma level of Homocysteine occurs in diabetic patients with non-proliferative diabetic retinopathy and proliferative diabetic retinopathy, suggesting that higher levels were associated with more severe diabetic eye disease (Malaguarnera et al., 2014).

Homocysteine is an important sulphur amino acid connected to vitamin B12 and folate that is metabolized by remethylation to methionine and by transsulfuration to cysteine. It is reversibly formed and secreted in the process of metabolism and can be considered as an effective neurotoxin possibly mediated through the increased generation of free radicals or by calcium influx through NMDA receptor channels (Hu et al., 2012).

---

Hyperhomocysteine is found usually in both genetic and nongenetic metabolic disorders. The toxic effects of hyperhomocysteinaemia have been recognized as an independent risk factor in cardiovascular disease (Welch & Loscalzo, 1998) and its high plasma level have been linked with neurodegenerative conditions (Herrmann & Obeid, 2011).

There is increasing evidence that elevated plasma homocysteine is associated with cognitive dysfunction and dementia (Adunsky et al., 2005; Reif, Pfuhlmann, & Lesch, 2005). Interestingly, hyperhomocysteinaemia has been directly linked to psychosis, depression, and other psychiatric disorders (Atmaca, Tezcan, Kuloglu, Kirtas, & Ustundag, 2005; Chen et al., 2005; Reif et al., 2005). Hyperhomocysteinaemia is believed to play an important role in pathogenesis of AD and plasma homocysteine concentrations have been positively correlated with illness duration in AD patients (Morris, 2003), as well as with disease progression (Nilsson, Gustafson, & Hultberg, 2002). The etiology of AD is complex, but it is known to be multifactorial. Homocysteine may be a contributory as opposed to primary factor, although its involvement appears to be important.

The aim of this study was to investigate whether the Homocysteine has a role in the development of retinal neurodegeneration. Initially, we assessed its presence in the retina in an animal model of T2DM using the Goto-Kakizaki model, which is a spontaneous non obese T2DM rat which exhibit large

---

changes in the gene expression profiles of the hippocampus and prefrontal cortex comparing with Wistar rats, supporting their association with AD (Abdul-Rahman et al., 2012). We then went on to see if hcy in the retina was also linked to the development of AD. This was performed using a transgenic TASTPM mice which mimics various hallmarks of AD such as high levels of circulating A $\beta$  protein and its deposition in the form of plaques in the brain, with cognitive and behavioural deficits (Howlett et al., 2004) and neuroinflammation.

## **Materials and Methods**

### ***Animals***

All experiments were approved by the UK Home Office and the University College London Ethics Committee, in accordance with the GlaxoSmithKline statement on use of animals and the Association for Research in Vision and Ophthalmology statement.

The animals were housed in a controlled environment with standard food and water *ad libitum* in a 12-hour light/12-hour dark cycle.

Goto-Kakizaki (GK) rat eyes of 3, 12 and 18 months were obtained from The Hatter Institute, UCL and compared with aged-matched Wistar rats (n= 3, 4 per group). The GK rats are a non-obese spontaneous type 2 diabetic model

---

obtained by selective breeding of Wistar rats with glucose tolerance (Goto, Kakizaki, & Masaki, 1976).

2,4,8,12 months male heterozygous TASTPM mice, a heterozygote double mutant mice over-expressing the hAPP695swe mutation (TAS10) and the presenilin-1 M146V mutation (TPM) (Howlett et al., 2004), had been studied as a model of Alzheimer's disease neurodegeneration compared with aged-matched male C57Bl/6j mice (n=3 per group).

At the indicated timepoints, animals were killed, enucleated and eyes fixed in 4% paraformaldehyde.

### ***Immunohistochemistry***

GK rats eyes were dissected at the equator, and the cornea, lens and vitreous were removed. The GK rats and Wistar rats dissected eyes and the whole eyes of TASTPM and C57Bl/6j mice were fixed in 10% formalin solution and then processed in a series of methanol solutions with increasing concentrations, followed by embedding in paraffin. The sections were cut at 4 $\mu$ m.

The slides were washed with xylene to remove the paraffin, then in ethanol in descending concentration (100%, 90% and 70%) and cold running water, followed by the blocking of endogenous peroxidases with 3% of H<sub>2</sub>O<sub>2</sub>. The antigens were unmasked using citrate buffer at pH=6, excluding for the

---

staining of the anti-NMDA receptor 2B (Millipore, 1:400 dilution for IHC-P) which required the EDTA buffer with alkaline pH. After 1 hour incubation with 5% Normal Donkey Serum, diluted in Tris[(1-benzyl-1H-1,2,3-triazol-4-yl)methyl]amine (TBTA), the sections were incubated with the primary antibody (Table...) at 4° in a humidifying chamber overnight. The secondary antibody (AlexaFluor 488 or AlexaFluor 555, Life Technology) were added and incubated for 1 hour. To mark the nuclei 4,6-diamidino-2-phenylindole (DAPI) was added for 1 minute (1:2500 dilution of 1µg/ml).

### ***Microscopy and Statistical Data Analysis***

Stained sections were analysed using fluorescent microscopy (Zeiss Axiovert S100) at x20 and x10 magnification with specific analysis of the RGCL. The mean fluorescence intensity was analysed with ImageJ software. The statistical data used was unpaired t-test.

## **Results**

### ***Homocysteine levels in GK RGC Layer***

The levels of Homocysteine (hcy) in the retinal ganglion cell layer (RGCL) of GK-rats were analysed in order to evaluate whether Hcy presence was associated with disease. . Increased hcy fluorescence was found in 12-month and 18-month GK-rats retinas as compared to the 3-month GK-rats and age-

---

matched controls ( $p>0.05$  and  $p>0,005$  respectively) (Figure 1). In contrast, control retina showed similar hcy fluorescence over time.

### ***Homocysteine and neurodegeneration in TASTPM RGC Layer***

We next analysed retinal neurodegenerative changes in TASTPM mice. Increased hcy fluorescence was found in 4-month TASTPM retinas as compared to age-matched controls ( $p>0.05$ ). In contrast, similar hcy fluorescence levels were found in 12 month TASTPM and control retina, although levels were decreased in 2 and 8 month TASTPM retinas as compared to age-matched controls (Figure 2).

Increased Amyloid beta ( $A\beta$ ) fluorescence was found in 4-month TASTPM retinas as compared to age-matched controls ( $p>0.05$ ) (Figure 4). There was no significant difference at any other time points. Amyloid Precursor Proteine (APP) fluorescence was found increased in the 4-month TASTPM RGCL as compared to age-matched controls ( $p>0.05$ ) (Figure 3). Although the APP fluorescence were found increased also in the 12 month TASTPM mice, the levels were not significant ( $p=0,06$ ) compared to aged-matched control and 8 months TASTPM. Cleaved Caspase-3 fluorescence was significantly increased in the 4-month TASTPM as compared to the 2-month TASTPM and to age-matched controls (Figure 5).

---

Increased levels of COX-1 fluorescence were observed in the 8 month TASTPM RGCL (Figure 6). Interestingly, the COX-1 levels reached the maximum levels in the 12 month TASTPM retinas as compared to 2, 4, 8 month TASTPM retinas and age- matched controls. This result indicated an increased activity in inflammation and neurodegeneration.

## **Discussion**

In the present study we have found increasing levels of homocysteine in the RGCL of GK rats with age, being significantly elevated at 12 and 18 months compared controls. As this may have been linked to the changes of AD seen in GK rats, we next examined the role of Hcy in AD. We found significantly increased levels of RGCL hcy in TASTPM mice – a transgenic model of AD. This elevation coincided with significant increases in levels of A $\beta$ , APP and cleaved-caspase 3 in the RGCL at 4 months.

Unlike most rodent models of T2DM (ob/ob mouse, db/db mouse, ZDF rat, OLEFT rat), the GK-rats are nonobese, nonketotic, and display mild fasting hyperglycemia. From the birth to the weaning period, GK-rats are normoglycemic. However, at 1 month, these animals have a profound alteration in glucose-stimulated insulin secretion by the GK pancreatic  $\beta$ -

---

cell, accompanied by increased hepatic glucose production and peripheral insulin-resistance which increases with age as the animal enters adulthood. Both retinopathy and nephropathy have been reported at 12 months of age (Portha, 2005). Moreover, our group has found enhanced levels of A $\beta$ , APP, phosphorylated-tau and apoptosis in the retinae of 12-month GK-rats (personal communication T Wong, M Phillips). Therefore, our new findings reported in this study indicate that in GK rats the higher levels of hcy are linked to the development of retinal neurodegeneration.

Howlett. et al have extensively studied the relationship between AD neuropathology and the development of cognitive impairment in TASTPM mice (Howlett et al., 2004). They have observed increasing cerebral A $\beta$  deposition from 3 months in an age-dependent manner. At 6 months, when cognitive impairment is apparent, mature A $\beta$  plaques comprising a fibrillar core surrounded by degenerating neurites and reactive glia are described in TASTPM cortex. To our knowledge, this is the first study showing the link between increased levels of A $\beta$ , APP and hcy, although hcy is recognised as a potential AD biomarker (Thambisetty & Lovestone, 2010). Overall, recent findings suggest that the presence of hcy is associated with increased levels of A $\beta$  oligomers, potentiating their neurotoxic effect (Khodadadi et al., 2012; Inna I Kruman et al., 2000; Pacheco-Quinto et al., 2006). These studies are in keeping with our findings, namely that hcy



---

with increasing retinal A $\beta$  and APP, promotes the activation of caspase-3, leading to apoptosis and neurodegeneration of the retina.

Several studies linking diabetes and Alzheimer's disease support the hypothesis that the AD could be regarded as diabetes type3 (de la Monte & Wands, 2008). Epidemiological evidence (Biessels & Kappelle, 2005), histopathological, molecular, and biochemical abnormalities, including amyloidogenesis, insulin signaling impairment (Steen et al., 2005), advanced glycation end products, mitochondria dysfunction (Moreira et al., 2007), oxidative stress and inflammation (Yang & Song, 2013), are in common with these two major disease.

High levels of homocysteine in the plasma have been described in both diseases, suggesting that it may play a crucial role in the progression of AD, neurodegeneration and diabetes. (Herrmann & Obeid, 2011). *In vitro* and *in vivo* studies have shown that homocysteine is a potent excitatory neurotransmitter that binds to the NMDA (N-methyl-D-aspartate) receptor and leads to cytoplasmic calcium influx, cellular apoptosis and endothelial dysfunction (McCully, 2009). Hcy has also been linked with a reduction in expression of Glucose Transporter-1 and cerebrovascular eNOS (endothelial nitric oxide synthase) (Lee, Kim, Kim, & Chang, 2004), and the presence of vacular damage and lipid peroxidation may account for the described

---

impaired learning and memory performance (Ho et al., 2003; Obeid & Herrmann, 2006).

High levels of homocysteine, due to dietary deficiencies in folate and vitamins B6 and B12 or to genetic deficiency in Cystathionine- $\beta$ -synthase (Cbs +/-), have been associated with damage to the blood brain barrier (Kamath et al., 2006). This in itself may lead to neurodegeneration. However, there is further evidence that elevated hcy can increase production of mitochondrial ROS (reactive oxygen species) (Inna I Kruman et al., 2000), although whether this is associated with Amyloid beta is not well-know. However, high levels of Amyloid beta oligomers, A $\beta$ -40 and A $\beta$ -42, have been found in both Cbs +/- and APP and PS1 mice brain (Pacheco-Quinto et al., 2006), but are also induced in primary cortical neurons treated with Hcy (10-100  $\mu$ M) (Inna I Kruman et al., 2000).

According to this, also our study confirm not only the strict like between these disease in the retinopathy associated both to diabetes and AD, but also the key role of homocysteine in neurodegeneration.

### **Acknowledgments**

G.M has been supported by the International Ph. D. program in Neuropharmacology, University of Catania. None of the authors had any relevant personal or financial conflict of interests.

---

## Reference

- Abdul-Rahman, O., Sasvari-Szekely, M., Ver, A., Rosta, K., Szasz, B. K., Kereszturi, E., & Keszler, G. (2012). Altered gene expression profiles in the hippocampus and prefrontal cortex of type 2 diabetic rats. *BMC Genomics*, *13*(1), 81. doi:10.1186/1471-2164-13-81
- Abu El-Asrar, a M., Dralands, L., Missotten, L., & Geboes, K. (2007). Expression of antiapoptotic and proapoptotic molecules in diabetic retinas. *Eye (London, England)*, *21*(2), 238–45. doi:10.1038/sj.eye.6702225
- Adunsky, A., Arinzon, Z., Fidelman, Z., Krasniansky, I., Arad, M., & Gepstein, R. (2005). Plasma homocysteine levels and cognitive status in long-term stay geriatric patients: a cross-sectional study. *Archives of Gerontology and Geriatrics*, *40*(2), 129–38. doi:10.1016/j.archger.2004.07.001
- Ahsan, H. (2014). Diabetic retinopathy - Biomolecules and multiple pathophysiology. *Diabetes & Metabolic Syndrome*, 10–13. doi:10.1016/j.dsx.2014.09.011
- Atmaca, M., Tezcan, E., Kuloglu, M., Kirtas, O., & Ustundag, B. (2005). Serum folate and homocysteine levels in patients with obsessive-compulsive disorder. *Psychiatry and Clinical Neurosciences*, *59*(5), 616–20. doi:10.1111/j.1440-1819.2005.01425.x
- Ballard, C., Gauthier, S., Corbett, A., Brayne, C., Aarsland, D., & Jones, E. (2011). Alzheimer's disease. *Lancet*, *377*, 1019–1031. doi:10.1016/S0140-6736(10)61349-9
- Barber, a J., Lieth, E., Khin, S. a, Antonetti, D. a, Buchanan, a G., & Gardner, T. W. (1998). Neural apoptosis in the retina during experimental and human diabetes. Early onset and effect of insulin. *The Journal of Clinical Investigation*, *102*(4), 783–91. doi:10.1172/JCI2425

- 
- Bates, C. J. (1991). Glutathione and related indices in rat lenses, liver and red cells during riboflavin deficiency and its correction. *Experimental Eye Research*, *53*, 123–130. doi:10.1016/0014-4835(91)90154-7
- Bek, T., Lund-Andersen, H., Hansen, A. B., Johnsen, K. B., Sandbæk, A., & Lauritzen, T. (2009). The prevalence of diabetic retinopathy in patients with screen-detected type 2 diabetes in Denmark: The ADDITION study. *Acta Ophthalmologica*, *87*, 270–274. doi:10.1111/j.1755-3768.2008.01207.x
- Beulens, J. W. J., Patel, A., Vingerling, J. R., Cruickshank, J. K., Hughes, A. D., Stanton, A., ... Stolk, R. P. (2009). Effects of blood pressure lowering and intensive glucose control on the incidence and progression of retinopathy in patients with type 2 diabetes mellitus: A randomised controlled trial. *Diabetologia*, *52*, 2027–2036. doi:10.1007/s00125-009-1457-x
- Biessels, G. J., & Kappelle, L. J. (2005). Increased risk of Alzheimer's disease in Type II diabetes: insulin resistance of the brain or insulin-induced amyloid pathology? *Biochemical Society Transactions*, *33*(Pt 5), 1041–4. doi:10.1042/BST20051041
- Boyle, J. P., Thompson, T. J., Gregg, E. W., Barker, L. E., & Williamson, D. F. (2010). Projection of the year 2050 burden of diabetes in the US adult population: dynamic modeling of incidence, mortality, and prediabetes prevalence. *Population Health Metrics*, *8*, 29. doi:10.1186/1478-7954-8-29
- Brown, M. M., Brown, G. C., Sharma, S., & Busbee, B. (2003). Quality of life associated with visual loss: A time tradeoff utility analysis comparison with medical health states. *Ophthalmology*, *110*, 1076–1081. doi:10.1016/S0161-6420(03)00254-9
- Brown, M. M., Brown, G. C., Sharma, S., Landy, J., & Bakal, J. (2002). Quality of life with visual acuity loss from diabetic retinopathy and age-related macular degeneration. *Archives of Ophthalmology*, *120*, 481–484.
- Butterfield, D. A., Di Domenico, F., & Barone, E. (2014). Elevated risk of type 2 diabetes for development of Alzheimer disease: a key role for oxidative stress in brain. *Biochimica et Biophysica Acta*, *1842*(9), 1693–706. doi:10.1016/j.bbadis.2014.06.010

- 
- Chen, C.-S., Tsai, J.-C., Tsang, H., Kuo, Y., Lin, H., Chiang, I., & Devanand, D. P. (2005). Homocysteine levels, MTHFR C677T genotype, and MRI Hyperintensities in late-onset major depressive disorder. *The American Journal of Geriatric Psychiatry*: Official Journal of the American Association for Geriatric Psychiatry, 13(10), 869–75. doi:10.1176/appi.ajgp.13.10.869
- Clarke, P. M., Simon, J., Cull, C. A., & Holman, R. R. (2006). Assessing the impact of visual acuity on quality of life in individuals with type 2 diabetes using the short form-36. *Diabetes Care*, 29, 1506–1511. doi:10.2337/dc05-2150
- De Bree, A., Verschuren, W. M. M., Kromhout, D., Kluijtmans, L. A. J., & Blom, H. J. (2002). Homocysteine determinants and the evidence to what extent homocysteine determines the risk of coronary heart disease. *Pharmacological Reviews*, 54, 599–618. doi:10.1124/pr.54.4.599
- De la Monte, S. M., & Wands, J. R. (2008). Alzheimer's Disease is Type 3 Diabetes--Evidence Reviewed. *Journal of Diabetes Science and Technology*, 2(6), 1101–1113. doi:10.1177/193229680800200619
- De la Torre, J. C. (2004). Is Alzheimer's disease a neurodegenerative or a vascular disorder? Data, dogma, and dialectics. *The Lancet. Neurology*, 3(3), 184–90. doi:10.1016/S1474-4422(04)00683-0
- Decanini, a, Karunadharm, P. R., Nordgaard, C. L., Feng, X., Olsen, T. W., & Ferrington, D. a. (2008). Human retinal pigment epithelium proteome changes in early diabetes. *Diabetologia*, 51(6), 1051–61. doi:10.1007/s00125-008-0991-2
- Dehabadi, M. H., Davis, B. M., Wong, T. K., & Cordeiro, M. F. (2014). Retinal manifestations of Alzheimer's disease. *Neurodegenerative Disease Management*, 4(3), 241–52. doi:10.2217/nmt.14.19
- Fenwick, E. K., Pesudovs, K., Rees, G., Dirani, M., Kawasaki, R., Wong, T. Y., & Lamoureux, E. L. (2011). The impact of diabetic retinopathy: understanding the patient's perspective. *The British Journal of Ophthalmology*, 95, 774–782. doi:10.1136/pgmj.2010.191312rep
- Ferri, C. P., Prince, M., Brayne, C., Brodaty, H., Fratiglioni, L., Ganguli, M., ... Sczufca, M. (2005). Global prevalence of dementia: a Delphi

---

consensus study. *Lancet*, 366(9503), 2112–7. doi:10.1016/S0140-6736(05)67889-0

- Fowler, B. (2005). Homocysteine: Overview of biochemistry, molecular biology, and role in disease processes. *Seminars in Vascular Medicine*. doi:10.1055/s-2005-872394
- Goto, Y., Kakizaki, M., & Masaki, N. (1976). Production of spontaneous diabetic rats by repetition of selective breeding. *The Tohoku Journal of Experimental Medicine*, 119(1), 85–90.
- Harris, M. I., Cowie, C. C., & Howie, L. J. (1993). Self-monitoring of blood glucose by adults with diabetes in the United States population. *Diabetes Care*, 16, 1116–1123. doi:10.2337/diacare.16.8.1116
- Herrmann, W., & Obeid, R. (2011). Homocysteine: A biomarker in neurodegenerative diseases. *Clinical Chemistry and Laboratory Medicine*. doi:10.1515/CCLM.2011.084
- Ho, P. I., Ashline, D., Dhitavat, S., Ortiz, D., Collins, S. C., Shea, T. B., & Rogers, E. (2003). Folate deprivation induces neurodegeneration: Roles of oxidative stress and increased homocysteine. *Neurobiology of Disease*, 14, 32–42. doi:10.1016/S0969-9961(03)00070-6
- Hoogeveen, E. K., Kostense, P. J., Jakobs, C., Dekker, J. M., Nijpels, G., Heine, R. J., ... Stehouwer, C. D. (2000). Hyperhomocysteinemia increases risk of death, especially in type 2 diabetes: 5-year follow-up of the Hoorn Study. *Circulation*, 101(13), 1506–11. Retrieved from <http://www.ncbi.nlm.nih.gov/pubmed/10747342>
- Howlett, D. R., Richardson, J. C., Austin, A., Parsons, A. a, Bate, S. T., Davies, D. C., & Gonzalez, M. I. (2004). Cognitive correlates of A $\beta$  deposition in male and female mice bearing amyloid precursor protein and presenilin-1 mutant transgenes. *Brain Research*, 1017(1-2), 130–6. doi:10.1016/j.brainres.2004.05.029
- Hu, Z.-P., Browne, E. R., Liu, T., Angel, T. E., Ho, P. C., & Chan, E. C. Y. (2012). Metabonomic profiling of TASTPM transgenic Alzheimer's disease mouse model. *Journal of Proteome Research*, 11(12), 5903–13. doi:10.1021/pr300666p

- 
- Kamath, A. F., Chauhan, A. K., Kisucka, J., Dole, V. S., Loscalzo, J., Handy, D. E., & Wagner, D. D. (2006). Elevated levels of homocysteine compromise blood-brain barrier integrity in mice. *Blood*, *107*, 591–593. doi:10.1182/blood-2005-06-2506
- Kern, T. S., & Barber, A. J. (2008). Retinal ganglion cells in diabetes. *The Journal of Physiology*, *586*(Pt 18), 4401–8. doi:10.1113/jphysiol.2008.156695
- Khodadadi, S., Riazi, G. H., Ahmadian, S., Hoveizi, E., Karima, O., & Aryapour, H. (2012). Effect of N-homocysteinylolation on physicochemical and cytotoxic properties of amyloid  $\beta$ -peptide. *FEBS Letters*, *586*(2), 127–31. doi:10.1016/j.febslet.2011.12.018
- Klein, R., Palta, M., Allen, C., Shen, G., Han, D. P., & D'Alessio, D. J. (1997). Incidence of retinopathy and associated risk factors from time of diagnosis of insulin-dependent diabetes. *Archives of Ophthalmology*, *115*, 351–356. doi:10.1001/archophth.1997.01100150353007
- Krady, J. K., Basu, A., Allen, C. M., Xu, Y., LaNoue, K. F., Gardner, T. W., & Levison, S. W. (2005). Minocycline reduces proinflammatory cytokine expression, microglial activation, and caspase-3 activation in a rodent model of diabetic retinopathy. *Diabetes*, *54*(5), 1559–65. Retrieved from <http://www.ncbi.nlm.nih.gov/pubmed/15855346>
- Kruman, I. I., Culmsee, C., Chan, S. L., Kruman, Y., Guo, Z., Penix, L., & Mattson, M. P. (2000). Homocysteine Elicits a DNA Damage Response in Neurons That Promotes Apoptosis and Hypersensitivity to Excitotoxicity, *20*(18), 6920–6926. doi:20(18):6920–6926
- Kruman, I. I., Culmsee, C., Chan, S. L., Kruman, Y., Guo, Z., Penix, L., & Mattson, M. P. (2000). Homocysteine elicits a DNA damage response in neurons that promotes apoptosis and hypersensitivity to excitotoxicity. *The Journal of Neuroscience* □: *The Official Journal of the Society for Neuroscience*, *20*(18), 6920–6926.
- Lee, H., Kim, H. J., Kim, J. M., & Chang, N. (2004). Effects of dietary folic acid supplementation on cerebrovascular endothelial dysfunction in rats with induced hyperhomocysteinemia. *Brain Res*, *996*, 139–147. Retrieved from [http://www.ncbi.nlm.nih.gov/entrez/query.fcgi?cmd=Retrieve&db=PubMed&dopt=Citation&list\\_uids=14697491](http://www.ncbi.nlm.nih.gov/entrez/query.fcgi?cmd=Retrieve&db=PubMed&dopt=Citation&list_uids=14697491)
-

- 
- Lim, C. P., Loo, A. V. P., Khaw, K. W., Sthaneshwar, P., Khang, T. F., Hassan, M., & Subrayan, V. (2012). Plasma, aqueous and vitreous homocysteine levels in proliferative diabetic retinopathy. *The British Journal of Ophthalmology*, *96*(5), 704–7. doi:10.1136/bjophthalmol-2011-301044
- London, A., Benhar, I., & Schwartz, M. (2013). The retina as a window to the brain—from eye research to CNS disorders. *Nature Reviews. Neurology*, *9*(1), 44–53. doi:10.1038/nrneuro.2012.227
- Malaguarnera, G., Gagliano, C., Giordano, M., Salomone, S., Vacante, M., Bucolo, C., ... Motta, M. (2014). Homocysteine Serum Levels in Diabetic Patients with Non Proliferative, Proliferative and without Retinopathy. *BioMed Research International*, *2014*, 191497. doi:10.1155/2014/191497
- Mangoni, A. A., & Jackson, S. H. D. (2002). Homocysteine and cardiovascular disease: current evidence and future prospects. *The American Journal of Medicine*, *112*, 556–565.
- Mayer, E. L., Jacobsen, D. W., & Robinson, K. (1996). Homocysteine and coronary atherosclerosis. *Journal of the American College of Cardiology*. doi:10.1016/0735-1097(95)00508-0
- McCully, K. S. (2009). Chemical pathology of homocysteine. IV. Excitotoxicity, oxidative stress, endothelial dysfunction, and inflammation. *Annals of Clinical and Laboratory Science*. doi:39/3/219 [pii]
- Mizutani, M., Kern, T. S., & Lorenzi, M. (1996). Accelerated death of retinal microvascular cells in human and experimental diabetic retinopathy. *The Journal of Clinical Investigation*, *97*(12), 2883–90. doi:10.1172/JCI118746
- Moreira, P. I., Santos, M. S., Seça, R., & Oliveira, C. R. (2007). Brain mitochondrial dysfunction as a link between Alzheimer's disease and diabetes. *Journal of the Neurological Sciences*, *257*(1-2), 206–14. doi:10.1016/j.jns.2007.01.017
- Morris, M. S. (2003). Rapid review Homocysteine and Alzheimer ' s disease Rapid review, *2*(July), 425–428.



- 
- Morrison, H. I., Schaubel, D., Desmeules, M., & Wigle, D. T. (1996). Serum folate and risk of fatal coronary heart disease. *JAMA*, *275*, 1893–1896. Retrieved from [http://www.ncbi.nlm.nih.gov/entrez/query.fcgi?cmd=Retrieve&db=PubMed&dopt=Citation&list\\_uids=8648869](http://www.ncbi.nlm.nih.gov/entrez/query.fcgi?cmd=Retrieve&db=PubMed&dopt=Citation&list_uids=8648869)
- Nilsson, K., Gustafson, L., & Hultberg, B. (2002). Relation between plasma homocysteine and Alzheimer's disease. *Dementia and Geriatric Cognitive Disorders*, *14*(1), 7–12. doi:58327
- Obeid, R., & Herrmann, W. (2006). Mechanisms of homocysteine neurotoxicity in neurodegenerative diseases with special reference to dementia. *FEBS Letters*, *580*(13), 2994–3005. doi:10.1016/j.febslet.2006.04.088
- Ola, M. S., Nawaz, M. I., Khan, H. a, & Alhomida, A. S. (2013). Neurodegeneration and neuroprotection in diabetic retinopathy. *International Journal of Molecular Sciences*, *14*(2), 2559–72. doi:10.3390/ijms14022559
- Pacheco-Quinto, J., Rodriguez de Turco, E. B., DeRosa, S., Howard, A., Cruz-Sanchez, F., Sambamurti, K., ... Pappolla, M. A. (2006). Hyperhomocysteinemic Alzheimer's mouse model of amyloidosis shows increased brain amyloid  $\beta$  peptide levels. *Neurobiology of Disease*, *22*, 651–656. doi:10.1016/j.nbd.2006.01.005
- PANCHARUNITI, N., LEWIS, C. A., SAUBERLICH, H. E., PERKINS, L. L., GO, R. C. P., ALVAREZ, J. O., ... ROSEMAN, J. M. (1994). PLASMA HOMOCYST(E)INE, FOLATE, AND VITAMIN-B12 CONCENTRATIONS AND RISK FOR EARLY-ONSET CORONARY-ARTERY DISEASE. *AMERICAN JOURNAL OF CLINICAL NUTRITION*, *59*, 940–948.
- Portha, B. (2005). Programmed disorders of beta-cell development and function as one cause for type 2 diabetes? The GK rat paradigm. *Diabetes/metabolism Research and Reviews*, *21*(6), 495–504. doi:10.1002/dmrr.566
- Ramakrishnan, S., Sulochana, K. N., Lakshmi, S., Selvi, R., & Angayarkanni, N. (2006). Biochemistry of homocysteine in health and diseases. *Indian Journal of Biochemistry & Biophysics*, *43*(5), 275–283.

- 
- Reif, A., Pfulmann, B., & Lesch, K.-P. (2005). Homocysteinemia as well as methylenetetrahydrofolate reductase polymorphism are associated with affective psychoses. *Progress in Neuro-Psychopharmacology & Biological Psychiatry*, *29*(7), 1162–8. doi:10.1016/j.pnpbp.2005.06.027
- Rein, D. B., Zhang, P., Wirth, K. E., Lee, P. P., Hoerger, T. J., McCall, N., ... Saaddine, J. (2006). The economic burden of major adult visual disorders in the United States. *Archives of Ophthalmology*, *124*, 1754–1760. doi:10.1001/archophth.124.12.1754
- Reitz, C., & Mayeux, R. (2014). Alzheimer disease: epidemiology, diagnostic criteria, risk factors and biomarkers. *Biochemical Pharmacology*, *88*(4), 640–51. doi:10.1016/j.bcp.2013.12.024
- Risacher, S. L., WuDunn, D., Pepin, S. M., MaGee, T. R., McDonald, B. C., Flashman, L. A., ... Saykin, A. J. (2013). Visual contrast sensitivity in Alzheimer's disease, mild cognitive impairment, and older adults with cognitive complaints. *Neurobiology of Aging*, *34*, 1133–1144. doi:10.1016/j.neurobiolaging.2012.08.007
- Rizzo, M., Anderson, S. W., Dawson, J., & Nawrot, M. (2000). Vision and cognition in Alzheimer's disease. *Neuropsychologia*, *38*(8), 1157–69. Retrieved from <http://www.ncbi.nlm.nih.gov/pubmed/10838150>
- Robinson, K., Mayer, E. L., Miller, D. P., Green, R., van Lente, F., Gupta, A., ... Nissen, S. E. (1995). Hyperhomocysteinemia and low pyridoxal phosphate. Common and independent reversible risk factors for coronary artery disease. *Circulation*, *92*, 2825–2830. doi:10.1161/01.CIR.92.10.2825
- ROTH, M. (1955). The natural history of mental disorder in old age. *The Journal of Mental Science*, *101*, 281–301.
- Salomone, S., Caraci, F., Leggio, G. M., Fedotova, J., & Drago, F. (2012). New pharmacological strategies for treatment of Alzheimer's disease: focus on disease modifying drugs. *British Journal of Clinical Pharmacology*, *73*(4), 504–17. doi:10.1111/j.1365-2125.2011.04134.x
- Schalinske, K. L., & Smazal, A. L. (2012). Homocysteine imbalance: a pathological metabolic marker. *Advances in Nutrition (Bethesda, Md.)*, *3*(6), 755–62. doi:10.3945/an.112.002758

- 
- Simó, R., & Hernández, C. (2012). Neurodegeneration is an early event in diabetic retinopathy: therapeutic implications. *The British Journal of Ophthalmology*, *96*(10), 1285–90. doi:10.1136/bjophthalmol-2012-302005
- Spijkerman, A. M. W., Dekker, J. M., Nijpels, G., Adriaanse, M. C., Kostense, P. J., Ruwaard, D., ... Heine, R. J. (2003). Microvascular complications at time of diagnosis of type 2 diabetes are similar among diabetic patients detected by targeted screening and patients newly diagnosed in general practice: the hoorn screening study. *Diabetes Care*, *26*(9), 2604–8. doi:10.2337/diacare.26.9.2604
- Stamler, J., Vaccaro, O., Neaton, J. D., & Wentworth, D. (1993). Diabetes, other risk factors, and 12-yr cardiovascular mortality for men screened in the multiple risk factor intervention trial. *Diabetes Care*, *16*, 434–444.
- Steen, E., Terry, B. M., Rivera, E. J., Cannon, J. L., Neely, T. R., Tavares, R., ... de la Monte, S. M. (2005). Impaired insulin and insulin-like growth factor expression and signaling mechanisms in Alzheimer's disease--is this type 3 diabetes? *Journal of Alzheimer's Disease*: *JAD*, *7*(1), 63–80. Retrieved from <http://www.ncbi.nlm.nih.gov/pubmed/15750215>
- Thambisetty, M., & Lovestone, S. (2010). Blood-based biomarkers of Alzheimer's disease: challenging but feasible. *Biomarkers in Medicine*, *4*, 65–79. doi:10.2217/bmm.09.84
- Ubbink, J. B. (1995). Homocysteine--an atherogenic and a thrombogenic factor? *Nutrition Reviews*, *53*, 323–325.
- Welch, G. N., & Loscalzo, J. (1998). Homocysteine and atherothrombosis. *The New England Journal of Medicine*, *338*(15), 1042–50. doi:10.1056/NEJM199804093381507
- Wild, S., Roglic, G., Green, A., Sicree, R., & King, H. (2004). Global Prevalence of Diabetes: Estimates for the year 2000 and projections for 2030. *Diabetes Care*, *27*, 1047–1053. doi:10.2337/diacare.27.5.1047
- Wright, a D., Martin, N., & Dodson, P. M. (2008). Homocysteine, folates, and the eye. *Eye (London, England)*, *22*(8), 989–93. doi:10.1038/sj.eye.6703061

---

Yang, Y., & Song, W. (2013). Molecular links between Alzheimer's disease and diabetes mellitus. *Neuroscience*, *250*, 140–50. doi:10.1016/j.neuroscience.2013.07.009

Zavrelova, H., Hoekstra, T., Alsema, M., Welschen, L. M. C., Nijpels, G., Moll, A. C., ... Dekker, J. M. (2011). Progression and regression: Distinct developmental patterns of diabetic retinopathy in patients with type 2 diabetes treated in the Diabetes Care System West-Friesland, the Netherlands. *Diabetes Care*, *34*, 867–872. doi:10.2337/dc10-1741

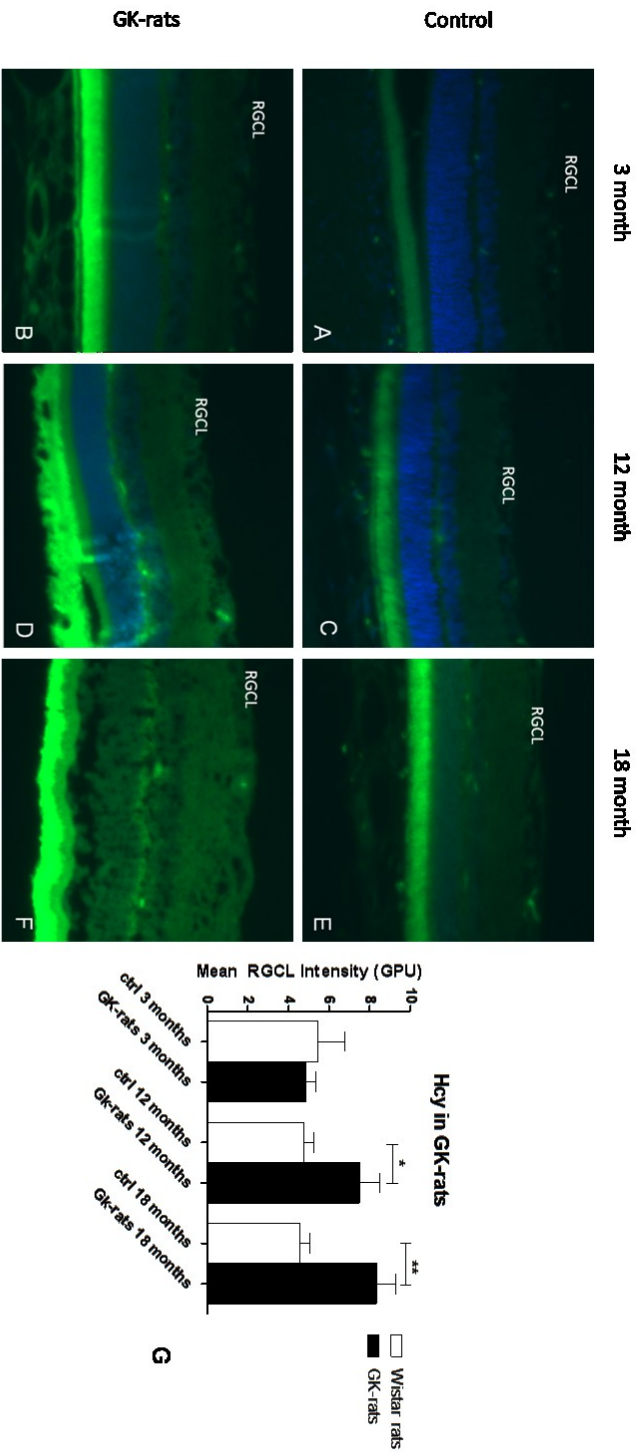
Zhang, C.-E., Wei, W., Liu, Y.-H., Peng, J.-H., Tian, Q., Liu, G.-P., ... Wang, J.-Z. (2009). Hyperhomocysteinemia increases beta-amyloid by enhancing expression of gamma-secretase and phosphorylation of amyloid precursor protein in rat brain. *The American Journal of Pathology*, *174*, 1481–1491. doi:10.2353/ajpath.2009.081036

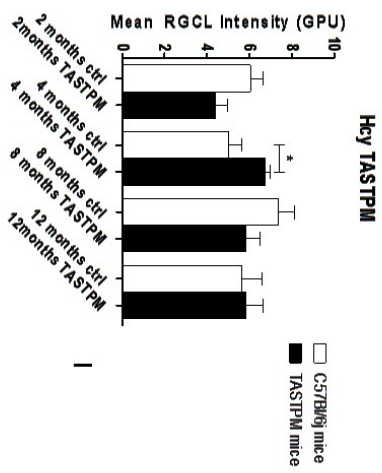
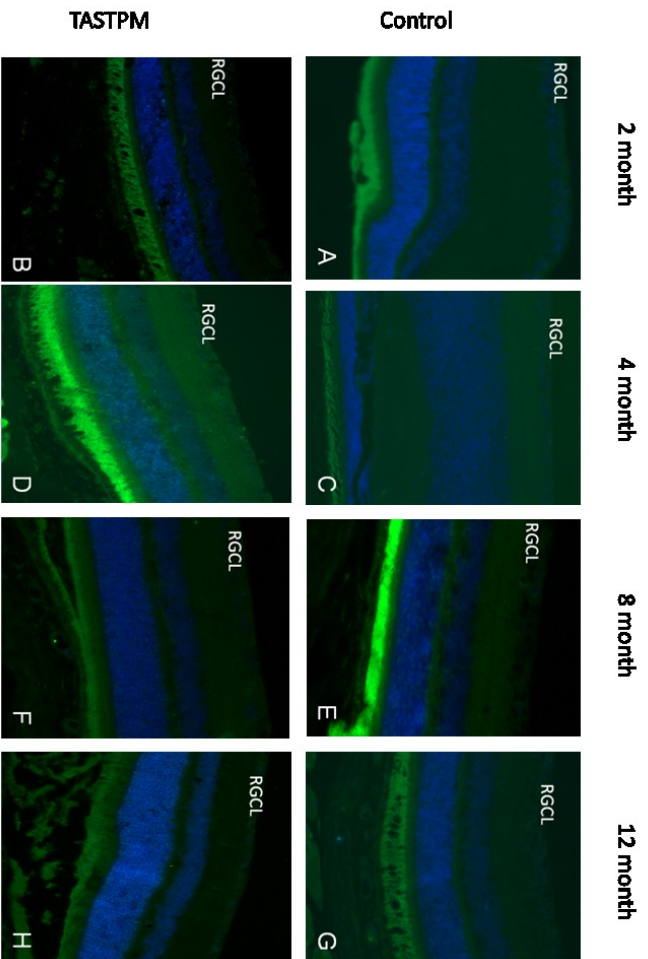
Zhuo, J. M., Wang, H., & Praticò, D. (2011). Is hyperhomocysteinemia an Alzheimer's disease (AD) risk factor, an AD marker, or neither? *Trends in Pharmacological Sciences*. doi:10.1016/j.tips.2011.05.003

---

Table 1. Primary Antibodies:

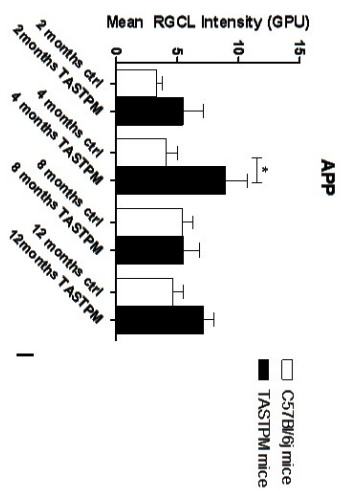
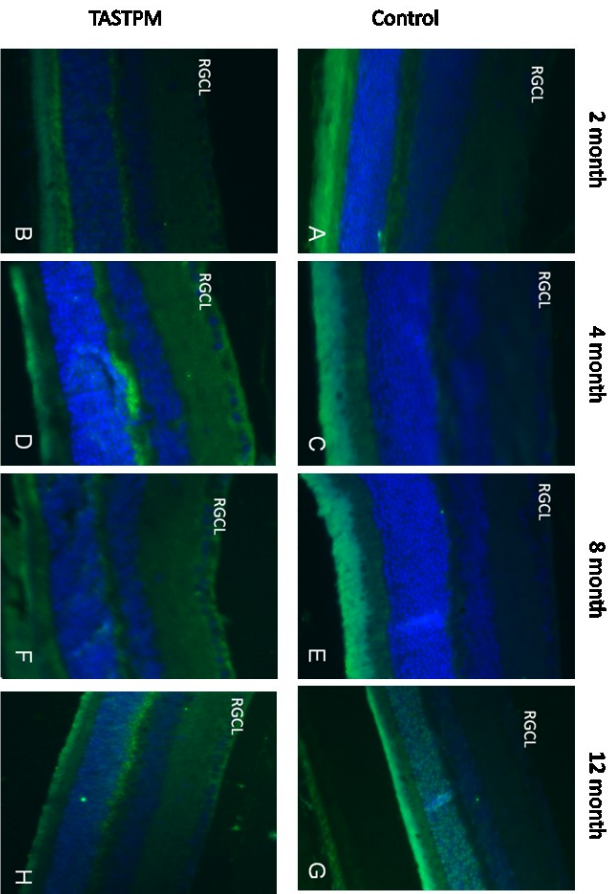
Antibody:	Company	Host	Dilution for IHC-P
Homocysteine	Abcam	Rabbit	1:400
Abeta	Abcam	Rabbit	1:750
APP	Abcam	Goat	1:1000
Caspase 3	Cell signalling	Rabbit	1:100
Cox1	Life technologies	Mouse	1:100





**Figure 2. Homocysteine (Hcy) staining in RGCL Layer of TASTPM mice.**

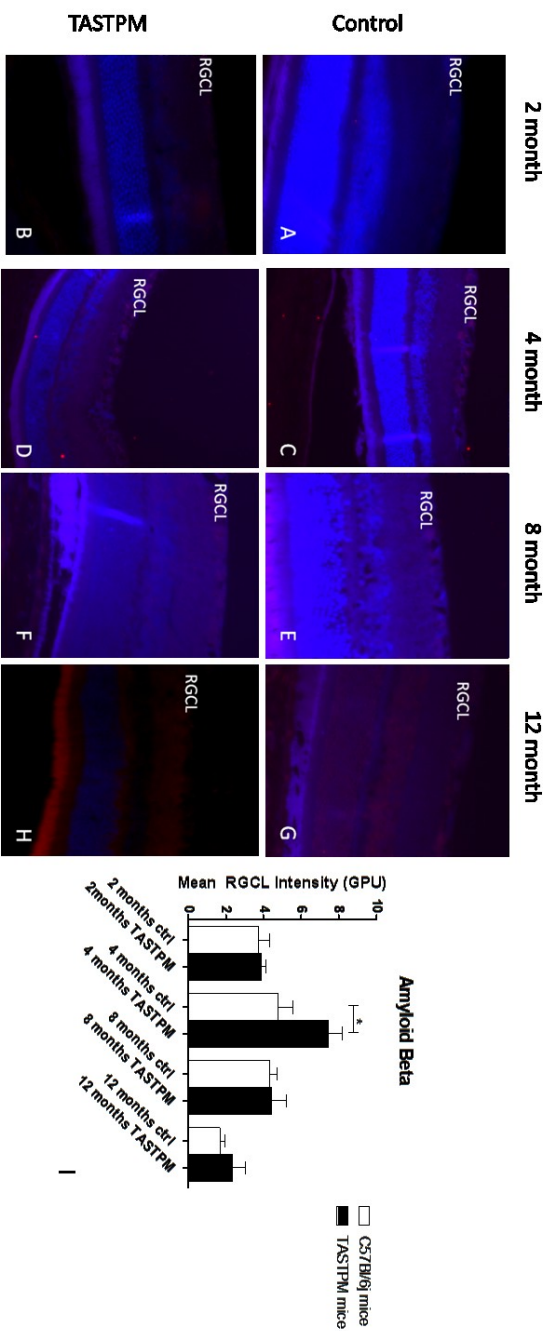
**A-H** Pannel of retinae stained with hcy-antibody 10x magnification. **A.** 2 month control, **B.** 2 month TASTPM, **C.** 4 month control, **D.** 4 month TASTPM, **E.** 8 month control, **F.** 8 month TASTPM, **G.** 12 month control, **H.** 12 month TASTPM. **I.** Mean intensity. The mean intensity of homocysteine were significantly increased at 4 months ( $p < 0.05^*$ ) compared to the age-matched control, whereas no significant data were found at 2, 8 and 12 months. Data are means  $\pm$  SEM.

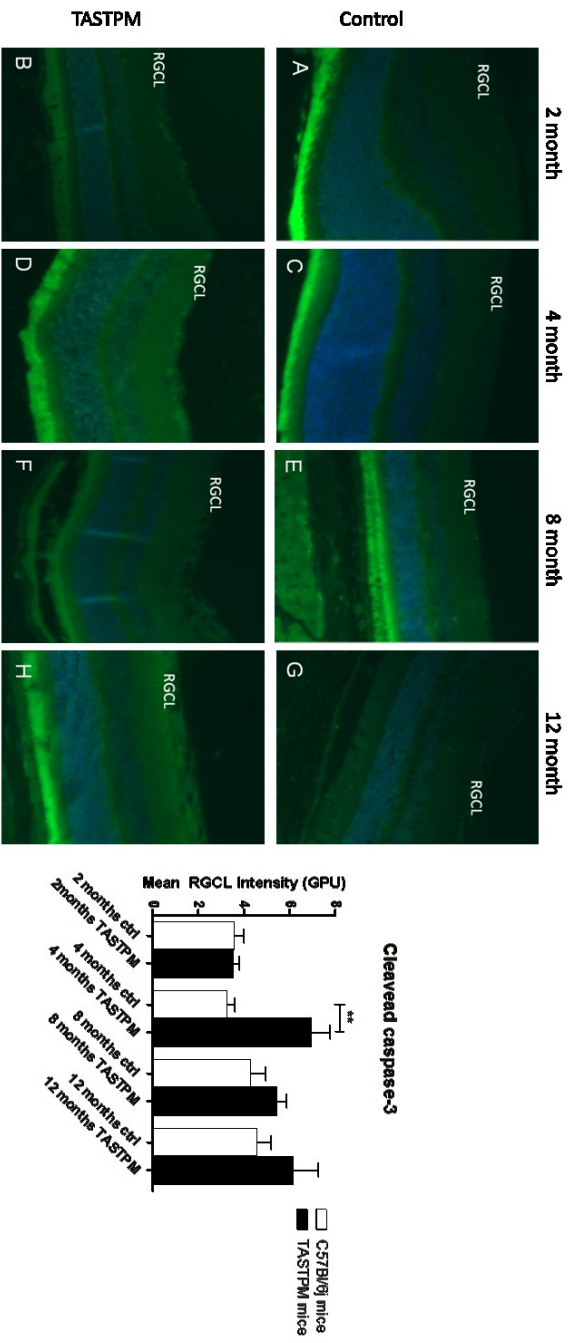


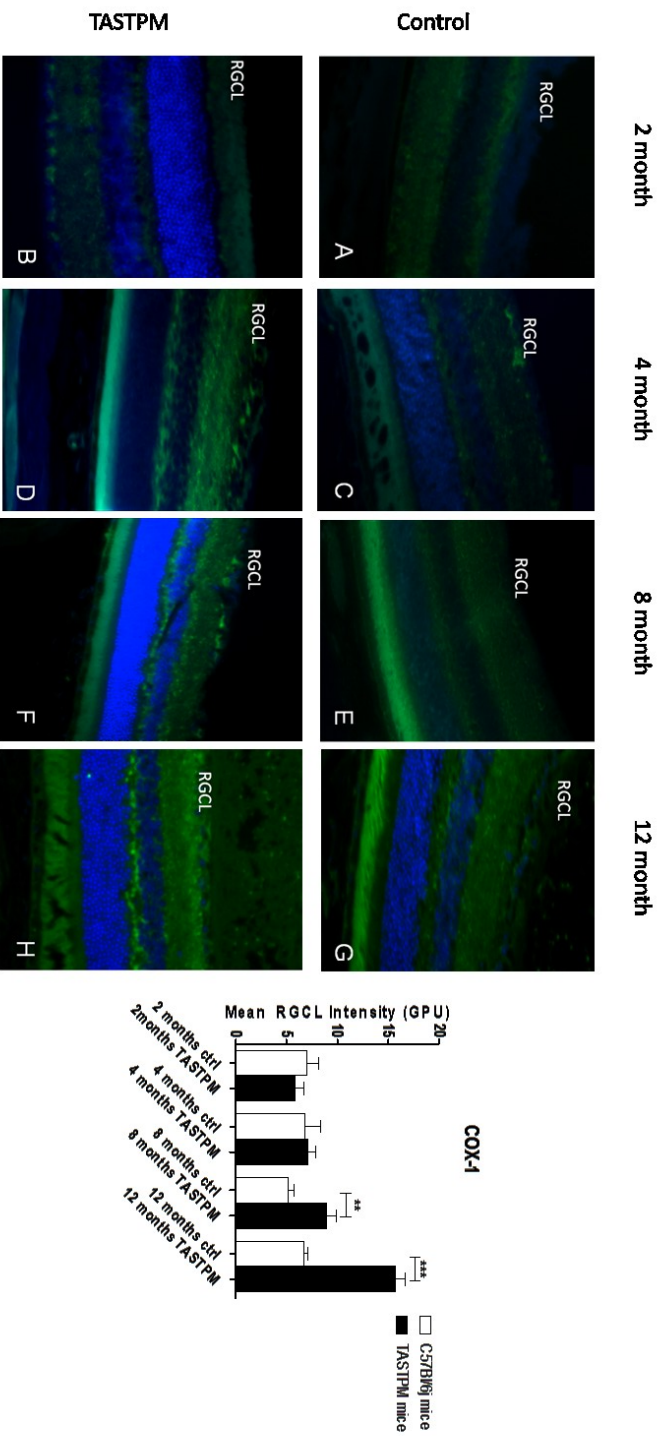
**Figure 3. APP staining in RGC Layer of TASTPM mice.**

**A-H** Pannel of retinae stained with APP-antibody 20x magnification. **A.** 2 month control, **B.** 2 month TASTPM, **C.** 4 month control, **D.** 4 month TASTPM, **E.** 8 month control, **F.** 8 month TASTPM, **G.** 12 month control, **H.** 12 month TASTPM. **I.** Mean intensity. Increased APP fluorescence was found in the 4-month TASTPM retinae as compared to age-matched controls ( $p > 0.05^*$ ). In contrast, similar APP fluorescence levels were found on 2 month, 8 month TASTPM and control retina. Data are means  $\pm$  SEM









---

## 2. General Discussion and Conclusions

In the first study presented, elevated blood homocysteine concentration has been documented as an independent risk factor for DR (Malaguarnera et al., 2014). In particular we found that its level increase with the worsening of the retinopathy: from diabetes without retinopathy to non-proliferative and proliferative diabetic retinopathy.

The exact mechanism by which elevated plasma homocysteine increases vascular disease is still unclear. It has been proposed that homocysteine may have a direct effect on vessel walls by promoting vascular smooth muscle cell proliferation (De Bree, Verschuren, Kromhout, Kluijtmans, & Blom, 2002; Mangoni & Jackson, 2002). Other proposed mechanisms suggest that homocysteine may increase platelet adhesion, interfere with clotting, or enhance oxidation of LDL cholesterol (Mayer, Jacobsen, & Robinson, 1996; Ubbink, 1995).

A strong inverse relationship exist between homocysteine concentrations and blood measures of folate, vitamin B12 and vitamin B6 (Bates, 1991; Morrison, Schaubel, Desmeules, & Wigle, 1996; PANCHARUNITI et al., 1994; Robinson et al., 1995). Homocysteine is remethylated to form methionine in a reaction that requires folate and vitamin B12 or homocysteine may be metabolized to cysteine in a reaction that necessitate

---

B6 (Fowler, 2005). Thus, in the second study we measured the levels of folate in the blood, investigating whether the deficiency were present and correlated with the worsening of the eye pathology as well as homocysteine. We found that in diabetic retinopathy plasma homocysteine was significantly higher and both folate and vitamin B6 status significantly lower in participants with type 2 diabetes.

Therefore, high concentrations of plasma total homocysteine may be an indications of poor status of the B vitamins, especially vitamin B6. Elevated plasma total homocysteine concentrations and lower level of both vitamin B6 and folate may contribute to an increased risk incidence of DR.

DR has a negative impact on quality of life, particularly in the advanced stages. At similar levels of visual acuity loss, the impact on quality of life related to DR was shown to be comparable to that related to AMD (aged-related macular degeneration), which has implications for cost utility analyses of ophthalmic interventions (Brown, Brown, Sharma, & Busbee, 2003; Brown, Brown, Sharma, Landy, & Bakal, 2002; Clarke, Simon, Cull, & Holman, 2006; Fenwick et al., 2011).

Multiple modifiable risk factors for late complications in patients with type 2 diabetes, including hyperglycemia, hypertension and dyslipidemia, increase the risk of a poor outcome (Stamler, Vaccaro, Neaton, & Wentworth, 1993).

---

Randomized trials that investigated the effect of intensified intervention involving a single risk factor in patients with type 2 diabetes demonstrated benefits in terms of both macrovascular and microvascular complications in kidneys, eyes and nerves.

The high levels of homocysteine and the low levels of both folate status and vitamin B6 levels are strongly related. Infact, in the biochemical process folic acid gives a methylic group to homocysteine in order to be converted in methionine, whereas vitamin B6 is a co-enzyme in the transulphuration pathway leading to the production of cysteine. Hyperhomocysteinemia increases the impaired cells proliferation, DNA damage, and in retina of diabetic patients contribute to develop non proliferative and proliferative retinopathy.

The neurodegeneration that occurs in the retinopathy reinforces the vascular damage and vice versa. Therefore, in the last study presented in this thesis we investigated whether could be the role of Homocysteine in neurodegeneration.

Several neurodegenerative conditions that affect the brain have manifestations in the eye, and ocular symptoms often precede conventional diagnosis of such CNS disorders. Epidemiological studies have linked type 2 diabetes mellitus (T2DM) with an increased risk of Alzheimer's Disease

---

(AD). Histopathological, molecular, and biochemical abnormalities have commonalities in both these major disease, which has lead to AD recently termed as "Type 3 Diabetes".

High levels of Homocysteine (Hcy) in the plasma has been associated with both AD and T2DM. The aim was to investigate whether retinal Hcy is associated with retinal neurodegeneration in animal models of AD (TASTPM transgenic mice) and T2DM (Goto-Kakizaki (GK) rats).

As far as we are aware, this has been the first study that shows a role of homocysteine in retinal neurodegeneration in GK-rats and TASTPM mice. Hcy is increased with aging and the worsening of the diabetes in GK-rats, and in both models appears to be linked with Retinal Ganglion Cells apoptosis and A $\beta$  expression. This highlights the association of T2DM with AD. High levels of homocysteine or deficiencies in folate and vitamins B6 and B12 or to genetic deficiency in Cystathionine- $\beta$ -synthase (Cbs +/-), have been associated with damage to the blood brain barrier (Kamath et al., 2006). This in itself may lead to neurodegeneration. However, there is further evidence that elevated hcy can increase production of mitochondrial ROS (reactive oxygen species) (I I Kruman et al., 2000), although whether this is associated with Amyloid beta is not well-know. We hypothesize that elevated levels of homocysteine cause the cleave of APP (Zhang et al., 2009) and the formation of oligomers of A $\beta$ , which are also stabilized by the homocysteine

---

thiolactone (a metabolite of homocysteine formed when its levels are enhanced)(Khodadadi et al., 2012). The association with both of them is responsible of oxidative stress, apoptosis, excitotoxicity and inflammation. Further studies are required to better understand the complexity of this mosaic, in which homocysteine represent an important tessera.



---

### 3. References

- Abdul-Rahman, O., Sasvari-Szekely, M., Ver, A., Rosta, K., Szasz, B. K., Kereszturi, E., & Keszler, G. (2012). Altered gene expression profiles in the hippocampus and prefrontal cortex of type 2 diabetic rats. *BMC Genomics*, *13*(1), 81. doi:10.1186/1471-2164-13-81
- Abu El-Asrar, a M., Dralands, L., Missotten, L., & Geboes, K. (2007). Expression of antiapoptotic and proapoptotic molecules in diabetic retinas. *Eye (London, England)*, *21*(2), 238–45. doi:10.1038/sj.eye.6702225
- Adunsky, A., Arinzon, Z., Fidelman, Z., Krasniansky, I., Arad, M., & Gepstein, R. (2005). Plasma homocysteine levels and cognitive status in long-term stay geriatric patients: a cross-sectional study. *Archives of Gerontology and Geriatrics*, *40*(2), 129–38. doi:10.1016/j.archger.2004.07.001
- Ahsan, H. (2014). Diabetic retinopathy - Biomolecules and multiple pathophysiology. *Diabetes & Metabolic Syndrome*, 10–13. doi:10.1016/j.dsx.2014.09.011
- Atmaca, M., Tezcan, E., Kuloglu, M., Kirtas, O., & Ustundag, B. (2005). Serum folate and homocysteine levels in patients with obsessive-compulsive disorder. *Psychiatry and Clinical Neurosciences*, *59*(5), 616–20. doi:10.1111/j.1440-1819.2005.01425.x
- Ballard, C., Gauthier, S., Corbett, A., Brayne, C., Aarsland, D., & Jones, E. (2011). Alzheimer's disease. *Lancet*, *377*, 1019–1031. doi:10.1016/S0140-6736(10)61349-9
- Barber, a J., Lieth, E., Khin, S. a, Antonetti, D. a, Buchanan, a G., & Gardner, T. W. (1998). Neural apoptosis in the retina during experimental and human diabetes. Early onset and effect of insulin. *The Journal of Clinical Investigation*, *102*(4), 783–91. doi:10.1172/JCI2425
- Bates, C. J. (1991). Glutathione and related indices in rat lenses, liver and red cells during riboflavin deficiency and its correction. *Experimental Eye Research*, *53*, 123–130. doi:10.1016/0014-4835(91)90154-7
- Bek, T., Lund-Andersen, H., Hansen, A. B., Johnsen, K. B., Sandbæk, A., & Lauritzen, T. (2009). The prevalence of diabetic retinopathy in patients with screen-detected type 2 diabetes in Denmark: The ADDITION study. *Acta Ophthalmologica*, *87*, 270–274. doi:10.1111/j.1755-3768.2008.01207.x

- 
- Beulens, J. W. J., Patel, A., Vingerling, J. R., Cruickshank, J. K., Hughes, A. D., Stanton, A., ... Stolk, R. P. (2009). Effects of blood pressure lowering and intensive glucose control on the incidence and progression of retinopathy in patients with type 2 diabetes mellitus: A randomised controlled trial. *Diabetologia*, *52*, 2027–2036. doi:10.1007/s00125-009-1457-x
- Biessels, G. J., & Kappelle, L. J. (2005). Increased risk of Alzheimer's disease in Type II diabetes: insulin resistance of the brain or insulin-induced amyloid pathology? *Biochemical Society Transactions*, *33*(Pt 5), 1041–4. doi:10.1042/BST20051041
- Boyle, J. P., Thompson, T. J., Gregg, E. W., Barker, L. E., & Williamson, D. F. (2010). Projection of the year 2050 burden of diabetes in the US adult population: dynamic modeling of incidence, mortality, and prediabetes prevalence. *Population Health Metrics*, *8*, 29. doi:10.1186/1478-7954-8-29
- Brown, M. M., Brown, G. C., Sharma, S., & Busbee, B. (2003). Quality of life associated with visual loss: A time tradeoff utility analysis comparison with medical health states. *Ophthalmology*, *110*, 1076–1081. doi:10.1016/S0161-6420(03)00254-9
- Brown, M. M., Brown, G. C., Sharma, S., Landy, J., & Bakal, J. (2002). Quality of life with visual acuity loss from diabetic retinopathy and age-related macular degeneration. *Archives of Ophthalmology*, *120*, 481–484.
- Butterfield, D. A., Di Domenico, F., & Barone, E. (2014). Elevated risk of type 2 diabetes for development of Alzheimer disease: a key role for oxidative stress in brain. *Biochimica et Biophysica Acta*, *1842*(9), 1693–706. doi:10.1016/j.bbadis.2014.06.010
- Chen, C.-S., Tsai, J.-C., Tsang, H., Kuo, Y., Lin, H., Chiang, I., & Devanand, D. P. (2005). Homocysteine levels, MTHFR C677T genotype, and MRI Hyperintensities in late-onset major depressive disorder. *The American Journal of Geriatric Psychiatry*: Official Journal of the American Association for Geriatric Psychiatry, *13*(10), 869–75. doi:10.1176/appi.ajgp.13.10.869
- Clarke, P. M., Simon, J., Cull, C. A., & Holman, R. R. (2006). Assessing the impact of visual acuity on quality of life in individuals with type 2 diabetes using the short form-36. *Diabetes Care*, *29*, 1506–1511. doi:10.2337/dc05-2150
- De Bree, A., Verschuren, W. M. M., Kromhout, D., Kluijtmans, L. A. J., & Blom, H. J. (2002). Homocysteine determinants and the evidence to what extent homocysteine determines the risk of coronary heart disease. *Pharmacological Reviews*, *54*, 599–618. doi:10.1124/pr.54.4.599

- 
- De la Monte, S. M., & Wands, J. R. (2008). Alzheimer's Disease is Type 3 Diabetes--Evidence Reviewed. *Journal of Diabetes Science and Technology*, 2(6), 1101–1113. doi:10.1177/193229680800200619
- De la Torre, J. C. (2004). Is Alzheimer's disease a neurodegenerative or a vascular disorder? Data, dogma, and dialectics. *The Lancet. Neurology*, 3(3), 184–90. doi:10.1016/S1474-4422(04)00683-0
- Decanini, a, Karunadharma, P. R., Nordgaard, C. L., Feng, X., Olsen, T. W., & Ferrington, D. a. (2008). Human retinal pigment epithelium proteome changes in early diabetes. *Diabetologia*, 51(6), 1051–61. doi:10.1007/s00125-008-0991-2
- Dehabadi, M. H., Davis, B. M., Wong, T. K., & Cordeiro, M. F. (2014). Retinal manifestations of Alzheimer's disease. *Neurodegenerative Disease Management*, 4(3), 241–52. doi:10.2217/nmt.14.19
- Fenwick, E. K., Pesudovs, K., Rees, G., Dirani, M., Kawasaki, R., Wong, T. Y., & Lamoureux, E. L. (2011). The impact of diabetic retinopathy: understanding the patient's perspective. *The British Journal of Ophthalmology*, 95, 774–782. doi:10.1136/pgmj.2010.191312rep
- Ferri, C. P., Prince, M., Brayne, C., Brodaty, H., Fratiglioni, L., Ganguli, M., ... Sczufca, M. (2005). Global prevalence of dementia: a Delphi consensus study. *Lancet*, 366(9503), 2112–7. doi:10.1016/S0140-6736(05)67889-0
- Fowler, B. (2005). Homocysteine: Overview of biochemistry, molecular biology, and role in disease processes. *Seminars in Vascular Medicine*. doi:10.1055/s-2005-872394
- Goto, Y., Kakizaki, M., & Masaki, N. (1976). Production of spontaneous diabetic rats by repetition of selective breeding. *The Tohoku Journal of Experimental Medicine*, 119(1), 85–90.
- Harris, M. I., Cowie, C. C., & Howie, L. J. (1993). Self-monitoring of blood glucose by adults with diabetes in the United States population. *Diabetes Care*, 16, 1116–1123. doi:10.2337/diacare.16.8.1116
- Herrmann, W., & Obeid, R. (2011). Homocysteine: A biomarker in neurodegenerative diseases. *Clinical Chemistry and Laboratory Medicine*. doi:10.1515/CCLM.2011.084
- Ho, P. I., Ashline, D., Dhitavat, S., Ortiz, D., Collins, S. C., Shea, T. B., & Rogers, E. (2003). Folate deprivation induces neurodegeneration: Roles of oxidative

---

stress and increased homocysteine. *Neurobiology of Disease*, *14*, 32–42.  
doi:10.1016/S0969-9961(03)00070-6

Hoogeveen, E. K., Kostense, P. J., Jakobs, C., Dekker, J. M., Nijpels, G., Heine, R. J., ... Stehouwer, C. D. (2000). Hyperhomocysteinemia increases risk of death, especially in type 2 diabetes: 5-year follow-up of the Hoorn Study. *Circulation*, *101*(13), 1506–11. Retrieved from <http://www.ncbi.nlm.nih.gov/pubmed/10747342>

Howlett, D. R., Richardson, J. C., Austin, A., Parsons, A. a, Bate, S. T., Davies, D. C., & Gonzalez, M. I. (2004). Cognitive correlates of Abeta deposition in male and female mice bearing amyloid precursor protein and presenilin-1 mutant transgenes. *Brain Research*, *1017*(1-2), 130–6.  
doi:10.1016/j.brainres.2004.05.029

Hu, Z.-P., Browne, E. R., Liu, T., Angel, T. E., Ho, P. C., & Chan, E. C. Y. (2012). Metabonomic profiling of TASTPM transgenic Alzheimer's disease mouse model. *Journal of Proteome Research*, *11*(12), 5903–13.  
doi:10.1021/pr300666p

Kamath, A. F., Chauhan, A. K., Kisucka, J., Dole, V. S., Loscalzo, J., Handy, D. E., & Wagner, D. D. (2006). Elevated levels of homocysteine compromise blood-brain barrier integrity in mice. *Blood*, *107*, 591–593. doi:10.1182/blood-2005-06-2506

Kern, T. S., & Barber, A. J. (2008). Retinal ganglion cells in diabetes. *The Journal of Physiology*, *586*(Pt 18), 4401–8. doi:10.1113/jphysiol.2008.156695

Khodadadi, S., Riazi, G. H., Ahmadian, S., Hoveizi, E., Karima, O., & Aryapour, H. (2012). Effect of N-homocysteinylation on physicochemical and cytotoxic properties of amyloid  $\beta$ -peptide. *FEBS Letters*, *586*(2), 127–31.  
doi:10.1016/j.febslet.2011.12.018

Klein, R., Palta, M., Allen, C., Shen, G., Han, D. P., & D'Alessio, D. J. (1997). Incidence of retinopathy and associated risk factors from time of diagnosis of insulin-dependent diabetes. *Archives of Ophthalmology*, *115*, 351–356.  
doi:10.1001/archophth.1997.01100150353007

Krady, J. K., Basu, A., Allen, C. M., Xu, Y., LaNoue, K. F., Gardner, T. W., & Levison, S. W. (2005). Minocycline reduces proinflammatory cytokine expression, microglial activation, and caspase-3 activation in a rodent model of diabetic retinopathy. *Diabetes*, *54*(5), 1559–65. Retrieved from <http://www.ncbi.nlm.nih.gov/pubmed/15855346>

- 
- Kruman, I. I., Culmsee, C., Chan, S. L., Kruman, Y., Guo, Z., Penix, L., & Mattson, M. P. (2000). Homocysteine Elicits a DNA Damage Response in Neurons That Promotes Apoptosis and Hypersensitivity to Excitotoxicity, *20*(18), 6920–6926. doi:20(18):6920–6926
- Kruman, I. I., Culmsee, C., Chan, S. L., Kruman, Y., Guo, Z., Penix, L., & Mattson, M. P. (2000). Homocysteine elicits a DNA damage response in neurons that promotes apoptosis and hypersensitivity to excitotoxicity. *The Journal of Neuroscience* □: *The Official Journal of the Society for Neuroscience*, *20*(18), 6920–6926.
- Lee, H., Kim, H. J., Kim, J. M., & Chang, N. (2004). Effects of dietary folic acid supplementation on cerebrovascular endothelial dysfunction in rats with induced hyperhomocysteinemia. *Brain Res*, *996*, 139–147. Retrieved from [http://www.ncbi.nlm.nih.gov/entrez/query.fcgi?cmd=Retrieve&db=PubMed&dopt=Citation&list\\_uids=14697491](http://www.ncbi.nlm.nih.gov/entrez/query.fcgi?cmd=Retrieve&db=PubMed&dopt=Citation&list_uids=14697491)
- Lim, C. P., Loo, A. V. P., Khaw, K. W., Sthaneshwar, P., Khang, T. F., Hassan, M., & Subrayan, V. (2012). Plasma, aqueous and vitreous homocysteine levels in proliferative diabetic retinopathy. *The British Journal of Ophthalmology*, *96*(5), 704–7. doi:10.1136/bjophthalmol-2011-301044
- London, A., Benhar, I., & Schwartz, M. (2013). The retina as a window to the brain—from eye research to CNS disorders. *Nature Reviews. Neurology*, *9*(1), 44–53. doi:10.1038/nrneurol.2012.227
- Malaguarnera, G., Gagliano, C., Giordano, M., Salomone, S., Vacante, M., Bucolo, C., ... Motta, M. (2014). Homocysteine Serum Levels in Diabetic Patients with Non Proliferative, Proliferative and without Retinopathy. *BioMed Research International*, *2014*, 191497. doi:10.1155/2014/191497
- Mangoni, A. A., & Jackson, S. H. D. (2002). Homocysteine and cardiovascular disease: current evidence and future prospects. *The American Journal of Medicine*, *112*, 556–565.
- Mayer, E. L., Jacobsen, D. W., & Robinson, K. (1996). Homocysteine and coronary atherosclerosis. *Journal of the American College of Cardiology*. doi:10.1016/0735-1097(95)00508-0
- McCully, K. S. (2009). Chemical pathology of homocysteine. IV. Excitotoxicity, oxidative stress, endothelial dysfunction, and inflammation. *Annals of Clinical and Laboratory Science*. doi:39/3/219 [pii]

- 
- Mizutani, M., Kern, T. S., & Lorenzi, M. (1996). Accelerated death of retinal microvascular cells in human and experimental diabetic retinopathy. *The Journal of Clinical Investigation*, 97(12), 2883–90. doi:10.1172/JCI118746
- Moreira, P. I., Santos, M. S., Seica, R., & Oliveira, C. R. (2007). Brain mitochondrial dysfunction as a link between Alzheimer's disease and diabetes. *Journal of the Neurological Sciences*, 257(1-2), 206–14. doi:10.1016/j.jns.2007.01.017
- Morris, M. S. (2003). Rapid review Homocysteine and Alzheimer's disease Rapid review, 2(July), 425–428.
- Morrison, H. I., Schaubel, D., Desmeules, M., & Wigle, D. T. (1996). Serum folate and risk of fatal coronary heart disease. *JAMA*, 275, 1893–1896. Retrieved from [http://www.ncbi.nlm.nih.gov/entrez/query.fcgi?cmd=Retrieve&db=PubMed&dopt=Citation&list\\_uids=8648869](http://www.ncbi.nlm.nih.gov/entrez/query.fcgi?cmd=Retrieve&db=PubMed&dopt=Citation&list_uids=8648869)
- Nilsson, K., Gustafson, L., & Hultberg, B. (2002). Relation between plasma homocysteine and Alzheimer's disease. *Dementia and Geriatric Cognitive Disorders*, 14(1), 7–12. doi:58327
- Obeid, R., & Herrmann, W. (2006). Mechanisms of homocysteine neurotoxicity in neurodegenerative diseases with special reference to dementia. *FEBS Letters*, 580(13), 2994–3005. doi:10.1016/j.febslet.2006.04.088
- Ola, M. S., Nawaz, M. I., Khan, H. a, & Alhomida, A. S. (2013). Neurodegeneration and neuroprotection in diabetic retinopathy. *International Journal of Molecular Sciences*, 14(2), 2559–72. doi:10.3390/ijms14022559
- Pacheco-Quinto, J., Rodriguez de Turco, E. B., DeRosa, S., Howard, A., Cruz-Sanchez, F., Sambamurti, K., ... Pappolla, M. A. (2006). Hyperhomocysteinemic Alzheimer's mouse model of amyloidosis shows increased brain amyloid  $\beta$  peptide levels. *Neurobiology of Disease*, 22, 651–656. doi:10.1016/j.nbd.2006.01.005
- PANCHARUNITI, N., LEWIS, C. A., SAUBERLICH, H. E., PERKINS, L. L., GO, R. C. P., ALVAREZ, J. O., ... ROSEMAN, J. M. (1994). PLASMA HOMOCYST(E)INE, FOLATE, AND VITAMIN-B12 CONCENTRATIONS AND RISK FOR EARLY-ONSET CORONARY-ARTERY DISEASE. *AMERICAN JOURNAL OF CLINICAL NUTRITION*, 59, 940–948.
- Portha, B. (2005). Programmed disorders of beta-cell development and function as one cause for type 2 diabetes? The GK rat paradigm. *Diabetes/metabolism Research and Reviews*, 21(6), 495–504. doi:10.1002/dmrr.566

- 
- Ramakrishnan, S., Sulochana, K. N., Lakshmi, S., Selvi, R., & Angayarkanni, N. (2006). Biochemistry of homocysteine in health and diseases. *Indian Journal of Biochemistry & Biophysics*, *43*(5), 275–283.
- Reif, A., Pfuhlmann, B., & Lesch, K.-P. (2005). Homocysteinemia as well as methylenetetrahydrofolate reductase polymorphism are associated with affective psychoses. *Progress in Neuro-Psychopharmacology & Biological Psychiatry*, *29*(7), 1162–8. doi:10.1016/j.pnpbp.2005.06.027
- Rein, D. B., Zhang, P., Wirth, K. E., Lee, P. P., Hoerger, T. J., McCall, N., ... Saaddine, J. (2006). The economic burden of major adult visual disorders in the United States. *Archives of Ophthalmology*, *124*, 1754–1760. doi:10.1001/archoph.124.12.1754
- Reitz, C., & Mayeux, R. (2014). Alzheimer disease: epidemiology, diagnostic criteria, risk factors and biomarkers. *Biochemical Pharmacology*, *88*(4), 640–51. doi:10.1016/j.bcp.2013.12.024
- Risacher, S. L., WuDunn, D., Pepin, S. M., MaGee, T. R., McDonald, B. C., Flashman, L. A., ... Saykin, A. J. (2013). Visual contrast sensitivity in Alzheimer's disease, mild cognitive impairment, and older adults with cognitive complaints. *Neurobiology of Aging*, *34*, 1133–1144. doi:10.1016/j.neurobiolaging.2012.08.007
- Rizzo, M., Anderson, S. W., Dawson, J., & Nawrot, M. (2000). Vision and cognition in Alzheimer's disease. *Neuropsychologia*, *38*(8), 1157–69. Retrieved from <http://www.ncbi.nlm.nih.gov/pubmed/10838150>
- Robinson, K., Mayer, E. L., Miller, D. P., Green, R., van Lente, F., Gupta, A., ... Nissen, S. E. (1995). Hyperhomocysteinemia and low pyridoxal phosphate. Common and independent reversible risk factors for coronary artery disease. *Circulation*, *92*, 2825–2830. doi:10.1161/01.CIR.92.10.2825
- ROTH, M. (1955). The natural history of mental disorder in old age. *The Journal of Mental Science*, *101*, 281–301.
- Salomone, S., Caraci, F., Leggio, G. M., Fedotova, J., & Drago, F. (2012). New pharmacological strategies for treatment of Alzheimer's disease: focus on disease modifying drugs. *British Journal of Clinical Pharmacology*, *73*(4), 504–17. doi:10.1111/j.1365-2125.2011.04134.x
- Schalinske, K. L., & Smazal, A. L. (2012). Homocysteine imbalance: a pathological metabolic marker. *Advances in Nutrition (Bethesda, Md.)*, *3*(6), 755–62. doi:10.3945/an.112.002758
-

- 
- Simó, R., & Hernández, C. (2012). Neurodegeneration is an early event in diabetic retinopathy: therapeutic implications. *The British Journal of Ophthalmology*, *96*(10), 1285–90. doi:10.1136/bjophthalmol-2012-302005
- Spijkerman, A. M. W., Dekker, J. M., Nijpels, G., Adriaanse, M. C., Kostense, P. J., Ruwaard, D., ... Heine, R. J. (2003). Microvascular complications at time of diagnosis of type 2 diabetes are similar among diabetic patients detected by targeted screening and patients newly diagnosed in general practice: the hoorn screening study. *Diabetes Care*, *26*(9), 2604–8. doi:10.2337/diacare.26.9.2604
- Stamler, J., Vaccaro, O., Neaton, J. D., & Wentworth, D. (1993). Diabetes, other risk factors, and 12-yr cardiovascular mortality for men screened in the multiple risk factor intervention trial. *Diabetes Care*, *16*, 434–444.
- Steen, E., Terry, B. M., Rivera, E. J., Cannon, J. L., Neely, T. R., Tavares, R., ... de la Monte, S. M. (2005). Impaired insulin and insulin-like growth factor expression and signaling mechanisms in Alzheimer's disease--is this type 3 diabetes? *Journal of Alzheimer's Disease*: *JAD*, *7*(1), 63–80. Retrieved from <http://www.ncbi.nlm.nih.gov/pubmed/15750215>
- Thambisetty, M., & Lovestone, S. (2010). Blood-based biomarkers of Alzheimer's disease: challenging but feasible. *Biomarkers in Medicine*, *4*, 65–79. doi:10.2217/bmm.09.84
- Ubbink, J. B. (1995). Homocysteine--an atherogenic and a thrombogenic factor? *Nutrition Reviews*, *53*, 323–325.
- Welch, G. N., & Loscalzo, J. (1998). Homocysteine and atherothrombosis. *The New England Journal of Medicine*, *338*(15), 1042–50. doi:10.1056/NEJM199804093381507
- Wild, S., Roglic, G., Green, A., Sicree, R., & King, H. (2004). Global Prevalence of Diabetes: Estimates for the year 2000 and projections for 2030. *Diabetes Care*, *27*, 1047–1053. doi:10.2337/diacare.27.5.1047
- Wright, a D., Martin, N., & Dodson, P. M. (2008). Homocysteine, folates, and the eye. *Eye (London, England)*, *22*(8), 989–93. doi:10.1038/sj.eye.6703061
- Yang, Y., & Song, W. (2013). Molecular links between Alzheimer's disease and diabetes mellitus. *Neuroscience*, *250*, 140–50. doi:10.1016/j.neuroscience.2013.07.009
- Zavrelova, H., Hoekstra, T., Alsema, M., Welschen, L. M. C., Nijpels, G., Moll, A. C., ... Dekker, J. M. (2011). Progression and regression: Distinct developmental patterns of diabetic retinopathy in patients with type 2 diabetes



---

treated in the Diabetes Care System West-Friesland, the Netherlands. *Diabetes Care*, 34, 867–872. doi:10.2337/dc10-1741

Zhang, C.-E., Wei, W., Liu, Y.-H., Peng, J.-H., Tian, Q., Liu, G.-P., ... Wang, J.-Z. (2009). Hyperhomocysteinemia increases beta-amyloid by enhancing expression of gamma-secretase and phosphorylation of amyloid precursor protein in rat brain. *The American Journal of Pathology*, 174, 1481–1491. doi:10.2353/ajpath.2009.081036

Zhuo, J. M., Wang, H., & Praticò, D. (2011). Is hyperhomocysteinemia an Alzheimer's disease (AD) risk factor, an AD marker, or neither? *Trends in Pharmacological Sciences*. doi:10.1016/j.tips.2011.05.003