

Coronary Involvement in Marfan Syndrome: The Role of Electrocardiographically Gated Computed Tomography Angiography

Rocco Donato, Emanuele David, Alfredo Blandino, Michele Gaeta, Domenico Spinelli¹, Giorgio Ascenti

Department of Radiological Sciences, University of Messina, ¹Department of Cardiovascular Surgery, Unit of Vascular Surgery, University of Messina, Messina, Italy

Abstract

We report a case of coronary artery and aortic root aneurysms in a 50-year-old man with Marfan syndrome. The coexistence of these findings is uncommon and rarely reported. We underline the role of electrocardiographically gated computed tomography angiography in the diagnosis of coronary aneurysm in this category of patients.

Keywords: Cardiac computed tomography, coronary aneurysm, coronary computed tomography angiography, Marfan syndrome

INTRODUCTION

Coronary artery aneurysm is an uncommon finding, often clinically silent, whose correct diagnosis may prevent severe sudden cardiac events. The use of electrocardiographically (ECG) gated during computed tomography (CT) angiography is an indispensable technical requirement for the identification of these findings and should always be used in the follow-up of this category of patients.

CASE REPORT

We present the case of a 50-year-old man who referred to the emergency department with sudden chest pain at rest. His blood pressure was 95/60 mmHg. The patient suffered from Marfan syndrome and he was followed in our Department of Clinical Medicine for some years. Routine blood, including cardiac enzymes, and urine analyses were within normal ranges, except C-reactive protein (252 mg/L) and erythrocyte sedimentation rate (84 mm/h). The patient was hospitalized in our cardiology unit and a CT of thorax was request. We chose to subject the patient to a CT angiography “Dual Source” ECG-synchronized to have an optimum viewing of aorta and coronary arteries. The CT scan identified a known aortic root dilatation (44 mm), it excluded the presence of coronary stenosis, but it also allowed finding an important new finding: a right coronary

artery aneurysm (8 mm), in the middle and proximal tract, with craniocaudal extension of 4 cm [Figure 1]. Following heart surgeon consulting, according to the characteristics of the aneurysm and in absence of coronary thrombosis, surgical or interventional treatment of the aneurysm were deprecated. In addition to medical therapy with beta-blockers, we decided to treat our patient with aspirin.

DISCUSSION

Our case confirms the importance of performing an ECG-gated CT, often not used and underestimated, to study pathologies of the thoracic aorta. In particular, in patients with Marfan syndrome, the clinical symptoms are sometimes caused by coronary disease rather than great vessels disease.^[1] We recommend as reported in the literature and in the most modern guidelines^[2-4] to always perform, when it is possible, an ECG-gated CT of thoracic aorta to avoid unpleasant consequences which a late diagnosis or a not diagnosis can lead.

Address for correspondence: Dr. Rocco Donato,
Department of Radiological Sciences, University of Messina, Messina, Italy.
E-mail: rdonato@unime.it

This is an open access article distributed under the terms of the Creative Commons Attribution-NonCommercial-ShareAlike 3.0 License, which allows others to remix, tweak, and build upon the work non-commercially, as long as the author is credited and the new creations are licensed under the identical terms.

For reprints contact: reprints@medknow.com

How to cite this article: Donato R, David E, Blandino A, Gaeta M, Spinelli D, Ascenti G. Coronary involvement in marfan syndrome: The role of electrocardiographically gated computed tomography angiography. *J Cardiovasc Echography* 2017;27:64-5.

Access this article online	
Quick Response Code: 	Website: www.jcecho.org
	DOI: 10.4103/jcecho.jcecho_43_16

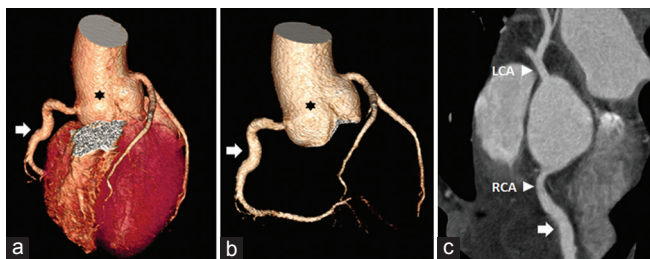


Figure 1: (a and b) Volume rendering reconstruction revealed the aneurysm of aortic root (black asterisk) and an aneurysm (white arrow) of the middle-proximal tract of RCA. (c) Curved multiplanar reconstruction showed the origin of both coronary artery and the aneurysm of RCA (white arrow). LCA: Left coronary artery, RCA: Right coronary artery.

Financial support and sponsorship

Nil.

Conflicts of interest

There are no conflicts of interest.

REFERENCES

1. Diaz-Zamudio M, Bacilio-Pérez U, Herrera-Zarza MC, Meave-González A, Alexanderson-Rosas E, Zambrana-Balta GF, *et al.* Coronary artery aneurysms and ectasia: Role of coronary CT angiography. *Radiographics* 2009;29:1939-54.
2. di Cesare E, Carbone I, Carriero A, Centonze M, De Cobelli F, De Rosa R, *et al.* Clinical indications for cardiac computed tomography. From the Working Group of the Cardiac Radiology Section of the Italian Society of Medical Radiology (SIRM). *Radiol Med* 2012;117:901-38.
3. Cademartiri F, Di Cesare E, Francone M, Ballerini G, Ligabue G, Maffei E, *et al.* Italian registry of cardiac computed tomography. *Radiol Med* 2015;120:919-29.
4. Taylor AJ, Cerqueira M, Hodgson JM, Mark D, Min J, O'Gara P, *et al.* ACCF/SCCT/ACR/AHA/ASE/ASNC/NASCI/SCAI/SCMR 2010 appropriate use criteria for cardiac computed tomography. A report of the American College of Cardiology Foundation Appropriate Use Criteria Task Force, the Society of Cardiovascular Computed Tomography, the American College of Radiology, the American Heart Association, the American Society of Echocardiography, the American Society of Nuclear Cardiology, the North American Society for Cardiovascular Imaging, the Society for Cardiovascular Angiography and Interventions, and the Society for Cardiovascular Magnetic Resonance. *J Am Coll Cardiol* 2010;56:1864-94.

