





## CASE REPORT

# A case of high-risk AML in a patient with advanced systemic mastocytosis

Manlio Fazio<sup>1</sup>  | Calogero Vetro<sup>2</sup> | Uroš Markovic<sup>2</sup>  | Andrea Duminuco<sup>1</sup> | Marina Parisi<sup>2</sup> | Cinzia Maugeri<sup>2</sup> | Elisa Mauro<sup>2</sup> | Nunziatina Laura Parrinello<sup>2</sup> | Fabio Stagno<sup>2</sup> | Loredana Villari<sup>3</sup> | Anna Maria Triolo<sup>2</sup> | Stefania Stella<sup>4</sup> | Giuseppe A. Palumbo<sup>1,5,6</sup> | Francesco Di Raimondo<sup>2,5</sup> | Alessandra Romano<sup>5</sup>  | Roberta Zanotti<sup>7</sup> 

<sup>1</sup>Post Graduation School of Hematology, University of Catania, A.O.U. Policlinico “G.Rodolico-San Marco”, Catania, Italy

<sup>2</sup>Division of Hematology, A.O.U. Policlinico “G.Rodolico-San Marco”, Catania, Italy

<sup>3</sup>Department of Pathology, A.O.U. Policlinico di Catania, Catania, Italy

<sup>4</sup>Center of Experimental Oncology and Hematology, A.O.U. Policlinico “G. Rodolico-San Marco”, Catania, Italy

<sup>5</sup>Dipartimento di specialità Medico-Chirurgiche, CHIRMED, sezione di Ematologia, Università degli Studi di Catania, Catania, Italy

<sup>6</sup>Dipartimento di Scienze Mediche, Chirurgiche e Tecnologie Avanzate “G.F. Ingrassia”, University of Catania, Catania, Italy

<sup>7</sup>Department of Medicine, Hematology Unit, Azienda Ospedaliera Universitaria Integrata di Verona, Verona, Italy

**Correspondence**

Alessandra Romano, Dipartimento di specialità Medico-Chirurgiche, CHIRMED, sezione di Ematologia, Università degli Studi di Catania, Catania, Italy.

Email: [sandrina.romano@gmail.com](mailto:sandrina.romano@gmail.com)

**Abstract**

Aggressive SM+AML has limited therapeutic options. Even a strong combination of decitabine–venetoclax–midostaurin has a transient effect on AML and a mitigated effect on SM. Larger series are required to identify the best therapeutic strategy.

**KEYWORDS**

advanced systemic mastocytosis (AdvSM), cladribine, concurrent hematologic disease, decitabine–venetoclax (DEC-VEN), HAM regimen, refractory acute myeloid leukemia (R-AML)

## 1 | INTRODUCTION

Systemic mastocytosis (SM) can be associated with another hematologic neoplasia including acute myeloid leukemia (AML). Adopting triplet combination for both diseases with decitabine–venetoclax–midostaurin could be a valid option. However, even if leukemia responds, mastocytosis can persist with a lower mutational

burden, eventually prompting AML relapse with a very dismal prognosis.

Systemic mastocytosis (SM) is a rare disease that derives from an abnormal proliferation of clonal mast cells (MCs) in extracutaneous organs such as bone marrow (BM), lymph nodes, spleen, liver, bones, and gastrointestinal tract. The affected patients are at high risk of suffering from life-threatening anaphylaxis and may develop even a

This is an open access article under the terms of the [Creative Commons Attribution-NonCommercial-NoDerivs](https://creativecommons.org/licenses/by-nc-nd/4.0/) License, which permits use and distribution in any medium, provided the original work is properly cited, the use is non-commercial and no modifications or adaptations are made.

© 2023 The Authors. *Clinical Case Reports* published by John Wiley & Sons Ltd.

MC activation syndrome (MCAS). According to the WHO classification, the diagnosis of SM can be established when either one major and one minor or at least three minor criteria are fulfilled.<sup>1</sup>

SM is an umbrella term which encompasses a wide spectrum of clinical entities, from indolent (ISM) and smoldering (SSM) to advanced SM (AdvSM).<sup>2</sup> SSM is characterized by the presence of two or more B-findings which are indicative of high MCs burden but without organ damage (>30% MCs in the BM and/or serum tryptase >200 µg/dL and/or *cKITD816V* mutation with a variant allele frequency [VAF] ≥10%; hypercellular and dysplastic BM without criteria for myelodysplastic syndrome [MDS]; hepatomegaly or splenomegaly in the absence of functional impairment). AdvSM includes: aggressive SM (ASM) which has a median overall survival (OS) of 41 months, SM with associated non-mast cell hematologic neoplasm (SM-AHN) which has a median OS of 24 months,<sup>3</sup> and mast cell leukemia (MCL) which has a median OS of 2 months. ASM is characterized by the presence of one or more C-findings which are indicative of organ damage (cytopenia, hepatomegaly and splenomegaly with functional impairment, intestinal malabsorption with hypoalbuminemia and weight loss, osteolytic lesions with pathological fractures).<sup>1</sup> AHNs derive from the myeloid lineage in 80%–90% of cases and chronic myelomonocytic leukemia (CMML) is the most frequently associated one.<sup>4</sup>

The most common mutations detected in SM are somatic activating mutations in *cKIT*, most notably *cKITD816V*.<sup>5</sup> These mutations can also be detected in the concomitant myeloid (but not in lymphoid) AHNs. Moreover, most patients with AdvSM show additional somatic mutations both on SM and AHN cells (most frequently *SRSF2*, *ASXL1*, *RUNX1 [S/A/R]*, *TET2*, and *JAK2*).<sup>6</sup> This mutational multilineage involvement strengthens the hypothesis of a clonal relationship between these two diseases.<sup>7</sup>

Midostaurin is a multikinase inhibitor that targets both wild-type and *D816V*-mutated *c-KIT* and has been largely approved for the treatment of both *FLT3*-mutated acute myeloid leukemia (AML) and AdvSM.<sup>8</sup>

## 2 | CASE PRESENTATION

A 69-year-old Caucasian man presented at our center in March 2017 due to neutrophilic leukocytosis (white blood cell [WBC] count 16.380 cells/µL) and normal Hb and platelet values, along with maculo-papular cutaneous lesions dating from 2010. A skin biopsy performed shortly after confirmed the diagnosis of cutaneous mastocytosis (CM). In past medical history, the patient referred

hypertension, glucose intolerance. No allergies or syncope or other mediator-related symptoms were reported.

BM histological analysis revealed the presence of aggregates with >15 atypical mast cell CD117<sup>+</sup>, CD34<sup>-</sup>, CD25<sup>+</sup>, tryptase<sup>+</sup>, consensual to reticulin fibrosis and focally collagen (Grade 2–3). *cKITD816V* mutation was demonstrated in peripheral blood (PB) (VAF: 12%).<sup>9</sup> BM karyotype was normal. Baseline serum tryptase level was 184 µg/dL (n.r. 0.1–11.4 µg/dL); normal alkaline phosphatase (ALP); increased β2 microglobulin serum levels.

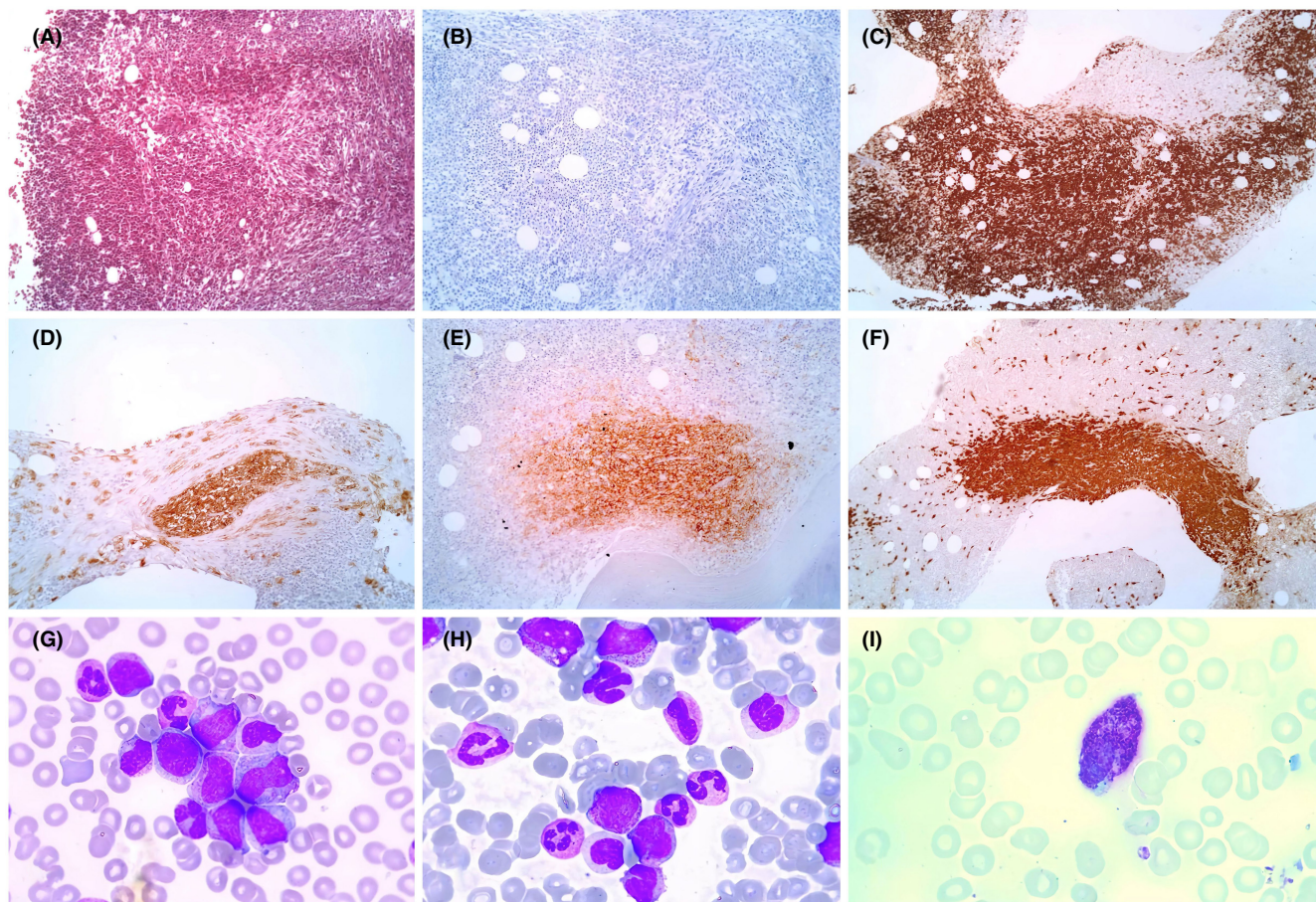
The further presence of more than 90% neutrophils (N) in PB together with predominant maturing granulopoiesis in the BM histological sample was suggestive of a concomitant chronic neutrophilic leukemia (CNL). Twenty-seven different myeloid genes were analyzed in PB, using next-generation sequencing (NGS), including *BCR-ABL1*, *FIPIL1-PDGFRα*, *JAK2V617F*, *MPL*, *CARL*, with no evidence of mutations including that of the *CSF3R* gene, characteristic of CNL. Lastly, the absence of ≥10% peripheral monocytes excluded the hypothesis of a CMML.<sup>4</sup>

Osteopenia was documented by DEXA (T score –1.8 at lumbar spine) and diffuse osteosclerosis with micro osteolysis at skull was documented by low-dose CT scans. Abdominal ultrasound showed only mild hepatomegaly.

Thus, the final diagnosis was ISM associated with MPN/MDS overlap syndrome (ISM-AHN)<sup>3</sup> (Figure 1A–F). The patient was started on H1/H2 antagonist treatment and vitamin D supplementation together with hydroxyurea (HU, 500 mg bis in die) and maintained good general conditions for 4 years with moderate leukocytosis and decrease in serum tryptase level (from initial 184 to 73 µg/dL).

Follow-up histological BM analysis performed in 2020 showed an increase in MC infiltration (30%–35%) with neoplastic immunophenotype and <5% of CD34<sup>+</sup> blasts. Routine low-dose CT scans revealed osteosclerosis, and the abdomen ultrasound revealed liver steatosis and mild splenomegaly, in absence of cytopenia. These results documented the progression from ISM to SSM.<sup>3</sup>

In March 2021 the patient presented at our center with weakness, loss of sense of well-being and weight loss (3 kg in the last 2 months). The complete blood count (CBC) showed 218,000 WBC/µL (N 43.5%, lymphocytes 11.9%, monocytes 24.6% and blasts 20% on PB differential count) without severe anemia or thrombocytopenia. The evolution of MPN/MDS syndrome to AML was confirmed at PB flow cytometry: presence of 23% blasts with a CD33<sup>+</sup>, HLA-DR<sup>+</sup>, CD34<sup>+</sup>, and CD117<sup>+</sup> immunophenotype (Figure 1G,H). BM biopsy was not performed due to patient refusal. Physical exam revealed the increase in both splenomegaly and hepatomegaly (palpable from costal margin at 6 and 3 cm, respectively). Laboratory



**FIGURE 1** Immunohistochemical features of SM-AHN (A–F). Photomicrograph of the bone marrow histology and immunohistochemistry supporting the diagnosis of SM-AHN. SM and MDS/MPN: hypercellularity, granulocytic lineage expansion and paratrabecular infiltration of mast cells (MCs) (arrow) with the characteristic delicate fibrosis (arrowed), hematoxylin and eosin (H&E) stain (A); paratrabecular infiltration of MCs. The mast cell granules are well highlighted by the metachromatic staining with toluidine blue (B); cellularity predominantly determined by granulopoiesis expressing CD15 (C); positive immunostaining (brown) of spindle-shaped MCs with CD 117 (D), CD25 (E), and tryptase (F). Morphology (G–I). AML: blasts and neutrophils (leukemic hiatus) (G, H). This PB smear was made after the first cycle of venetoclax and shows blast clearance with the persistence of pathologic spindle-shaped MCs (in the picture) (I).

investigations showed serum tryptase  $>200\mu\text{g/dL}$ ; NGS study on PB showed an increase in *cKITD816V* (38%) along with an additional high risk *RUNX-1 I342 K* mutation (VAF: 5%).<sup>10</sup> The presence of Grade 2 hypoalbuminemia ( $2.22\text{g/dL}$ —n.r.  $3.50\text{--}5.20$ ) were considered related to SM and described as C-findings, hence confirming the evolution from SSM to ASM with a final diagnosis of ASM associated with secondary AML.<sup>3</sup>

We decided to treat the patient with the decitabine–venetoclax combination (DEC-VEN) as a first-line therapy for AML<sup>11</sup> and midostaurin as a first-line therapy for ASM. We did not choose chemotherapy because of age and patient refusal to be hospitalized. In the absence of a sibling donor, we activated unrelated donor research. Due to significant leukocytosis and the high risk of tumor lysis syndrome, venetoclax was initially omitted, and decitabine was administered ( $20\text{mg/m}^2$  i.v. for 5 days/cycle) associated with HU ( $1000\text{mg/day}$ ).

After two cycles of decitabine and HU, the WBC was  $9220\text{ cells}/\mu\text{L}$ ; thereafter, the patient was treated with a third cycle of therapy with venetoclax ( $400\text{mg daily}$ ) for 28 days/cycle and decitabine ( $20\text{mg/m}^2$ ) for 5 days/cycle.

Midostaurin was initially imbricated with decitabine and HU and administered at a daily dose of  $200\text{mg}$  but was progressively reduced due to hematologic toxicity and suspended before venetoclax imbrication because of progressive symptomatic thrombocytopenia.

After the third cycle of therapy including venetoclax, a BM biopsy was performed that revealed a total blast clearance (morphologic leukemia-free state MLFS), although pathological  $\text{CD}25^+$  MC infiltration was stable (30%) (Figure 1I). Despite this, the *cKITD816V* mutation burden appeared reduced (10%), albuminemia returned within normal ranges, tryptase levels dropped to  $84.3\mu\text{g/dL}$ , and at physical examination spleen and liver

appeared completely reseeded. Thus, SM was deemed in clinical improvement by combined consensus IWG-MRT-ECNM response criteria.<sup>12</sup>

He subsequently received a fourth cycle of therapy with DEC-VEN combination but venetoclax was temporarily suspended throughout the cycle in order to allow neutrophil recovery. Unfortunately, blood examinations repeated 1 month later documented AML relapse with peripheral leukocytosis (WBC 67,880/ $\mu$ L) and 30% blasts on PB differential count; serum tryptase level was 91.3  $\mu$ g/dL; spleen and liver appeared enlarged at manual palpation (4 and 2 cm from costal margin, respectively); albumin level was at the lower limit. Once the patient was again debulked with HU, another cycle of DEC-VEN was administered, associated with midostaurin at half dosage (100 mg/die).

Despite an initial benefit, the patient developed refractoriness to this regimen. Abdominal examination revealed a massive splenomegaly of 8 cm below the left costal margin, and a PB smear showed 60% blasts. As a consequence, the patient was hospitalized in order to undergo salvage chemotherapy as a possible bridge to allogeneic stem cell transplantation (allo-HSCT). The patient was treated with HAM regimen<sup>13</sup> in association with cladribine.<sup>14</sup> Our intention was to treat both pathologies considering that cladribine is effective both on R/R-AML<sup>15</sup> and AdvSM.<sup>16</sup> The scheme we administered consisted of: Ara-C 2000 mg i.v. bis in die (from Day +1 to Day +4), mitoxantrone 10 mg/die i.v. (from Day +3 to Day +5), and cladribine 7 mg/die subcutaneously (from Day +1 to Day +5). Dose was calculated on ideal weight and reduced due to age and performance status. For the prophylaxis of HD-Ara-C-induced photophobia and conjunctivitis, he received glucocorticoid eye drops every 6 h starting before the first dose and continuing for 24 h after the last dose of HD-Ara-C.

Despite achieving a decreased serum tryptase level (from 69.9 at the admission to 54.8  $\mu$ g/dL) and organomegaly reduction, the patient experienced prolonged Grade 4 pancytopenia (Hb <7 g/dL, PLT <2000/ $\mu$ L, WBC <100/ $\mu$ L), which required constant red blood cell and platelet transfusions. Furthermore, he developed a septic state that led to exitus on Day +18 from the HAM treatment start (Figure 2).

### 3 | DISCUSSION

The association between AML, especially *cKIT D816<sup>mut</sup>/CBF<sup>neg</sup>* AML, and SM determines a particularly dismal prognosis. A retrospective analysis published in 2019 reported 40 *KIT D816<sup>mut</sup>/CBF<sup>neg</sup>* SM-AML patients (29 with secondary AML evolved from SM  $\pm$  associated myeloid neoplasm). The median OS of the 40 SM-AML patients was 5.4 months and thus even worse as compared

to patients with MCL, which is defined by the presence of  $\geq 20\%$  MCs in a BM smear. SM-AML patients treated with intensive chemotherapy (including HAM regimen)  $\pm$  allo-HSCT achieved a higher OS (16.7 months) than those who received non-intensive treatment as hypomethylating agents (HMAs)  $\pm$  cladribine (2.7 months). HMAs do not induce any complete remission (CR) in SM-AML and none of the patients was treated with midostaurin.<sup>17</sup>

The association of HMAs with venetoclax could achieve a CR/sustained response (SR) in both diseases, even with different response time, as reported in some case reports.<sup>18,19</sup> In none of them midostaurin was imbricated to the scheme. Venetoclax is a Bcl-2 inhibitor with confirmed efficacy in combination with HMAs in patients with previously untreated AML who were ineligible for intensive induction therapy. The HMAs-VEN regimen had significant improvement in terms of OS, CR, and duration of response.<sup>20</sup>

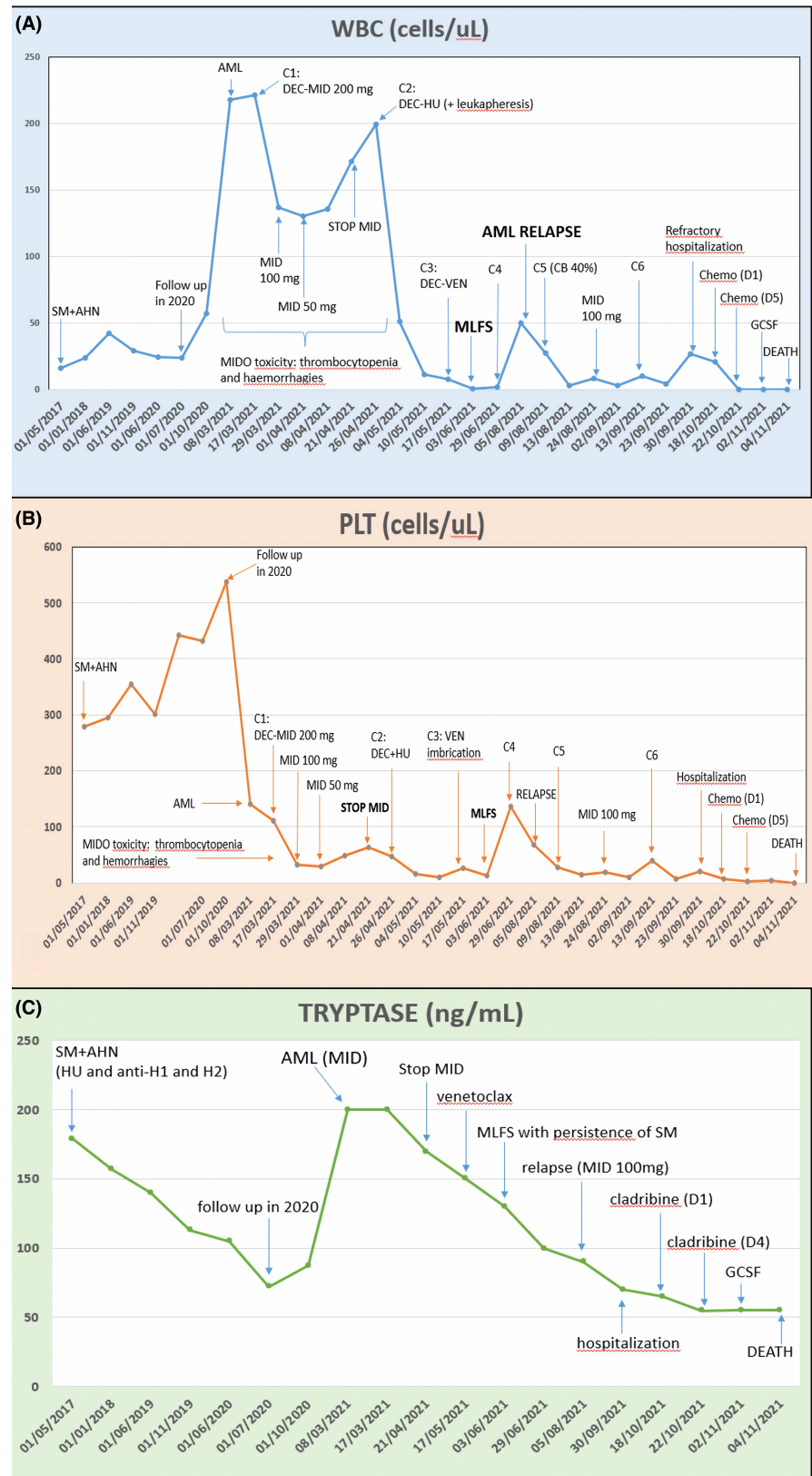
High expression of Bcl-2 is also typical in AdvSM, including SM-AML. Considering that neoplastic MCs and AML derive from the same malignant clone and that leukemia stem cells are Bcl-2+, venetoclax can prevent MC differentiation by targeting Bcl-2 in the neoplastic progenitors.<sup>18</sup>

The expression of Bcl-2 determines partial resistance to midostaurin monotherapy in AdvSM. According to the study D2201, midostaurin is the only approved agent in first-line therapy for AdvSM with *KITD816V* mutation, achieving mainly partial (PR) or major responses (MR) that are not sustained.<sup>21</sup> A recent preliminary study demonstrated that midostaurin restores apoptotic dependency to Bcl-2 in MCL-like cells and justified a possible employment of midostaurin associated with venetoclax front-line therapy in mast cell tumors.<sup>22</sup>

Our patient obtained MLFS and SM clinical improvement after two cycles of decitabine associated with midostaurin and one cycle of DEC-VEN. Unfortunately, midostaurin administration necessitated interruption before the introduction of venetoclax due to hematologic toxicity. Nevertheless, we decided to reintroduce midostaurin at half dosage during the fifth cycle of DEC-VEN, after AML relapse, motivated by the persistence of pathological MCs in the BM.

Similar cases of SM-AML have been reported in the literature describing the permanence of a residual mast cell infiltrate in the BM despite AML remission with an induction regimen or following stem cell allograft.<sup>23</sup> Most importantly, MCs release numerous factors (histamine, heparin, tryptase, cytokines) in the microenvironment, thus enhancing tumor-associated angiogenesis.<sup>24</sup> As a consequence, the residual MC infiltrates potentially create a favorable substrate for further progression or the recurrence of the associated hematologic neoplasms.<sup>25</sup>

**FIGURE 2** Graphs representing the trend of white blood cell count (A), platelet count (B), and tryptase level (C) from SM-AHN diagnosis in 2017 until exitus in 2021. The graphs reflect the patient's measured platelet count (PLT), white blood cell count (WBC), and tryptase level after treatment with HU and H1/H2 antagonists, MDS/MPN evolution to AML and SM-AML I and II line therapies. AML, acute myeloid leukemia; C, cycle; DEC, decitabine; D, day; GCSF, granulocyte colony-stimulating factor; HU, hydroxyurea; MID, midostaurine; MLFS, morphologic leukemia-free state; SM-AHN, systemic mastocytosis with associated hematologic neoplasm; VEN, venetoclax.



Within a short time the patient became refractory to the triplet (DEC-VEN-MIDO) and was immediately hospitalized in order to undergo salvage therapy with HAM regimen (for R/R-AML) associated with cladribine (both for AdvSM and R/R-AML) as a bridge to transplant.<sup>13</sup>

Relapsed/refractory (R/R) AML remains an impervious hematologic challenge with generally poor outcomes and despite the existence of a wide armamentarium of second-line regimens, none of them is significantly beneficial compared to the others.<sup>26</sup> A German clinical phase I/II

study investigated the tolerability and efficacy of high-dose cytosine arabinoside and mitoxantrone (HAM) in heavily pretreated patients with advanced refractory disease. A total of 40 patients was recruited in the study (median age 45 years); 21 patients (53%) achieved CR (19 of them after one HAM course and two of them after two HAM courses); one additional patient obtained a PR (normalization of PB counts but with residual 15% blasts in the BM). Most common non-hematologic toxicity was represented by nausea, vomiting, mucositis, and diarrhea. These results demonstrated that the HAM regimen could achieve a high ORR in a very unfavorable category of patients and suggested it should be employed in earlier stages of the disease.<sup>13</sup>

Cladribine is a polyvalent antimetabolite which has been used for both R/R-AML and SM. It is an adenosine-deaminase resistant analog of adenosine which is activated inside the cells and induces apoptosis in hematopoietic cells, leukemic cells, and lymphatic malignancies. Several reports describe how cladribine induces CRs (100% regression) in cutaneous forms and major (complete resolution of at least one C-findings and no progression of other C-findings) or PRs in indolent and AdvSM.<sup>16</sup>

On the other hand, a meta-analysis of 10 prospective studies evaluated the role of cladribine in R/R-AML showing a significant prognostic improvement, especially when combined with cytarabine in cladribine/cytarabine/G-CSF/mitoxantrone regimen (CLAG-M).<sup>15</sup> The reason for this synergistic effect is due to the fact that cladribine increases cytarabine uptake in leukemia cells and the accumulation of its active cytotoxic metabolite (Ara-CTP).<sup>27</sup> The most common toxicities caused by cladribine are myelosuppression (severe neutropenia and thrombocytopenia), immunosuppression (low TCD4<sup>+</sup> and TCD8<sup>+</sup> levels) and subsequent opportunistic infections (Grades 3 and 4), the latter being the main cause of early death as in this case.<sup>15</sup>

## 4 | CONCLUSION

The employment of an HMA-venetoclax regimen in combination with midostaurin (or other *KIT* inhibitors)<sup>5,28</sup> could be an option for patients with AML associated with SM, but data about this combination, dosage of midostaurin and their toxicity are lacking. However, in our case, MLFS was achieved, but pathologic mastocyte infiltration appeared stable and only clinical improvement of SM was obtained.

The efficacy and safety of the HAM regimen combined with cladribine in R/R-AML have been documented, but there are no cases in the literature about the employment of this therapeutic scheme in SM

associated with R/R-AML. Unfortunately, our attempt was not valuable. More specifically, even though treatment allowed to decrease serum tryptase level, the patient developed Grade 4 neutropenia and died because of septic shock during aplasia.

For these reasons, further studies are necessary to understand the validity of the abovementioned therapeutic combinations in this particular set of patients.

## AUTHOR CONTRIBUTIONS

**Manlio Fazio:** Conceptualization; writing – original draft. **Calogero Vetro:** Conceptualization; data curation. **Uros Markovic:** Writing – review and editing. **Andrea Duminuco:** Writing – review and editing. **Marina Silvia Parisi:** Investigation. **Cinzia Maugeri:** Investigation. **Elisa Mauro:** Investigation. **Nunziatina Laura Parrinello:** Investigation. **Fabio Stagno:** Investigation. **Loredana Villari:** Investigation. **Anna Maria Triolo:** Investigation. **Stefania Stella:** Investigation. **Giuseppe Palumbo:** Supervision. **Francesco Di Raimondo:** Supervision. **Alessandra Romano:** Conceptualization; data curation; investigation; project administration; writing – review and editing. **Roberta Zanotti:** Data curation; supervision; writing – review and editing.

## ACKNOWLEDGMENTS

Authors thank AIL (Associazione Italiana Leucemia e Linfomi) Sezione di Catania and ASIMAS (Associazione Italiana Mastocitosi) for their commitment to research and support to people affected by these diseases.

## CONFLICT OF INTEREST STATEMENT

The authors declare that they had no sources of funding for this study and no potential conflicts of interest with respect to the research, authorship, and/or publication of this article.

## DATA AVAILABILITY STATEMENT

All data analyzed during this study are included in this article.

## ETHICS STATEMENT


This study was conducted in accordance with the Declaration of Helsinki. The authors obtained written consent to use personal data of the patient for the publication of this case report.

## ORCID

Manlio Fazio  <https://orcid.org/0000-0001-8804-2640>

Uroš Markovic  <https://orcid.org/0000-0003-0868-5676>

Alessandra Romano  <https://orcid.org/0000-0002-6333-4433>

Roberta Zanotti  <https://orcid.org/0000-0003-2871-9730>

## REFERENCES

- Arber DA, Orazi A, Hasserjian RP, et al. International consensus classification of myeloid neoplasms and acute leukemias: integrating morphologic, clinical, and genomic data. *Blood*. 2022;140(11):1200-1228.
- Valent P, Akin C, Sperr WR, et al. New insights into the pathogenesis of mastocytosis: emerging concepts in diagnosis and therapy. *Annu Rev Pathol*. 2023;18(1):361-386.
- Pardanani A. Systemic mastocytosis in adults: 2021 update on diagnosis, risk stratification and management. *Am J Hematol*. 2021;96(4):508-525.
- Valent P, Orazi A, Savona MR, et al. Proposed diagnostic criteria for classical chronic myelomonocytic leukemia (CMML). *CMML Variants and Pre-CMML Conditions*. Vol 104. Haematologica. Ferrata Storti Foundation; 2019:1935-1949.
- Verstovsek S. Advanced systemic mastocytosis: the impact of KIT mutations in diagnosis, treatment, and progression. *Eur J Haematol*. 2013;90:89-98.
- Reiter A, George TI, Gotlib J. New Developments in Diagnosis, Prognostication, and Treatment of Advanced Systemic Mastocytosis [Internet]. 2020. Available from: <http://ashpublications.org/blood/article-pdf/135/16/1365/1724162/blood.bld.201900932c.pdf>
- Sotlar K, Colak S, Bache A, et al. Variable presence of *KIT*<sup>D816V</sup> in clonal haematological non-mast cell lineage diseases associated with systemic mastocytosis (SM-AHNMD). *J Pathol*. 2010;220(5):586-595.
- Gallogly MM, Lazarus HM, Cooper BW. Midostaurin: a novel therapeutic agent for patients with FLT3-mutated acute myeloid leukemia and systemic mastocytosis. *Ther Adv Hematol*. 2017;8(9):245-261.
- Khoury JD, Solary E, Abla O, et al. The 5th edition of the World Health Organization Classification of Haematolymphoid Tumours: Myeloid and Histiocytic/Dendritic Neoplasms. *Leukemia*. 2022;36(7):1703-1719.
- Ni ZF, Ma LJ, Shi LL, Shen PL, Zhao JQ. Clinical characteristics of acute myeloid leukemia patients with RUNX1 gene mutation. *Zhongguo Shi Yan Xue Ye Xue Za Zhi*. 2021;29(5):1411-1416.
- Dinardo CD, Pratz K, Pullarkat V, et al. Venetoclax Combined with Decitabine or Azacitidine in Treatment-Naive, Elderly Patients with Acute Myeloid Leukemia [Internet]. 2019 Available from: [www.abbvie.com/our-science/clinical-trials/clinical-trials-data-and](http://www.abbvie.com/our-science/clinical-trials/clinical-trials-data-and)
- Gotlib J, Pardanani A, Akin C, et al. Perspectives International Working Group-Myeloproliferative Neoplasms Research and Treatment (IWG-MRT) & European Competence Network on Mastocytosis (ECNM) Consensus Response Criteria in Advanced Systemic Mastocytosis. 2013 Available from: <http://ashpublications.org/blood/article-pdf/121/13/2393/1364345/2393.pdf>
- Hiddemann W, Kreuzmann H, Straif K, et al. High-dose cytosine arabinoside and mitoxantrone: a highly effective regimen in refractory acute myeloid leukemia. *Blood*. 1987 Mar;69(3):744-749.
- Jaglal MV, Duong VH, Bello CM, et al. Cladribine, cytarabine, filgrastim, and mitoxantrone (CLAG-M) compared to standard induction in acute myeloid leukemia from myelodysplastic syndrome after azanucleoside failure. *Leuk Res*. 2014;38(4):443-446.
- Zhou A, Han Q, Song H, Zi J, Ma J, Ge Z. Efficacy and toxicity of cladribine for the treatment of refractory acute myeloid leukemia: a meta-analysis. *Drug Des Devel Ther*. 2019;13:1867-1878.
- Marlies E, Van H. Cladribine in the treatment of systemic mastocytosis, a review of the literature. *Int J Rare Dis Disord*. 2019;2(1):1-5.
- Jawhar M, Döhner K, Kreil S, et al. KIT D816 mutated/CBF-negative acute myeloid leukemia: a poor-risk subtype associated with systemic mastocytosis. *Leukemia*. 2019;33(5):1124-1134.
- Pourhassan H, Kim Y, Pullarkat V. Clearance of bone marrow mast cells after hypomethylating agent and venetoclax for systemic mastocytosis associated with myeloid neoplasia. *Eur J Haematol [Internet]*. 2022;<https://onlinelibrary.wiley.com/doi/10.1111/ejh.13894>;110:213-216.
- Atieh T, Woodroof J, Yacoub A. Venetoclax and decitabine show robust activity in advanced systemic mastocytosis. *Blood*. 2020;136(Supplement 1):25-26.
- DiNardo CD, Jonas BA, Pullarkat V, et al. Azacitidine and venetoclax in previously untreated acute myeloid leukemia. *N Engl J Med*. 2020;383(7):617-629.
- DeAngelo DJ, George TI, Linder A, et al. Efficacy and safety of midostaurin in patients with advanced systemic mastocytosis: 10-year median follow-up of a phase II trial. *Leukemia*. 2018;32(2):470-478.
- Canioni D, Moraly J, Lhermitte L, et al. BCL-2 is expressed in advanced mastocytosis and midostaurin induces venetoclax sensitivity of mast leukemia cell lines. *Blood*. 2019;133(Supplement\_1):1683.
- Zhrebker L, Cooper B, Krause JR. Systemic mastocytosis with associated acute myelogenous leukemia. *Bayl Univ Med Cent Proc*. 2014;27(1):22-24.
- Xu P, Zhang C, Wang Y, et al. Increased number of mast cells in the bone marrow of chronic myeloid leukemia may herald the pending myeloid transformation—the mast cell is an indicator of myeloid transformation. *Transl Cancer Res*. 2019;8(5):2121-2129.
- Mehtani D, Puri N. Steering mast cells or their mediators as a prospective novel therapeutic approach for the treatment of hematological malignancies. *Front Oncol*. 2021;24:11.
- Megías-Vericat JE, Martínez-Cuadrón D, Sanz MÁ, Montesinos P. Salvage regimens using conventional chemotherapy agents for relapsed/refractory adult AML patients: a systematic literature review. *Ann Hematol*. 2018;97(7):1115-1153.
- Kornblau SM, Gandhi V, Andreeff HM, et al. Clinical and laboratory studies of 2-chlorodeoxyadenosine +/- cytosine arabinoside for relapsed or refractory acute myelogenous leukemia in adults. *Leukemia*. 1996 Oct;10(10):1563-1569.
- Dhillon S. Avapritinib: first approval. *Drugs*. 2020;80(4):433-439.

**How to cite this article:** Fazio M, Vetro C, Markovic U, et al. A case of high-risk AML in a patient with advanced systemic mastocytosis. *Clin Case Rep*. 2023;11:e7134. doi:[10.1002/ccr3.7134](https://doi.org/10.1002/ccr3.7134)