

Giant appendix as result of chronic appendicitis : report of a case

E. Pulvirenti, A. Toro, I. Di Carlo

Department of Surgical Sciences, Organ Transplantation and Advanced Technologies, University of Catania, Catania, Italy.

To the Editor,

During operations, surgeons often find a wide range of appendix sizes in patients with varying body dimension (1). The appendix length of male patients is longer than those of females with a mean of 7.5 cm and 6.5 cm respectively¹. Anyway, it is rare that the appendix matches the caecum and ascending colon in length, and, even if some appendices of more than 22 cm in length are described in literature, the only works available are too old or based on non-scientific references (2).

At admission, the patient showed leukocytosis (white blood cell count $> 15 \times 10^3/\text{mL}$; normal range $4.10-10.90 \times 10^3/\text{mL}$) with 90% neutrophils associated with fever $> 38^\circ\text{C}$ and severe pain localized at the right lower quadrant. Because of the progressive pain, he finally agreed to surgery. The open surgical procedure, performed the day after admission, showed a giant appendix (13 cm long, 7 cm in diameter ; Fig. 1, 1-2), which was resected using a staple (Fig. 1, 3). Histopathologic analysis revealed a chronic appendicitis with remarkable thickening of the appendiceal walls (Fig. 1, 4). The

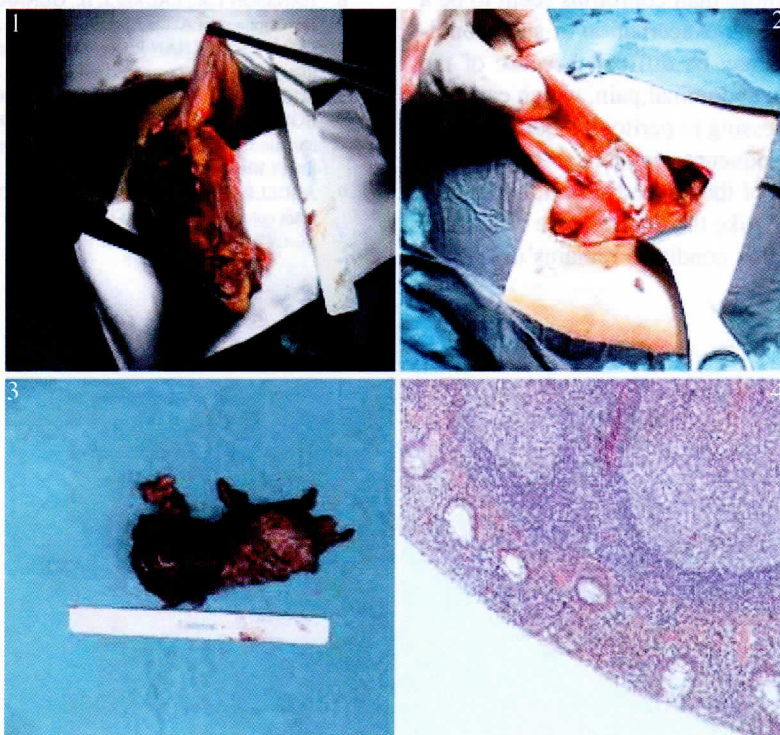


Fig. 1 — **1** : Appendix of 13 cm long and 7 cm of diameter ; **2** : The appendix origin from the caecum ; **3** : The resected appendix ; **4** : Histology showing a chronic appendicitis (haematoxylin & eosin, 10 \times).

A 21-y-old man had a 2-y history of episodic right lower quadrant abdominal pain. Although the diagnosis of acute appendicitis was made several times, the patient always refused surgery and was treated each time with antibiotic therapy, which was effective and allowed his discharge from the hospital. However, the last episode was particularly painful, inducing him to appear at the emergency department.

Correspondence to : Isidoro Di Carlo, MD, PhD, FACS, Associate Professor of Surgery, Department of Surgical Sciences, Organ Transplantation and Advanced Technologies, University of Catania, Cannizzaro Hospital, Via Messina 829, 95126 Catania, Italy. Tel. : +39 095 7264863. Fax : +39 095 7263020. E-mail : idicarlo@unict.it

Submission date : 27/04/2010
Acceptance date : 26/05/2010

patient had no postoperative complications and was discharged 6 d after surgery in good general condition.

The acute inflammation of the appendix is a common event of which the incidence in Europe and America is stable, being about 100 per 100,000 person-years (3) and occurring most commonly in the second and third decades of life. Although during the last 11 years there has been an increasing trend in using radiologic investigation for the diagnosis of the appendicitis (4), this can be reached in 90% of the cases through a careful anamnesis, physical examination and measurement of white cell count and C-reactive protein (5). The time between the appearance of symptoms and the surgery is the predominant factor determining the incidence of complicated appendicitis and the patient delay in presentation is not influenced by age or gender (6).

Whether the acute appendicitis is a well-defined entity, it is more difficult to reach a shared definition of recurrent appendicitis, which could be intended as the exacerbation of right iliac fossa pain in a patient with a history of a similar pain, leading to appendectomy and with the complete resolution of symptoms after the operation (7). Coprostasis more than coproliths seem to be a contributing factor to acute exacerbation of such condition (8) and diagnosis may be difficult because of the long history of episodic abdominal pain, which can mislead the surgeon, progressing to peritonitis quite rapidly.

An uncommon consequence we want to highlight is the possible thickening of the appendix wall, up to generate a "giant appendix" like the one we have described. The exact etiology of this condition remains unknown.

However, it is possible to theorize that the same conditions responsible of development of giant colonic diverticula play a role also in this situation: a unidirectional flap valve mechanism allowing bowel gas and debris to enter but not to leave the appendicular lumen or distension by gas-forming micro-organisms (9). Finally, also the delay in treatment, with recurrent episodes of inflammation treated only with antibiotic therapy, should be considered as a possible cause of development of such condition.

References

1. RASCHKA S., RASCHKA C. On the relationship between body dimensions and appendix length. *Anthropol. Anz.*, 2008, **66** : 67-72.
2. COYNE J.D. Lengthy appendices. *J. Clin. Pathol.*, 2007, **60** : 584.
3. OHMANN C., FRANKE C., KRAEMER M., YANG Q. Status report on epidemiology of acute appendicitis. *Chirurg.*, 2002, **73** : 769-76.
4. WONG K.K., CHEUNG T.W., TAM P.K. Diagnosing acute appendicitis: are we overusing radiologic investigations? *J. Pediatr. Surg.*, 2008, **43** : 2239-41.
5. SENGUPTA A., BAX G., PATERSON-BROWN S. White cell count and C-reactive protein measurement in patients with possible appendicitis. *Ann. R. Coll. Surg. Engl.*, 2009, **91** : 113-5.
6. HANSSON L.E., LAURELL H., GUNNARSSON U. Impact of Time in the Development of Acute Appendicitis. *Dig. Surg.*, 2008, **25** : 394-399.
7. CHANG S.K., CHAN P. Recurrent appendicitis as a cause of recurrent right iliac fossa pain. *Singapore Med. J.*, 2004, **45** : 6-8.
8. SGOURAKIS G., SOTIROPOULOS G.C., MOLMENTI E.P., EIBL C., BONTICIOUS S., MOEGE J., BERCHTOLD C. Are acute exacerbations of chronic inflammatory appendicitis triggered by coprostasis and/or coproliths? *World J. Gastroenterol.*, 2008, **14** : 3179-82.
9. ABDELRAZEQ A.S., OWAIS A.E., ALDOORI M.I., BOTTERILL I.D. A giant colonic diverticulum presenting as a 'phantom mass': a case report. *J. Med. Case Reports*, 2009, **27** : 3-29.