



Contents lists available at ScienceDirect

International Journal of Surgery Case Reports

journal homepage: www.casereports.com

Synchronous hepatic metastasis and metachronous Krukenberg tumor from advanced colon cancer. A case report with an unexpected disease-free survival



Giovanni Li Destri^{a,*}, Lidia Puzzo^a, Alessia Erika Russo^b, Francesco Ferrau^b, Antonio Di Cataldo^a, Stefano Puleo^a

^a University of Catania, Department of "Medical and Surgical Sciences and Advanced Technology G.F. Ingrassia"- Via Santa Sofia 86, 95123 Catania Italy

^b St. Vincent Hospital, Division of Medical Oncology, Contrada Sirina, 98039 Taormina, Messina, Italy

ARTICLE INFO

Article history:

Received 13 October 2016

Received in revised form

21 November 2016

Accepted 21 November 2016

Available online 23 November 2016

Keywords:

Advanced colorectal cancer

Hepatic metastasis

Krukenberg tumor

Disease free survival

Prognostic indexes

Case report

ABSTRACT

BACKGROUND: In the international literature we have never found a long survival in patients treated for a colon cancer with synchronous hepatic metastases and for a metachronous Krukenberg tumor.

PRESENTATION OF CASE: A 46-year old woman for an advanced colon cancer with a synchronous hepatic metastases was subjected to a left hemicolectomy and a resection of liver segment V (R0 resection; T4N2bM1; stage IVa according AJCC 2010). After one year a CT of the abdomen revealed an expansive formation of the left ovary. The patient was subjected to a bilateral ovariectomy, hysterectomy and hiperthermic intraperitoneal chemotherapy (HIPEC). The patient, after several cycles of adjuvant chemotherapy, is disease-free 13 years after surgery.

DISCUSSION: To our knowledge, in the literature there do not appear to be cases of such disease-free survival. The survival of patient despite the prognostic indexes is discussed. The authors discuss the importance of an adequate surgical treatment especially for liver metastases simultaneously treated to colon cancer. The authors also focus on chemotherapy (FOLFOX and then FOLFIRI) performed in a pre-biological era. Furthermore, the degree to which the HIPEC may have had an impact is still unknown, although it seems to be the gold standard for the treatment of the microscopic peritoneal neoplastic remnant.

CONCLUSION: The authors emphasize that the long term survival in colon cancer with hepatic and ovarian metastases is possible as long as it has an adequate surgical approach, a tailored chemotherapy and an intensive follow-up. Most likely new prognostic markers will have to be identified.

© 2016 The Author(s). Published by Elsevier Ltd on behalf of IJS Publishing Group Ltd. This is an open access article under the CC BY-NC-ND license (<http://creativecommons.org/licenses/by-nc-nd/4.0/>).

1. Introduction

About half of the patients diagnosed with colorectal cancer eventually become carriers of liver metastases; approximately 25% of such cases turn out to be synchronous [1]. The incidence of ovarian metastases (Krukenberg tumor), however, is not as precise. In fact, in literature, the gap ranges from 1.2% and 30.8%, with synchronous metastases (1.3–10%) being more prevalent than those metachronous (1.3–2.4%) [2,3].

We report the case of a patient treated, in an academic institution, with radical surgery for advanced cancer of the sigmoid colon and synchronous liver metastases, who subsequently developed bilateral ovarian metastases. To our knowledge, and after a careful review the literature, there do not appear to be cases of a such disease-free survival (DFS) (13 years).

* Corresponding author at: A.O.U. Policlinico – OVE; Via Santa Sofia 86; 95123 Catania, Italy.

E-mail addresses: g.lidestri@unict.it (G. Li Destri), lipuzzo@unict.it (L. Puzzo), alessierikarusso@hotmail.it (A.E. Russo), ferrau@oncologiataormina.it (F. Ferrau), dicalaldao@tiscali.it (A. Di Cataldo), spuleo@unict.it (S. Puleo).

<http://dx.doi.org/10.1016/j.ijscr.2016.11.044>

2210-2612/© 2016 The Author(s). Published by Elsevier Ltd on behalf of IJS Publishing Group Ltd. This is an open access article under the CC BY-NC-ND license (<http://creativecommons.org/licenses/by-nc-nd/4.0/>).

2. Presentation of case

A pre-menopausal 46-year old woman. In August of 2003 (Fig. 1), following the onset of constipation, a colonoscopy showed a stenotic cancer of the sigmoid. An abdominal Computed Tomography (CT) showed a hepatic metastases on the V segment with a maximum diameter of 6.5 cm. Laboratory tests revealed the level of serum carcinoembryonic antigen (CEA) to be 1.3 ng/ml (n.v. : 0–5 ng/ml). The patient was subjected, by the head of the department, to a left hemicolectomy, a resection of liver segment V, and cholecystectomy and appendectomy. The procedure involved a resection of a portion of the right ovary, site of a cystic neoplasm.

The histological diagnosis showed a colon adenocarcinoma, moderately differentiated, with liver metastases, pT3pN2 (8/13) M1R0, stage IVa according to AJCC 2010; the margins of the colon and liver resection, and the portion of the right ovary were free from cancer.

The patient was subjected to chemotherapy treatment with a FOLFOX-4 regimen for 6 months.

Throughout the intensive follow-up [4] there was no relapse; the CEA continues to remain within normal limits.

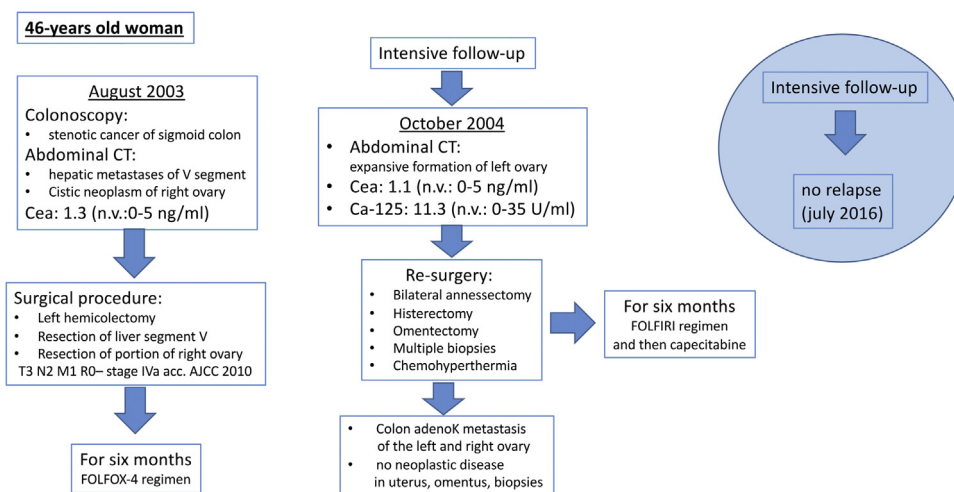


Fig. 1. Timeline.

In October 2004, a CT of the abdomen revealed an expansive formation in the pelvic area of 6 cm in diameter near the left ovary. The patient reported having missed her last menstrual cycle. Laboratory tests revealed values within the normal range of CEA (1.1–n.v.: 0–5 ng/ml) and Ca-125 (11.3– n.v.: 0–35 U/ml).

The patient was subjected to a new surgical procedure involving the removal of both a tumefaction of about 10 cm that had replaced the left ovary, for which an intra-operative histological examination was required, and the right ovary remnant, which appeared macroscopically intact, and of the uterus and omentum. No macroscopic tumor remnant in the abdominal cavity was observed; however, peritoneal biopsies were performed at the liver scar, site of the previous hepatectomy, at the right and left paracolic gutter and at the right and left hemidiaphragm.

The patient was subjected to hyperthermic intraoperative peritoneal chemotherapy (HIPEC) with carboplatin (500 mg).

In the intraoperative histological examination, a diagnosis of moderately differentiated adenocarcinoma was made; as to whether it was primary or metastatic was unclear. The final histology exam showed a metastasis of the left ovary resulting from intestinal-type adenocarcinoma of the colon, as well as in the remaining section of the right ovary; there was no evidence of neoplastic disease in the uterus, omentum, and liver tissue nor in diaphragmatic biopsies and paracolic gutters.

The immunophenotyping allowed for a diagnosis of colon adenocarcinoma metastases, rather than of primary ovarian adenocarcinoma. Cytokeratin 20 positivity, expressed by the epithelium of gastrointestinal type (Fig. 2), and Cytokeratin 7 negativity (Fig. 3), shown instead by serous and mucinous carcinoma of ovarian origin, confirmed the diagnosis of the localization in the ovaries of colon adenocarcinoma.

The patient was subjected to further chemotherapy with a FOLFIRI regimen for six months, and then to maintenance therapy with capecitabine (last administration in June 2006).

The most recent follow-up (July 2016) revealed no relapse.

This paper is in line with the SCARE criteria [5].

3. Discussion

About 20% of patients with colorectal cancer presented at diagnosis with distant metastases (stage IV) which only in 10–20% of cases are resectable. It is not easy to determine the survival of these patients also because the TNM classification divides stage IV patients in only two subgroups (IVA and IVB) regardless of the various prognostic factors [6].

Without question, problems related to secondary liver or ovarian cancer from colorectal cancer are widely debated in literature. It is quite rare, however, to discuss matters related to the radical treatment of the two diseases in a single clinical case.

Surgical treatment of liver metastases from colorectal cancer still remains the only essential therapeutic option [1,7]. For synchronous liver metastases, if the initial approach is of a sequential type (colon-rectum and then liver) the following approach was instead that of performing simultaneous surgery.

In the procedure that we performed, we combined a minor hepatectomy with the left hemicolectomy so as to quickly attack an “oligometastatic” cancer, located only in the liver and thus less likely to be aggressive, and to avoid possible further disseminations from the liver itself [8].

As opposed to the prognosis for a metachronous metastasis, the prognosis for a synchronous metastasis is considered worse. The most widely used prognostic score is Fong’s score [9], which is based on 5 pre-operatively universally determinable markers (the number of metastases, the size of the largest one, the preoperative CEA, the status of the lymph node of the primary tumor, and the DFS between the primary tumor and onset of liver metastases). Our patient would have been at Fong’s score 2 which suggests a 5-year survival of 40%.

To this prognostic assessment, it must be added that the value of CEA had always been within normal limits, thus suggesting an inferior promotion of tumor cell adhesion to host cells, a factor that is presumably responsible for greater aggressiveness of the tumor [7].

The exact timing of chemotherapy treatment still remains uncertain today; recently 2 interesting meta-analyses of randomized clinical trials [10,11] have been published in which patients with a colorectal tumor with synchronous resectable liver metastases were treated with perioperative chemotherapy (neoadjuvant and/or adjuvant) with an improvement statistically significant in terms of progression-free survival or disease-free survival. Unfortunately, both studies did not demonstrate an improvement in overall survival. Our patient after a surgical R0 colic and hepatic resection was undergoing a FOLFOX adjuvant therapy. This treatment was carried out in 2004 in the pre-biological era.

Neoplastic cells of colorectal origin are quite known to attack the ovaries, so much so that they are commonly referred to as a “sanctuary site” [2].

There is agreement on the need to perform a bilateral resection of the adnexa even when facing only a monolateral macroscopically visible localization; in fact, in 50–80% of cases, both ovaries

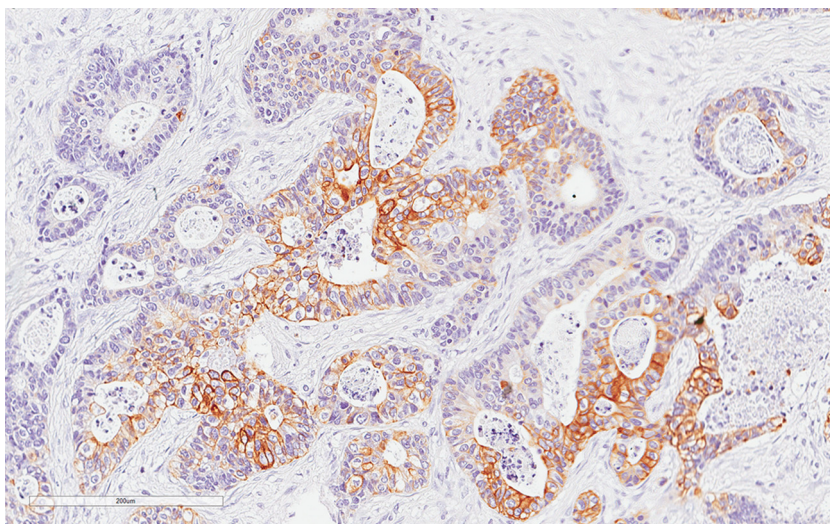


Fig. 2. Positive CK20 in intestinal-type glands (20x).

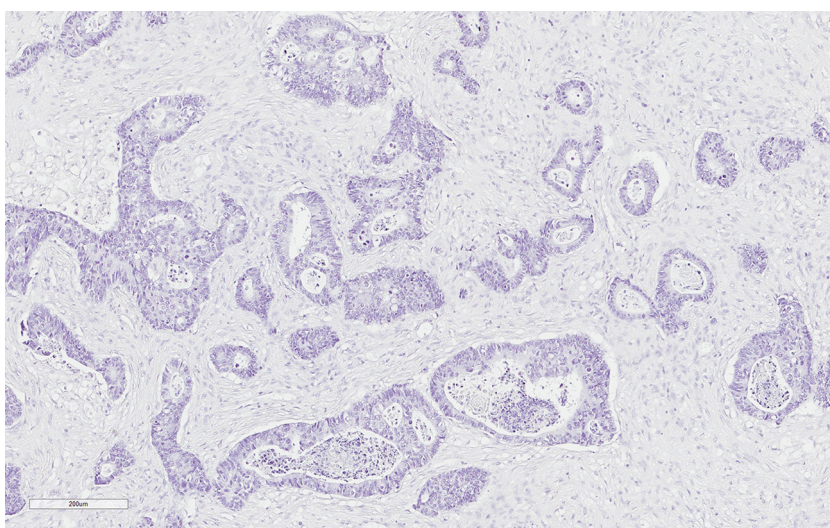


Fig. 3. Negative CK7 in intestinal-type glands (20x).

will be involved [15]. In our case the recurrence burdened by the right ovary, macroscopically intact, was completely unexpected and brought with it an additional unfavorable prognostic factor [2].

As to a new chemotherapy regimen, the choice obviously depends on several factors, among which are the type of chemotherapy previously carried out, the tolerability and toxicity of new treatment and, last but not least, the disease-free interval which, in our case, came to an end only eight months after the adjuvant treatment was completed, thus suggesting that the disease had become considerably aggressive. For this reason we opted for the FOLFIRI regimen, followed by a maintenance treatment with capecitabine. In the OPTIMOX2 study, the maintenance therapy with leucovorin/5-FU had a positive impact on DFS compared with discontinuation of chemotherapy. Capecitabine has been chosen as maintenance therapy strategy because of its favorable safety profile compared with 5-FU [13].

Worth remembering is the fact that today the use of target-oriented drugs, has been shown to increase the results of chemotherapy; therefore, it seems even more surprising that our patient, despite not having undergone a chemo-biological combination, is long surviving with a significant disease-free interval. This shows us that every patient responds at the end unpredictably to

therapy and that we probably have yet to discover new markers that are both prognostic and predictive.

Furthermore, the degree to which the HIPEC may have had an impact is not completely clear even if it is established that its best action occurs when the surgical resection has not left peritoneal disease larger than 1 mm. In the case of patients with colorectal cancer, it is on the verge of becoming the standard of care when there is evidence of metastasis peritoneal or there is a high risk of developing them; a major proportion of at-risk population (>33%) includes patients with ovarian metastases [14] as in the case described.

Almost all authors can agree on the fact that the prognosis of a colorectal cancer with ovarian metastasis is certainly poor [2,12,15]. While Tan [15] does not report disease free at the end of his follow-up, Sakakura [16], in his personal experience, and Kiyokawa [3], in a review of case studies, report the longest survival of 8 and 7 years respectively.

From a careful review of the literature we could only record two clinical cases treated with radical surgery, both reported in Eastern literature (only in Japanese), of a colon cancer with metastasis presented at first in the liver, synchronous in one case [17] and metachronous in the other [18], and subsequently in the ovary. Among these, only Kobayashi [18] reports a DFS of 36 months.

In conclusion, we believe that in colorectal cancer patients with hepatic and ovarian metastases healing is possible; in our case we think it was decisive to have been able to perform the best and most correct surgical approach and a prolonged and tailored chemotherapy treatment. The possibility of proper treatment is certainly dependent on an intensive follow-up, as we usually do [4], without which the surgical possibilities would be nullified. Finally, we believe that new prognostic markers in patients with stage IV should be identified.

Author contribution

Giovanni Li Destri: case report design, data collection, review of the literature concerning the surgical data, drafting the article.

Lidia Puzzo: acquisition of histological data; review of the literature concerning the corresponding histological data; contribution in drafting the manuscript.

Alessia Erika Russo: acquisition of oncological data; review of the literature concerning the corresponding oncological data, contribution in drafting the manuscript.

Francesco Ferraiù: acquisition of oncological data; review of the literature concerning the corresponding oncological data; critical revision of article

Antonio Di Cataldo: acquisition of oncological data; analysis and interpretation of data; review of the literature concerning the corresponding surgical data.

Stefano Puleo: critical revision of article for important intellectual content, final approval of the revision to be published.

Only from University of Catania. This research did not receive any specific grant from funding agencies in the public, commercial, or not-for-profit sectors.

Ethics committee approval was not required for this case report.

Consent

Informed consent was obtained from the patient for the publication of this case report and accompanying images.

Conflicts of interest

All authors declare no conflict of interest.

Registration of research studies

The manuscript does not report the result of an experimental investigation or research on human subjects.

Guarantor

Giovanni Li Destri is the Guarantor. He accepts full responsibility for the work, has access to the data, and controlled the decision to publish.

References

- [1] S.P. McKenzie, H.D. Vargas, B.M. Evers, D.L. Davenport, Selection criteria for combined resection of synchronous colorectal cancer hepatic metastases: a cautionary note, *Int. J. Colorectal Dis.* 29 (2014) 729–735, <http://dx.doi.org/10.1007/s00384-013-1828-0>.

- [2] S.J. Lee, J. Lee, H.Y. Lim, W.K. Kang, C.H. Choi, J.W. Lee, T.J. Kim, B.G. Kim, D.S. Bae, Y.B. Cho, H.C. Kim, S.H. Yun, W.Y. Lee, H.K. Chun, Y.S. Park, Survival benefit from ovarian metastatectomy in colorectal cancer patients with ovarian metastasis: a retrospective analysis, *Cancer Chemother. Pharmacol.* 66 (2010) 229–235, <http://dx.doi.org/10.1007/s00280-009-1150-2>.
- [3] T. Kiyokawa, R.H. Young, R.E. Scully, Krukenberg tumors of the ovary: a clinicopathologic analysis of 120 cases with emphasis on their variable pathologic manifestations, *Am. J. Surg. Pathol.* 30 (2006) 277–299.
- [4] G. Li Destri, A. Di Cataldo, S. Puleo, Colorectal cancer follow-up: useful or useless? *Surg. Oncol.* 15 (2006) 1–12.
- [5] R.A. Agha, A.J. Fowler, A. Saeta, I. Barai, S. Rajmohan, D.P. Orgill, SCARE Group, The SCARE statement: consensus-based surgical case report guidelines, *Int. J. Surg.* 2016 (October (34)) (2016) 180–186, <http://dx.doi.org/10.1016/j.ijsu.2016.08.014>.
- [6] K. Kawai, S. Ishihara, H. Yamaguchi, E. Sunami, J. Kitayama, H. Miyata, K. Sugihara, T. Watanabe, Nomograms for predicting the prognosis of stage IV colorectal cancer after curative resection: a multicenter retrospective study, *Eur. J. Surg. Oncol.* 41 (2015) 457–465, <http://dx.doi.org/10.1016/j.ejso.2015.01.026>.
- [7] J.W. Huh, W.Y. Lee, Y.A. Park, Y.B. Cho, S.H. Yun, H.C. Kim, H.K. Chun, Prognostic factors associated with primary cancer in curatively resected stage IV colorectal cancer, *J. Cancer Res. Clin. Oncol.* 140 (2014) 435–441, <http://dx.doi.org/10.1007/s00432-013-1580-4>.
- [8] R.P. Jones, S. Stättner, P. Sutton, D.F. Dunne, D. McWhirter, S.W. Fenwick, H.Z. Malik, G.J. Poston, Controversies in the oncological management of liver limited stage IV colorectal cancer, *Surg. Oncol.* 23 (2014) 53–60, <http://dx.doi.org/10.1016/j.suronc.2014.02.002>.
- [9] M.W. Kattan, M. Gönen, W.R. Jarnagin, R. DeMatteo, M. D'Angelica, M. Weiser, L.H. Blumgart, Y. Fong, A nomogram for predicting disease-specific survival after hepatic resection for metastatic colorectal cancer, *Ann. Surg.* 247 (2008) 282–287, <http://dx.doi.org/10.1097/SLA.0b013e31815ed67b>.
- [10] D. Ciliberto, U. Prati, L. Roveda, V. Barbieri, N. Staropoli, A. Abbruzzese, M. Caraglia, M. Di Maio, D. Flotta, P. Tassone, P. Tagliaferri, Role of systemic chemotherapy in the management of resected or resectable colorectal liver metastases: a systematic review and meta-analysis of randomized controlled trials, *Oncol. Rep.* 27 (2012) 1849–1856, <http://dx.doi.org/10.3892/or.2012>.
- [11] Z.M. Wang, Y.Y. Chen, F.F. Chen, S.Y. Wang, B. Xiong, Peri-operative chemotherapy for patients with resectable colorectal hepatic metastasis: a meta-analysis, *Eur. J. Surg. Oncol.* 41 (2015) 1197–1203, <http://dx.doi.org/10.1016/j.ejso.2015.05.020>.
- [12] S.M. Vakili, M.2 Sharbatdaran, A.3 Noorbaran, S.2 Siadati, D.4 Moslemi, S.2 Shafahi, A case of colon cancer with breast metastasis and krukenberg tumor, *Int. J. Hematol. Oncol. Stem Cell Res.* 8 (2014) 46–50.
- [13] J. Cassidy, C. Twelves, E. Van Cutsem, P. Hoff, E. Bajetta, M. Boyer, R. Bugat, U. Burger, A. Garin, U. Graeven, J. McKendric, J. Maroun, J. Marshall, B. Osterwalder, G. Pérez-Manga, R. Rosso, P. Rougier, R.L. Schilsky, Capecitabine Colorectal Cancer Study Group, First-line oral capecitabine therapy in metastatic colorectal cancer: a favorable safety profile compared with intravenous 5-fluorouracil/leucovorin, *Ann. Oncol.* 13 (2002) 566–575.
- [14] D. Elias, D. Goéré, F. Dumont, C. Honoré, P. Dartigues, A. Stoclin, D. Malka, V. Boige, M. Ducreux, Role of hyperthermic intraoperative peritoneal chemotherapy in the management of peritoneal metastases, *Eur. J. Cancer* 2014 (50) (2014) 332–340, <http://dx.doi.org/10.1016/j.ejca.2013.09.024>.
- [15] K.L. Tan, W.S. Tan, J.F. Lim, K.W. Eu, Krukenberg tumors of colorectal origin: a dismal outcome—experience of a tertiary center, *Int. J. Colorectal Dis.* 25 (2010) 233–238, <http://dx.doi.org/10.1007/s00384-009-0796-x>.
- [16] C. Sakakura, A. Hagiwara, J. Yamazaki, T. Takagi, K. Hosokawa, K. Shimomura, S. Kin, Y. Nakase, K. Fukuda, H. Yamagishi, Management of postoperative follow-up and surgical treatment for Krukenberg tumor from colorectal cancers, *Hepatogastroenterology* 51 (2004) 1350–1353.
- [17] E. Eto, Y. Ito, K. Mihara, S. Nishiya, S. Shibutani, T. Egawa, S. Hayashi, A. Nagashima, A case of metachronous ovarian metastasis after curative surgery of colon cancer with simultaneous hepatic metastasis, *Gan To. Kagaku Ryoho* 40 (2013) 1927–1929.
- [18] H. Kobayashi, H. Uetake, S. Iida, T. Ishikawa, M. Ishiguro, S. Okazaki, A. Kikuchi, H. Baba, H. Takahashi, N. Iwata, K. Sugihara, Resection for the treatment of bleeding caused by ovarian metastasis after hepatectomy for metachronous liver metastasis from sigmoid colon cancer, *Gan To. Kagaku Ryoho* 40 (2013) 1915–1917.

Open Access

This article is published Open Access at sciendo.com. It is distributed under the [IJSCR Supplemental terms and conditions](#), which permits unrestricted non commercial use, distribution, and reproduction in any medium, provided the original authors and source are credited.