

OPEN

Total Hemi-overgrowth in Pigmentary Mosaicism of the (*Hypomelanosis of*) Ito Type

Eight Case Reports

Vito Pavone, MD, Salvatore Santo Signorelli, MD, Andrea Domenico Praticò, MD,
Giovanni Corsello, MD, Salvatore Savasta, MD, Raffaele Falsaperla, MD, PhD,
Piero Pavone, MD, PhD, Giuseppe Sessa, MD, and Martino Ruggieri BA, MD, PhD

Abstract: Pigmentary mosaicism of the (*hypomelanosis of*) Ito type is an umbrella term, which includes phenotypes characterized by mosaic hypopigmentation in the form of streaks, whorls, patchy, or more bizarre skin configurations (running along the lines of Blaschko): these cutaneous patterns can manifest as an isolated skin disorder (*pigmentary mosaicism of the Ito type*) or as a complex malformation syndrome in association with extracutaneous anomalies (most often of the musculoskeletal and/or nervous systems) (*hypomelanosis of Ito*). Affected individuals are anecdotally reported to have also partial or total body hemi-overgrowth (HOG), which often causes moderate to severe complications.

We studied the occurrence and features of HOG in the 114 children and adults with mosaic pigmentary disorders of the Ito type diagnosed and followed up (from 2 to 22 years; average follow-up 16 years) at our Institutions.

Eight patients (5 M, 3 F; aged 4 to 25 years; median age 16 years) out of the 114 analyzed (7%) fulfilled the criteria for unilateral HOG, with differences in diameter ranging from 0.4 to 4.0 cm (upper limbs) and 1.0 to 9.0 cm (lower limbs). Moreover, among these 8 patients, 5/8 filled in the 75th to 90th percentile for height; 6/8 had associated kyphoscoliosis; and 5/8 showed cognitive delays. No tumour complications were recorded. Overall, 6/8 HOG patients presented with additional

(extracutaneous) syndromic manifestations, apart from the HOG (ie, with a clinical phenotype of *hypomelanosis of Ito*).

The present study, which includes children and adults with the longest follow-up so far recorded, confirms the association between pigmentary mosaicism of the Ito type and HOG lowering previous estimates (7% vs 16%) for HOG in the context of mosaic hypopigmentation. A careful examination, looking at subtle to moderate asymmetries and associated complications within the spectrum of these mosaic pigmentary disorders, is recommended.

(*Medicine* 95(10):e2705)

Abbreviations: HI = hypomelanosis of Ito, HOG = hemi-overgrowth, IP = incontinentia pigmenti, ND = nevus depigmentosus.

INTRODUCTION

Pigmentary mosaicism of the (*hypomelanosis of*) Ito type (still known as *incontinentia pigmenti achromians*; MIM # 300337) is a not uncommon mosaic cutaneous disorder.^{1–8} The abnormal skin patterning is characterized by hypopigmentation in the form of whorls, streaks, or patches that may be unilateral or bilateral.^{5–8} The hypopigmented streaks and whorls are irregularly shaped and of variable size, following the lines of Blaschko (arranged in *narrow bands*, according to the archetypical patterns of cutaneous mosaicism),^{7,9,10} and running parallel to one another. The body areas, which tend to be affected by hypopigmentation, are the trunk and the limbs; in the latter sites, such manifestations tend to assume a linear shape (for this reason the condition is also known as “*linear hypomelanosis in narrow bands*”).^{9,10} Scalp, palms, soles, or mucous membranes are usually spared. The disorder affects both the sexes, occurs in all races, and is (so far regarded as) sporadic.^{5,7,8}

The skin patterns may appear as an isolated skin disorder (a pure cutaneous trait) (*pigmentary mosaicism* or linear hypomelanosis [*of the Ito type*])^{2–4,7} or as a complex malformation syndrome in association with extracutaneous manifestations,^{5,6,8} including central nervous system or musculoskeletal alterations (*hypomelanosis of Ito* [HI]).^{5,6,8,11–16} More rarely, the eyes, heart, and genital organs can also be involved.^{5,11–13,15}

With regards to body asymmetry, the term “*hemi-hyperplasia*” is applied when a pathological growth is linked to an abnormal proliferation of cells, and the term “*hemi-hypertrophy*” is used when an abnormal growth is caused by an increase in the size of existing cells.¹⁷ In the absence of histologic evaluation, the terms “*overgrowth*” or “*abnormal growth*” are the most suitable. The association between pigmentary mosaicism of the Ito type and asymmetric overgrowth (hemi-overgrowth [HOG]) has

Editor: Giovanni Li Volti.

Received: September 23, 2015; revised: January 7, 2016; accepted: January 14, 2016.

From the Department of Orthopaedics, AOU “Policlinico-Vittorio Emanuele,” (VP, GS); Department of Clinical and Experimental Medicine, University of Catania, (SSS); Department of Biomedical and Biotechnological Sciences (ADP); Department of Clinical and Experimental Medicine, Section of Pediatrics and Child Neuropsychiatry, University of Catania, Catania (ADP, MR); Department of Sciences for Health Promotion and Mother and Child Health Care, Pediatric Unit, University of Palermo, Palermo, (GC); Department of Pediatrics, IRCCS Hospital San Matteo, University of Pavia, Pavia (SS); and Unit of Paediatrics and Emergency Paediatrics, AOU “Policlinico-Vittorio Emanuele,” (RF, PP) Catania, Italy.

Correspondence: Piero Pavone, Unit of Pediatrics, Unit of Paediatrics and Emergency Paediatrics, AOU “Policlinico-Vittorio Emanuele,” Via Plebiscito, 626, 95124 Catania, Italy (E-mail: ppavone@unict.it).

Authors’ contribution: VP and ADP wrote the first and subsequent drafts of manuscript; they followed up the HOG patients; SSS performed the angiographic evaluations; PP, RF, SS, and MR followed up the patients with pigmentary mosaicism and reviewed the literature; and GC and MR revised the paper.

The authors have no funding and conflicts of interest to disclose.

Copyright © 2016 Wolters Kluwer Health, Inc. All rights reserved.

This is an open access article distributed under the Creative Commons Attribution-NonCommercial License, where it is permissible to download, share and reproduce the work in any medium, provided it is properly cited. The work cannot be used commercially.

ISSN: 0025-7974

DOI: 10.1097/MD.0000000000002705

been previously anecdotally reported, but no systematic studies were undertaken.

The aim of this retrospective study is to report the personal experience in individuals with a combination of pigmentary mosaicism of the Ito type and HOG seen at our Institutions, and to review the existing literature on this topic. The updated treatment recommendation and the risk of tumour complications in these HOG patients are also discussed.

METHODS

Population Studied

Between April 1992 and December 2014, 114 individuals with pigmentary mosaic skin manifestations of the Ito type (ie, with hypopigmented skin patterns running along the lines of Blaschko)^{7,9,10} were referred to the Section of Pediatrics and Child Neuropsychiatry (formerly, Department of Pediatrics and Child Neurology) of the University of Catania, Italy, which caters to children/adolescents with neurological disorders. This University Section also holds a longstanding tradition (ie, since the 90s) of adult referrals affected or suspected of having neurocutaneous disorders, and for these reasons it caters to adults with mosaic pigmentary patterns associated or not to systemic abnormalities.

The local ethics committee of the University Hospital “Policlinico Vittorio-Emanuele” of Catania, approved the study. An informed consent on the present study was given to 8 of the selected patients affected by HI and HOG.

Demographic Data

At the time of the present study, the 114 included patients were children (n = 80) or adults (n = 34). Of the 80 children, 49 were boys (aged 2–18 years, average age 12 years) and 31 were girls (aged 18 months to 17 years, average age 11 6/12 years). Of the 34 adults, 20 were males (aged 18–65 years, average age 44 years) and 14 were females (aged 22–59 years, average age 37 years). Overall, the study included 69 males and 45 females (male-to-female ratio = 1.5).

Antenatal Findings

There was no apparent consanguinity between the 114 probands' parents or between the probands and/or other family members belonging to the various families. Seventy-six per cent of patients were born after an uncomplicated pregnancy; in the remaining 24%, mothers had experienced minor complications in their pregnancies, including remitting hepatitis, metrorrhagia, hypertension, anaemia, and depression. Eighteen patients were born at less than 38 weeks' gestation, whereas 2 had a birth weight of less than 2500 g.

Cutaneous Patterns

All patients had, at the time of their first referral, mosaic skin hypopigmentation in the form of whorls, streaks, patches, or arranged as S or V-shaped patterns following the lines of Blaschko,^{7,9,10} anywhere in the body, including, in order of frequency, legs, arms, trunk, and (less frequently) face. The skin abnormalities were most often (ie, 88%) arranged in mixed patterns including combinations of linear streaks (in the arms and/or legs) and whorls (in the abdomen); the S and V-shaped were recorded less frequently (ie, 33%). The skin lesions first manifested before the first year of life and their natural history were characterized by a constant increase of hypopigmentation within the lesions until the age of 5 to 6 years, with relatively

stable patterns at or around puberty, with later (postpubertal) decrease of hypopigmentation. The patterns were, however, visible in all adult patients and over the entire follow-up period in children.

Extracutaneous Patterns

The mosaic skin phenotypes, in the forms and patterns reported above, were associated with extracutaneous abnormalities, including musculoskeletal (n = 55), neurological (n = 30), and combined musculoskeletal and neurological (n = 29) abnormalities; 32/114 had, in addition, minor eye abnormalities and major or minor dysmorphic features (mostly [ie, 87%] falling in the group of combined extracutaneous abnormalities).

Diagnostic Workup

The patients' follow-up spanned from 2 to 22 years; average follow-up was 16 years. The initial (or early middle) diagnostic work-up included in all the 114 probands' general dermatological, and general and neurological examination, routine laboratory tests, full ophthalmologic evaluation and heart, and abdominal and pelvic ultrasound examination. When dictated by the clinical findings, we obtained radiographs and other additional laboratory studies; magnetic resonance imaging (MRI) studies of the brain were obtained in all the 114 patients at different ages.

Hemi-overgrowth

Among these 114 patients, HOG was recognized as a clinical discrepancy in length (>0.5 cm) and diameter (>1 cm) of the lower and (>0.4 cm) upper limbs. From an epidemiological viewpoint, we compared findings in the HOG subgroup versus findings in the overall group of 114 patients with pigmentary mosaicism and in the syndromic group of HI patients; a comparison between the HOG subgroup and the normal pediatric population was beyond the aims of the present study.

Genetic Studies

All the 114 patients were studied by standard cytogenetic analysis (ie, karyotype). In those with extracutaneous anomalies, we later, during the diagnostic work-up and follow-up, completed the study by array-Comparative Genomic Hybridization (CGH) analysis. Genomic DNA was extracted from peripheral blood cells collected from the triad composed by father, mother, and proband; the probands' sisters and brothers were added to the triads when necessary. DNA extraction was performed by using the NucleoSpin Blood kit (Macherey-Nagel, Duren, Germany). Commercially available DNA matched for sex was used as the reference DNA (Promega, Madison, WI). The genomic and reference DNA were hybridized according to the manufacturer's instructions (Technogenetics, Milan, Italy). Array-CGH was performed using an oligonucleotide-based microarray consisting of 60,000 oligonucleotides spaced at a density of 41 kb over the full genome (8x60k chip, Agilent Technologies, Santa Clara, CA) and carried out at an average resolution of 100 kb on extracted genomic DNA.

RESULTS

Eight out of the 114 patients analyzed (7.01%) showed a combination of cutaneous pigmentary mosaicism of the Ito type with HOG. No specific anomalies could be recorded in the

patients analyzed by means of genetic analysis (ie, karyotype and CGH-array). Herein, a short summary of the clinical and laboratory findings in these 8 patients is reported.

Case Reports

Patient 1 was a 4-year-old male who first came to our observation at the age of 3 years, due to episodes of febrile seizures. The parents and the youngest sister were healthy and did not show cutaneous anomalies. He was born by Caesarean section with a birth weight of 3100 g. Psychomotor development was regular. At his first physical examination, he weighed 17 kg, with a height of 101 cm and a head circumference of 51 cm (all within the 50th percentile). The hypopigmented lesions, in the form of whorls, were localized on the upper side of the right trunk and showed a linear pattern in the right lower limb. Limbs were asymmetrical: the asymmetry involved the right lower limb, which was larger than the left of 1 cm in diameter, and of 0.5 cm in the right upper limb compared with its counterpart, the right lower limb was 1 cm longer than the left. No facial asymmetry was present. Apart from the hemibody asymmetry, the patient did not show other anomalies. Neither cognitive delay nor spine anomalies were present. The right femoral bone age was 1 year older than the left side. No skin biopsy to check for genetic mosaicism was carried out.

Patient 2, a 6-year-old girl, was the first born to healthy parents (both parents did not have cutaneous anomalies). The asymmetry was first noticed at birth. Psychomotor development was within normal ranges. At physical examination, she weighed 24 kg (90th percentile), with a height of 115 cm (50th percentile) and a head circumference of 49 cm (50th percentile). The hypopigmented patterns, in the form of whorls and V-shaped arrangements, were more evident in the trunk and in the back, with a linear configuration in the right lower limb. The diameter of the right lower limb was 1 cm larger than the lower left limb; the difference in the upper limb was less pronounced (0.4 cm). The right lower limb was 0.8 cm longer than the left. No hemiface involvement, cognitive delay, epilepsy, or spine anomalies had been recorded. The right femoral bone age was advanced of 1 year compared with the left.

Patient 3, a 10-year-old boy, was born by normal delivery. His parents did not show cutaneous anomalies. He was admitted for consultation due to episodes of generalized tonic-clonic seizures lasting several minutes: seizures had started at age 2 years. He showed neurodevelopmental delay from his first months of life: his current school performance is poor. An electroencephalographic (EEG) examination revealed spike and wave discharges in the temporal and parietal regions. Treatment with sodium valproate substantially reduced the frequency of seizures. At physical examination, he weighed 34 kg, with a height of 141 cm (75th percentile). The hypopigmented lesions were localized in the thorax and in the back, mainly on the left side. The diameter of the sural region of the lower left limb was 8 cm larger than the contralateral, and the diameter of the biceps region of the left limb was 3 cm larger than the contralateral. The left lower limb was 2 cm longer than the right. The asymmetry involved also the left hemiface. A lower-limb MRI showed increased growth in both long bones and soft tissues. Mild thoracolumbar right kyphoscoliosis was noticed. Brain MRI and ophthalmologic examination were both normal.

Patient 4, a 15-year-old girl, was the only daughter of nonconsanguineous parents. Both her parents were healthy with no cutaneous anomalies. The girl was born at 40 weeks by normal delivery, with a birthweight of 3300 g, a height of 50 cm, and a

head circumference of 35 cm. She first came to our observation at the age of 2 years, due to psychomotor delay. The parents noticed the presence of cutaneous spots at about 3 months of age. Since her first year of life, the girl showed mild body asymmetry. At physical examination, at age 2 years, the girl showed typical hypopigmented lesions along the lines of Blaschko, mainly in the trunk and the upper and lower limbs (particularly evident over the right part of the body). During these years, the girl manifested moderate cognitive delay, poor school performance, and generalized tonic-clonic seizures, with a frequency of 6 to 8 episodes per year despite valproate treatment. At the age of 6 years, clobazam was added to the valproate regimen and the frequency of seizures decreased. An EEG revealed generalized spike and wave discharges. Currently, her physical examination reveals a weight of 70 kg and a height of 174 cm (both falling in the 90th percentile). Her school performance remained poor. The diameter of the biceps region of the right limb was 3 cm larger than the contralateral. Her right thigh diameter was 66 cm and her left thigh diameter was 57 cm (Figure 1): the sural right lower limb diameter was 43 cm, compared with the left, which measured 40 cm. The right lower limb length was 103 cm, whereas the left was 100 cm. Facial asymmetry was also present, but to a milder degree. She currently walks with unstable equilibrium with frequent falls down. A color Doppler ultrasound examination of her limbs showed normal laminar flow, with a wider diameter of the arteries in the affected right limb (Figure 2 A and B). Brain MRI was normal as her ophthalmological examination. Spinal x-ray examination revealed mild left kyphoscoliosis. Skin biopsy was not performed.

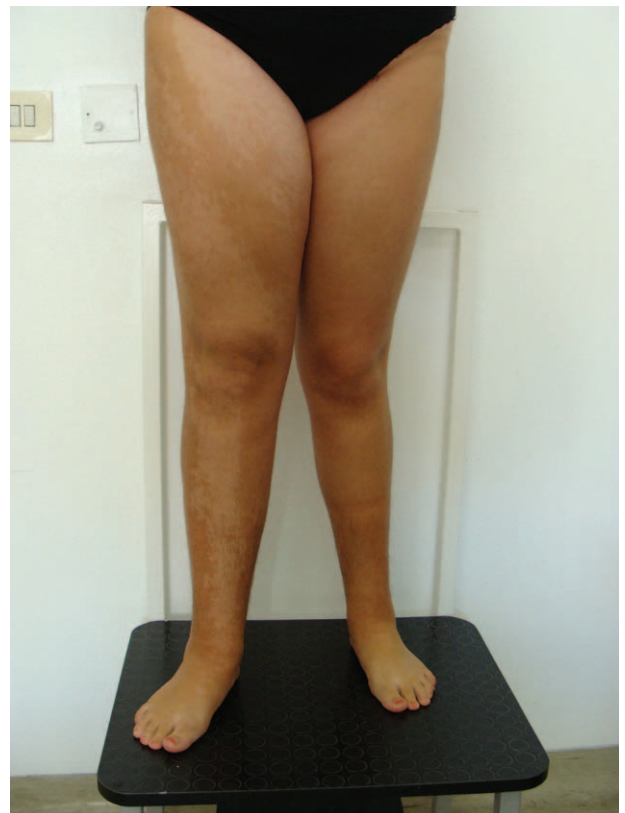

FIGURE 1. Patient 4 at age 15 years: note the right lower limb overgrowth in the affected limb with hypopigmentation.

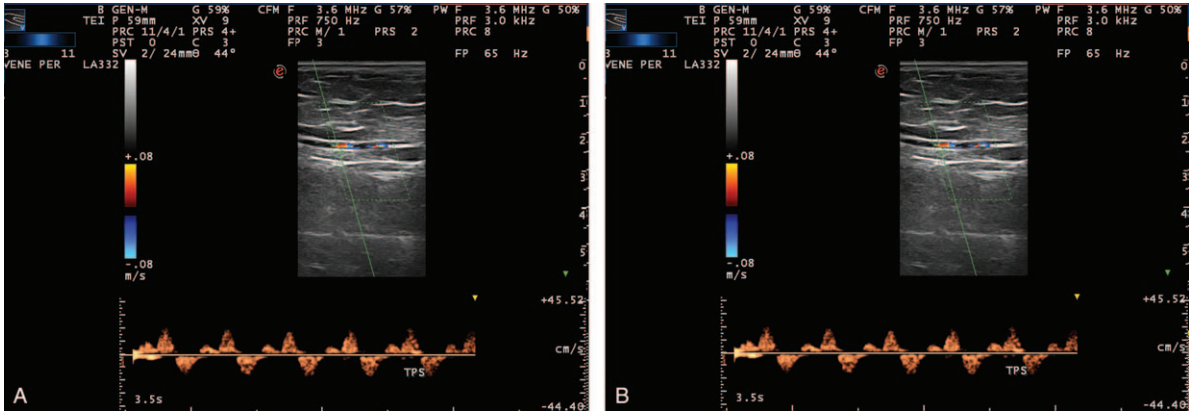


FIGURE 2. Patient 4 at age 15 years: color Doppler ultrasound examination of the right lower leg showing (A) normal laminar flow; and (B) larger diameter of the right limb vessels.

Patient 5 was a 18-year-old female who first came to our observation at the age of 24 months due to language delay. Her psychomotor development was also delayed. Convergent strabismus was present, with no anomalies at fundoscopy. Mild dysmorphic features were present, including epicanthic folds and hypotelorism. Physical examination revealed that her height was 175 cm (in the 90th percentile). The hypopigmented lesions were widely diffused in the trunk, particularly on the right side. The right upper limb diameter was 4 cm larger than the left side, and the right lower limb diameter was 7 cm larger and 3 cm longer than the left. Also, the right hemiface was involved by the disturbed growth. EEG and brain MRI were unrevealing. Left kyphoscoliosis was recorded with 10 to 15 degree of Cobb scale.

Patient 6, a 20-year-old male with no noticeable familial cutaneous anomalies, was first referred for a diagnostic work-up regarding his cutaneous manifestations, which were diffuse, as patches, and primarily found on his left side. He had been first referred at age 3 years due to his severe psychomotor delay and for generalized tonic-clonic seizures. The EEG, at that age, revealed spike and wave discharges, prevalent in the frontal regions. Moderate cognitive delay was present. At his most recent physical examination, his stature was 175 cm (50th percentile): his left upper limb was 3 cm larger than the right, and the left lower limb 6 cm larger than the right. The left lower limb was 2.5 cm longer than the right. The ears were bilaterally large and cupped with an enlargement of the left hemiface. Mild right kyphoscoliosis was recorded. Brain MRI was normal. Skin biopsy was not performed.

Patient 7, a 22-year-old male, had no family history of cutaneous lesions. At physical examination, his height was 182 cm (75th percentile). The hypopigmented lesions were widely diffused over the trunk and with greater prevalence on the right side (Figure 3). Left upper limb diameter was 2.5 cm larger than the right, whereas left lower limb diameter was 6 cm larger. The difference in the lower limb length was 4 cm (left > right). Right hemiface was importantly involved. Cognitive delay was present. An EEG revealed generalized spike and wave discharges, and the patient experiences epileptic seizures of the generalized tonic-clonic type. Fundus examination was normal. Convergent strabismus was noticed. Short and broad nose, macrocrania, and left kyphoscoliosis (20 degree of Cobb) were also recorded. Brain MRI was normal.

Patient 8, a 25-year-old male, had no family history of cutaneous anomalies. His cutaneous anomalies were localized

over the trunk and the limbs, particularly on the right (Figure 4). The stature was 181 cm (75th percentile). The right upper limb diameter was 2 cm larger as compared with the left; the right lower limb diameter was 4 cm larger. Lower limb length discrepancy was 5 cm (the right side was longer). There was mild involvement of the right hemiface. Left kyphoscoliosis was present (20 degree of Cobb). The man attended school with good scores. No seizures had been recorded.

DISCUSSION

Pigmentary mosaicism along the lines of Blaschko (*of the Ito type*) still represents a challenging disorder for clinicians and a controversial issue in the medical literature. Even though Ito, in his original report,¹⁸ described the skin anomaly as a purely cutaneous trait, subsequent case reports and case series expanded both the *skin phenotype* including scalp abnormalities, unilateral or bilateral curly hair, and conical teeth,¹⁻⁸ and the *systemic phenotype* reporting extracutaneous abnormalities (mostly of the musculoskeletal and nervous systems).^{5,6,8,11-16}

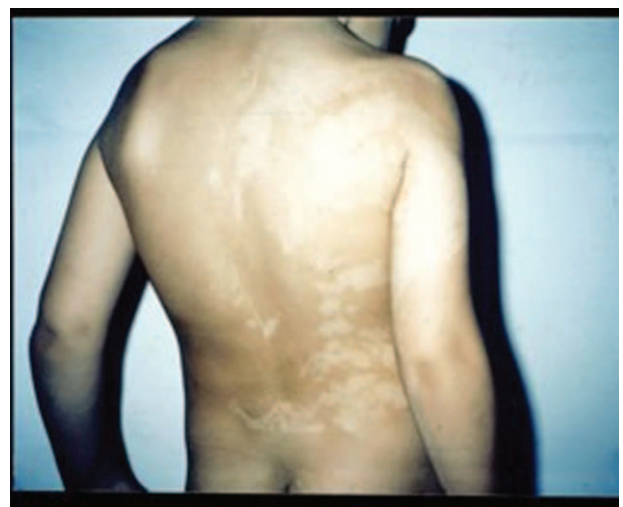

FIGURE 3. Patient 7 at age 10 years: note the hypopigmented patches in the right area of the back and the ipsilateral kyphoscoliosis.

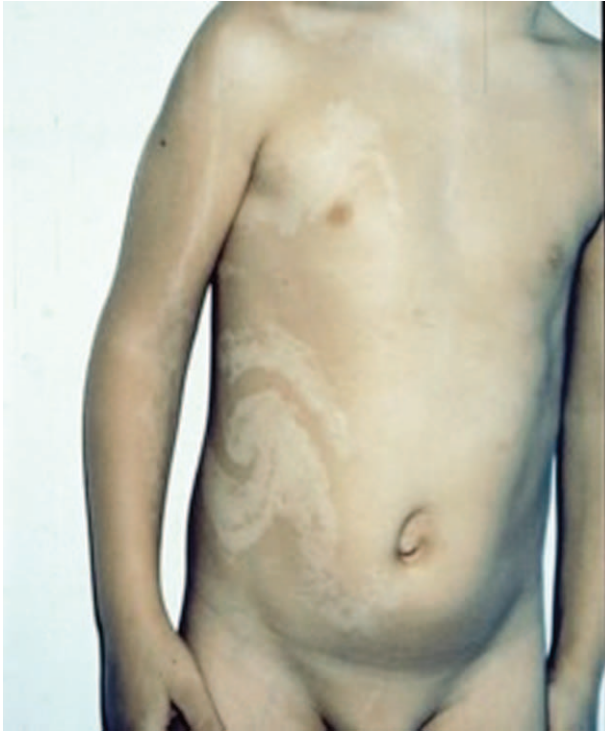

FIGURE 4. Patient 8 at age 9 years: note the hypopigmented whorls over the right side of the thorax and the abdomen and the linear hypopigmentation in the right arm.

The differential diagnosis comprises (other) disorders with hypopigmentation following the lines of Blaschko,^{6–8} and thus include the atrophic/hypopigmented (fourth) stage manifestations of *incontinentia pigmenti* (IP) of the Bloch-Sulzberger type (MIM # 308310) (as stated above, pigmentary mosaicism along the lines of Blaschko is still categorized in the OMIM database as “*incontinentia pigmenti achromians*”, ie, as the hypopigmented counterpart—achromians—of *incontinentia pigmenti*); *focal dermal hypoplasia* or Goltz Syndrome (MIM # 305600); and the systemic form of *nevus depigmentosus* (ND).^{6,10} In the present patients, the diagnosis of IP was excluded since the hypopigmented lesions, which usually appear on the extremities, are preceded by a progressive (multi-stage) pattern of cutaneous lesions (ie, erythematous/vescicobullous [stage 1], pustular/verrucous [stage 2], and hyperpigmented [stage 3]). Goltz syndrome diagnosis was excluded by the absence of other cutaneous findings, such as linear areas of telangiectasias, hyperpigmentation and dermal atrophy, and focal alopecia and nail dystrophy: these signs were not present in our patients. The systemic form of ND in its unilateral form may be difficult to differentiate from pigmentary mosaicism, but it is usually not associated with systemic manifestations.

Regarding the likely role of pigmentary genes in the occurrence of mosaic phenomena of hypopigmentation (along the lines of Blaschko) either as isolated traits or as syndromic patterns, Taibjee et al¹⁹ reported several ranges of mosaic chromosomal abnormalities, including diploidy, triploidy, aneuploidy, chromosomal deletions, insertions, and translocations (of basically all chromosomes) in about 50% of affected individuals with hypopigmentation along the lines of Blaschko: cross-comparison of these cytogenetic abnormalities and one or

more pigmentary genes showed significant (ie, >70%) overlaps. The claimed familial occurrence and the number of reported pedigrees inferring Mendelian inheritance in pigmentary mosaicism of the Ito type have not been proven at a clinical level.²⁰ It has been hypothesized that the pigmentary pattern that follows Blaschko's lines is the result of the migration of 2 different clones of cells during embryogenesis, and the clinical findings of pigmentary mosaicism (of the Ito type) is a non-specific manifestation (ie, a phenotype) reflecting genetic mosaicism, which likely disrupts expression or function of pigmentary genes.^{19,21} The pigmentary anomalies are the results of an interaction between 2 different cellular populations as it happens with the mosaicism.^{7,9} The current term of *pigmentary mosaicism* along the lines of Blaschko (or of the *Ito type*) (or *linear hypomelanosis in narrow bands*, according to the system of archetypical patterns of cutaneous mosaicism)^{9,10} thus reflects the anatomical distribution of the abnormal skin patterning over the body and the assumed pathogenesis of the disorder: that is, somatic mosaicism for a yet undiscovered gene or genes responsible for pigmentation in humans.^{5,9} In this respect, we still prefer to reserve^{5,9} the term HI to the syndromic phenotype (likely reflecting early embryonic occurrence of mosaicism), which comprises skin and (various) extracutaneous manifestations including dysmorphic signs, neurodevelopmental delay, seizures, cerebral malformations, (a wide spectrum of) musculoskeletal abnormalities, eye and other systemic anomalies, and the term pigmentary mosaicism along the lines of Blaschko (or of the Ito type) to the pure cutaneous trait (likely reflecting late occurrence during embryogenesis of mosaic phenomena), which can be encountered in the general population. Whatever phenotype one faces, the cutaneous manifestations are typically recorded since birth (or they may be noticed in the first months of life, usually after the first tanning), and tend to grow in the first years of life. Histopathological examination of the affected (hypopigmented) cutaneous area shows a reduction in melanin with a normal or decreased number of melanocytes versus a normal complexion in the unaffected areas. Notably, no specific anomalies could be recorded in the 114 patients analyzed by means of genetic analysis: as previously reported, the genetic substrate for these mosaic phenomena could be heterogeneous and only partially understood.^{7,19–21}

Hemi-overgrowth clinically refers to asymmetry of the body to a greater degree than can be attributed to normal variation, and it may affect 1 or more body parts (ie, it may involve the entire hemi-body, or just a single arm, the trunk, the abdomen, and external genitalia with or without visceral involvement).^{22–24} The degree of asymmetry is variable, and the most subtle cases may pass unnoticed. Radiographic studies show that the overgrowth affects both the long bones and the soft tissues to the same degree, with advanced ossification.^{25,26}

Total HOG is congenital and it may be noticeable right after birth. It can occur on either side, but in our patients, it was more frequent on the right side. Total HOG frequently manifests as long arms and in the trunk. A difference in posture and gait may call attention to total HOG, even if the difference in length is moderate. Pigmented nevi of different type and shape such as nevus pilosus, nevus unius lateralis, and telangiectasias may be noticed in the affected skin, or more rarely in the contralateral part. As with the HI patients, cognitive delay is present in approximately 25% of HOG patients. Asymmetry of the chest and pelvis and limping are also reported.^{23–25} The spine frequently shows scoliosis as the result of the asymmetry of the pelvis. Skeletal malformations are also reported, including

polydactyly, syndactyly, and other types of finger and toe anomalies. Partial or total HOG has been observed in many well-known syndromes such as Wiedemann–Beckwith, Klippel–Trenaunay–Weber, Proteus, Epidermal Nevus, Maffucci, Silver–Russel, and osteochondromatosis.^{22–25}

The present patients showed typical cutaneous manifestations reflecting pigmentary mosaicism of the Ito type, which were easily recordable in the first years of life. They had, at the time of their first referrals, mosaic skin hypopigmentation in the form of whorls, streaks, patches, or S or V-shaped patterns following the lines of Blaschko. These were present anywhere in the body including legs, arms, trunk, and (less frequently) face (in order of frequency). The skin abnormalities were most often arranged in mixed patterns including a combination of linear streaks (in the arms and/or legs) and whorls (in the abdomen), and less frequently S and V-shaped. These lesions were characterized by a constant increase of hypopigmentation within the lesions until the age of 5 to 6 years of age, with relatively stable patterns around puberty, and later (postpuberty) decrease in lesions. We did not record consanguinity between the probands' parents or between the probands and/or other family members. Notably, in the present case series, 4/8 patients showed generalized tonic-clonic seizures. Seizures have been widely reported in the setting of patients with pigmentary mosaicism of the Ito type or (more often) in HI.^{5,6,8,11–16,26–28} As previously reported,^{11,15,26,28,29} the spectrum of epileptic seizures present with heterogeneous semiology, ranging from generalized seizures well controlled by antiepileptic drugs to severe (most often partial, myoclonic or atonic) epileptic syndromes which are often drug-resistant. Interestingly, most HOG patients fell into the syndromic mosaic pigmentary phenotype (ie, HI).

We recorded a preponderance of right hemi-body lesions (in 6/8 HOG patients), with skin lesions widely diffused over almost the entire body, thus reflecting a more severe overall phenotype. In addition to that, the hypopigmented lesions were more evident in the area affected by HOG, again reflecting a more severe phenotype. Overall, the asymmetry was milder in the 2 youngest patients (patients 1 and 2), whereas in the remaining 6, the difference in diameter ranged from 4 to 9 cm in the lower limbs, and there was a diameter difference of 2 to 4 cm in the upper limbs. The difference in length of the lower limbs ranged from 2 to 5 cm. This could reflect a mild to moderate progression of disturbed growth throughout puberty and adolescence. This gradual progression with age did not cause troubles for daily functioning, with the exception of the patients with kyphoscoliosis. Two out of the 8 patients lacked involvement of face. Six out of the 8 patients had associated extracutaneous abnormalities that affected the musculoskeletal (eg, kyphoscoliosis) and nervous systems (eg, cognitive delay and epilepsy) and the eye (ie, convergent strabismus). Thus, the syndromic phenotype (ie, HI) was most often associated with HOG, reflecting the severity of the overall phenotype. Of note, 3 out of the 8 patients also had mild facial dysmorphisms. None of the patients presented with clinical and radiological signs of tumors.

The association between pigmentary mosaicism of the Ito type and total body HOG has been anecdotally reported in single case reports or within larger series of HI patients. Pascual-Castroviejo et al¹¹ recorded 4 HOG patients out of the 34 HI patients analyzed. Glover et al¹² reported an association between HI and HOG in 4 out of the 19 patients; they also recorded similar findings in 8 out of the 66 patients reviewed in the literature. Ruiz-Maldonado et al¹³ reported no cases of HOG

in a large series of 41 HI patients. In a later series of 76 infantile cases of HI, Pascual-Castroviejo et al¹⁵ reported the presence of facial, trunk, or member asymmetry in 12 patients (16%).

Six out of 8 patients showed a thoraco-lumbar kyphoscoliosis that resulted from pelvic asymmetry. These patients were treated with busts and physical rehabilitation to compensate for the difference in length, and all patients showed mild improvement. Surgical treatment of HOG is not advisable, except in cases of wide and disturbing asymmetry. Gärtner and Sabo²⁹ through a combination of intertrochanteric shortening osteotomy and triple osteotomy have surgically corrected HOG with coexistent dysplasia of the hip. Surgery options for limb overgrowth depend on the differences in length: for differences less than 2 cm, an orthopedic insole is generally used; if the difference ranges from 2 to 4 cm, then the longer arm may be surgically shortened; and if the difference is more than 4 cm, the shorter arm may be lengthened. In adult age, the shorter arm is generally lengthened and the deformities are corrected by external fixation.

Hemi-hypergrowth patients are at risk for tumor complications, primarily intra-abdominal tumors and especially Wilms tumors.^{30,31} A prospective multicenter clinical study of 168 children affected by isolated overgrowth attempted to evaluate the incidence and nature of neoplastic complications. A total of 10 tumors developed in 9 patients, with an incidence rate of 5.9%.³⁰ A lower incidence of neoplasms (1.2%) was reported by Dempsey-Robertson et al³¹ in 1 of the 10 patients—a child affected by Beckwith–Wiedeman syndrome, developed a hepatoblastoma, and 3 out of 250 children with isolated idiopathic overgrowth developed an abdominal neoplasm. Furthermore, 1 patient presented with adrenal carcinoma and 2 with Wilms tumor. None of the present patients showed signs of tumor complications. Notably, pigmentary mosaicism of the Ito type and HI are not associated with an increased risk of tumour.³²

In the present patients, the hypomelanotic lesions were recognized in early childhood, and the asymmetry of the body was identified (most often) during subsequent surveys for the diagnostic work-up or follow-up of the cutaneous anomalies. Parents confirmed that the asymmetry had remained unnoticed for some time.

The patients in this study suggest that the association between pigmentary mosaicism of the Ito type and HI with HOG is not uncommon. When mosaic hypopigmentation along the lines of Blaschko and HOG are both present, physicians should carefully monitor these conditions, as severe complications may manifest.

REFERENCES

1. Unsigned editorial: Hypomelanosis of Ito. *Lancet*. 1992;339:651–652.
2. Sybert VP. Hypomelanosis of Ito: a description, not a diagnosis. *J Invest Dermatol*. 1994;103:141S–143S.
3. Happle R. Incontinentia pigmenti versus hypomelanosis of Ito: the whys and wherefores of a confusing issue. *Am J Med Genet*. 1998;79:64–65.
4. Küster W, König A. Hypomelanosis of Ito: no entity, but a cutaneous sign of mosaicism. *Am J Med Genet*. 1999;85:346–350.
5. Ruggieri M, Pavone L. Hypomelanosis of Ito: clinical syndrome or just phenotype? *J Child Neurol*. 2000;15:635–644.
6. Pascual-Castroviejo I, Ruggieri M. Hypomelanosis of Ito and related disorders (pigmentary mosaicism). In: Ruggieri M, Pascual-Castroviejo I, Di Rocco C, eds. *Neurocutaneous disorders: Phakomatoses and Hamartoneoplastic Syndromes*. New York-Wien: Springer Verlag; 2008:363–385.

7. Happle R, Nevi. In: Happle R, ed. *Mosaicism in Human Skin. Understanding Nevi, Nevoid Skin Disorders, and Cutaneous Neoplasia*. Berlin/Heidelberg: Springer-Verlag; 2014:69–108.
8. Ruggieri M, Praticò AD. Mosaic neurocutaneous phenotypes and their cause. *Semin Pediatr Neurol*. 2015;22:207–233.
9. Happle R. Mosaicism in human skin. Understanding the patterns and mechanisms. *Arch Dermatol*. 1993;129:1460–1470.
10. Happle R. Pigmentary patterns associated with human mosaicism: a proposed classification. *Eur J Dermatol*. 1993;3:170–174.
11. Pascual-Castroviejo I, López-Rodríguez L, de la Cruz Medina M, et al. Hypomelanosis of Ito. Neurological complications in 34 cases. *Canad J Neurol Sci*. 1988;15:124–129.
12. Glover MT, Brett EM, Atherton DJ. Hypomelanosis of Ito: spectrum of the disease. *J Pediatr*. 1989;115:75–80.
13. Ruiz-Maldonado R, Toussaint S, Tamayo L, et al. Hypomelanosis of Ito: diagnostic criteria and report of 41 cases. *Pediatr Dermatol*. 1992;9:1–10.
14. Nehal KS, Pe Benito R, Orlow SJ. Analysis of 54 cases of hypopigmentation and hyperpigmentation along the lines of Blaschko. *Arch Dermatol*. 1996;132:1167–1170.
15. Pascual-Castroviejo I, Roche C, Martínez-Bermejo A, et al. Hypomelanosis of ITO. A study of 76 infantile cases. *Brain Dev*. 1998;20:36–43.
16. Cohen J 3rd, Shahrokh K, Cohen B. Analysis of 36 cases of Blaschkoid dyspigmentation: reading between the lines of Blaschko. *Pediatr Dermatol*. 2014;31:471–476.
17. Cohen MM Jr. A comprehensive and critical assessment of overgrowth and overgrowth syndromes. *Adv Hum Genet*. 1989;18:181–303373-376.
18. Ito M. Studies on melanin. XI. Incontinentia pigmenti achromians. A singular Case of nevus depigmentosus systematicus bilateralis. *Tohoku J Exp Med. (Suppl 55)*:1952:57–59.
19. Taibjee SM, Bennett DC, Moss C. Abnormal pigmentation in hypomelanosis of Ito and pigmentary mosaicism: the role of pigmentary genes. *Br J Dermatol*. 2004;151:269–282.
20. Ruggieri M. Familial hypomelanosis of Ito: implications for genetic counseling. *Am J Med Genet*. 2000;95:82–84.
21. Hatchwell E. Hypomelanosis of Ito and X; autosome translocations: a unifying hypothesis. *J Med Genet*. 1996;33:177–183.
22. Cohen MM Jr. *The Child With Multiple Birth Defects*, 2nd ed. New York: Oxford University Press; 1997:228.
23. Maratoux P. Essentially disturbed growth. In: Maratoux P, ed. *Bone Disease of Children*. Philadelphia: JB Lippincott Company; 1979: 279–280.
24. Warkany J. Hemidystrophies and hemisyndromes. In: Warkany J, ed. *Congenital Malformations: Notes and Comments*. Chicago: Year Book Medical Publisher; 1971:162–170.
25. Ruggieri M, Tigano G, Mazzone D, et al. Involvement of the white matter in hypomelanosis of Ito (incontinentia pigmenti achromians). *Neurology*. 1996;45:485–492.
26. Ruggieri M, Polizzi A, Pavone L, et al. Thalamic syndrome in children with measles infection and selective, reversible thalamic involvement. *Pediatrics*. 1998;101:112–119.
27. Assogba K, Ferlazzo E, Striano P, et al. Heterogeneous seizure manifestations in Hypomelanosis of Ito: report of four new cases and review of the literature. *Neurol Sci*. 2010;31:9–16.
28. Pavone P, Praticò AD, Ruggieri M, et al. Hypomelanosis of Ito: a round on the frequency and type of epileptic complications. *Neurol Sci*. 2015;36:1173–1180.
29. Gärtner CM, Sabo D. Case report of Ito-syndrome associated with congenital hemihypertrophy from the orthopaedic point of view. *Z Orthop Ihre Grenzgeb*. 2005;143:656–659.
30. Hoyme HE, Seaver LH, Jones KL, et al. Isolated hemi hyperplasia (hemihypertrophy): report of a prospective multi-center study of the incidence of neoplasia and review. *Am J Med Genet*. 1998;79:274–278.
31. Dempsey-Robertson M, Wilkes D, Stall A, et al. Incidence of abdominal tumors in syndromic and idiopathic hemihypertrophy/isolated hemihyperplasia. *J Pediatr Orthop*. 2012;32:322–326.
32. Ruggieri M, Magro G, Polizzi A. Tumours and hypomelanosis of Ito. *Arch Pathol Lab Med*. 2001;125:599–601.