
Occurrence and regional distribution of TRAIL and DR5 on temporomandibular joint discs: comparison of disc derangement with and without reduction

Rosalia Leonardi, DDM, MS,^a Luis Eduardo Almeida, DDS, MS,^b Paula C. Trevilatto, DDS, PhD,^b and Carla Loreto, DM, MS,^c Catania, Italy; and Curitiba, Brazil
UNIVERSITY OF CATANIA AND PONTIFICAL CATHOLIC UNIVERSITY OF PARANÁ

Background. Tumor necrosis factor (TNF)-related apoptosis-inducing ligand (TRAIL) is an apoptosis-inducing member of the TNF gene family which triggers apoptotic signals by interaction with its receptors. It has been suggested to be a major contributing factor to tissue degeneration.

Objective. The present study investigated, through immunohistochemistry, the regional expression of TRAIL and in temporomandibular joint (TMJ) disc of anterior disc displacement with reduction (ADDwR) and without reduction (ADDwoR) patients, to help determine the relationship between TMJ disc displacement and apoptosis.

Study design. We studied 18 TMJ diseased discs affected by disc displacement without or with reduction and 4 normal TMJ discs. Specimens were processed for immunohistochemistry to evaluate TRAIL and its receptor DR5 expression.

Results. Disc tissues from internal derangements (both ADDwR and ADDwoR) exhibited a much higher percentage of TRAIL- and DR5-positive cells as well as stain intensity compared with normal tissue though with regional variation according to the portion of the disc. There was a significantly higher percentage of stained cells in the posterior disc attachment compared with the anterior or intermediate bands of both ADDwR and ADDwoR discs for TRAIL and DR5.

Conclusions. TRAIL and DR5 are overexpressed in displaced human TMJ disc, especially in the posterior disc attachment. These results suggest a possible pivotal role of the TRAIL/DR5 system in TMJ disc degeneration. (**Oral Surg Oral Med Oral Pathol Oral Radiol Endod 2010;109:244-251**)

Internal derangements (IDs) are among the most frequent causes of temporomandibular joint (TMJ) disease.¹⁻³ They represent a disturbance in the normal anatomic relationship between the intra-articular disc and the condyle, resulting in an interference with the smooth movement of the joint. If the disc slips out of place or is displaced, it can prevent the proper movement of the condyle and cause dysfunction. There are 2 common types of internal derangements. The more frequently seen is an anterior disc displacement with reduction (ADDwR), when the disc slides in and out of its normal functional position as the jaw opens or closes, causing a popping sound. In the case of anterior disc displacement without reduction (ADDwoR), the

disc is permanently displaced or dislocated, and the jaw's range of motion is limited.^{2,4} In these instances, it has been speculated that TMJ disc tissue is damaged directly or indirectly by excessive mechanical stress and the disc, in most of these cases, becomes deformed, misshapen, or even torn.⁵⁻⁷ Progress made using cellular and molecular biology techniques has led to increased understanding in the pathogenesis and mechanisms of disc degeneration. However, as far as TMJ disc is concerned, studies have dealt mostly with collagen breakdown and cytokine overexpression.⁸⁻¹¹ These studies have shown that degenerative joint changes are due largely to an imbalance between matrix tissue synthesis and degeneration, probably caused by apoptosis.

In the other joints, nonphysiologic mechanical loading induces disc degeneration through an apoptotic-related process that leads to a diminished generation, organization, and repair of the extracellular matrix. Apoptosis is a physiologic process implicated in various aspects of mammalian development, including embryogenesis, normal tissue turnover, and homeostasis. FasL, tumor necrosis factor (TNF) α , and TNF-related apoptosis-inducing ligand (TRAIL) are common apoptosis-induced factors, known to trigger apoptosis

^aProfessor, Department of Dentistry, University of Catania, Faculty of Dentistry, Policlinico Universitario.

^bCenter for Health and Biological Sciences, Pontifical Catholic University of Paraná.

^cProfessor, Department of Anatomy, Diagnostic Pathology, Forensic Medicine, Hygiene, and Public Health, University of Catania, Italy. Received for publication Jun 13, 2009; returned for revision Sep 16, 2009; accepted for publication Sep 18, 2009.

1079-2104/\$ - see front matter

© 2010 Mosby, Inc. All rights reserved.

doi:10.1016/j.tripleo.2009.09.028

through distinct signal pathways.^{12,13} Recently, a major role of TRAIL and its death receptors (DRs) has been observed in some studies regarding intervertebral disc (IVD) degeneration.^{14,15} TRAIL is an apoptosis-inducing member of the TNF gene family which cross-links 3 receptor molecules on the surface of target cells. To date, 5 human TRAIL receptors have been identified: DR4/TRAIL-R1, DR5/TRAIL-R2/TRICK2, TRID/DcR1/TRAIL-R3, TRAIL-R4/DcR2, and osteoprotegerin TRAIL which triggers apoptotic signals through interaction with DR4 and DR5.¹⁶⁻²⁰

In TMJ disc tissue, one study demonstrated that TRAIL was overexpressed in apoptotic chondrocyte-like cells.²¹ However, it remains unclear how TRAIL and its receptor DR5 are involved in TMJ IDs (with and without disc reduction) and where they are regionally distributed in damaged TMJ disc cells. Therefore, the present investigation was designed to examine, through immunohistochemistry, the regional expression of TRAIL and DR5 in TMJ discs of ADDwR and ADDwoR patients to better understand the relationship between TMJ disc displacement and apoptosis.

MATERIALS AND METHODS

Patients and tissues

Eighteen TMJ displaced disc specimens were collected from consecutive patients treated between 2002 and 2008 at the Pontifical Catholic University of Paraná, Curitiba, Brazil. Four virtually unaffected human TMJ discs, selected from the archives of the Anatomy Institute of Catania University, Italy, were studied along with the pathologic material. After project approval by the ethics committee of the same university, informed consent was obtained from each patient before tissue collection.

The discs (10 from the right TMJ and 8 from the left) were obtained from 14 female and 4 male patients affected by temporomandibular joint IDs (11 patients were affected by ADDwR and 7 by ADDwoR), as confirmed by their clinical history, examination, and magnetic resonance imaging studies (Fig. 1). The mean age of all patients was 34.2 ± 5.4 years (ranging from 24 to 41 years). Clinical characteristics, mean ages, SD, median, and duration of ID before surgery for ADDwR and ADDwoR, were divided into 2 groups according to type of ID. Patients affected by ADDwR had a mean age of 32.7 ± 5.5 years (range 24-41 years), and those with ADDwoR had a mean age 36.5 ± 4.4 years (range 28-41 years). The duration of ID before surgery was 8.9 ± 1.3 months (range 7-10 months) for ADDwR patients and 8.1 ± 06 (range 7-9 months) for ADDwoR patients. Nine patients were caucasian, 6 native American, and 3 African Brazilian. The diagnosis that led to surgery was disc derangement with associated pain and

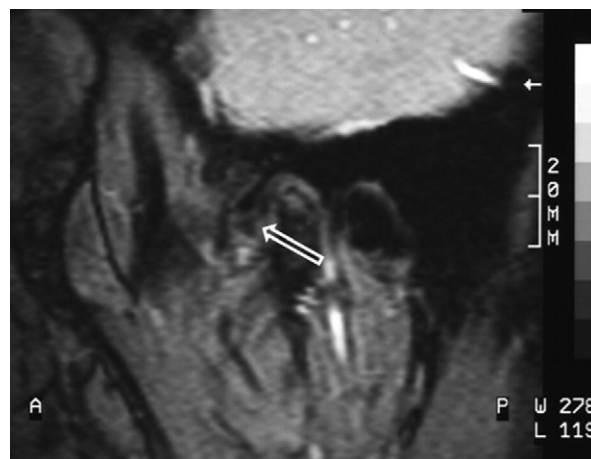


Fig. 1. Magnetic resonance image of a temporomandibular joint disc displacement (arrow) in closed mouth of a patient with anterior disc displacement with reduction. The posterior band appears thinned.

impairment of function. Inclusion criteria were: 1) unsuccessful nonsurgical treatment before surgery; 2) diagnosis of internal derangement of the TMJ; and 3) TMJ pain or interference with mandibular movements. Exclusion criteria were: 1) other TMJ diseases; 2) dentofacial deformity; 3) major jaw trauma; 4) previous TMJ surgery; and 5) previous steroid injections in the TMJ.

All patients' discs surgically removed were macroscopically deformed; none of the discs had a normal biconcave shape. Both patient and autopsy specimens included the anterior band, intermediate band, and the posterior disc attachments.

The 4 autopsy TMJ disc specimens that had been embedded in paraffin were obtained from 1 male and 3 female subjects (mean age 49.7 ± 4.4 years) from the Anatomy Institute of Catania University, Italy. These were selected because: 1) the subjects' clinical history gave no indication of generalized joint diseases or TMJ arthropathy; 2) macroscopic signs of degenerative or inflammatory joint disease were not evident upon dissection; and 3) microscopic examination of sections stained with Harry hematoxylin revealed no pathologic changes.

Immunohistochemistry

The discs were fixed overnight in 10% neutral buffered formalin (Bio-Optica, Milan, Italy). After fixation and overnight washing, each disc was sectioned through its center along a parasagittal plane, perpendicular to its long axis. Each tissue block was dehydrated in graded ethanol and embedded in paraffin, preserving the longitudinal anatomic orientation. Specimens were

sectioned (5 μ m) and placed on silanized glass slides with the anterior band always oriented to the right, for routine hematoxylin staining and subsequent immunohistochemistry. The sections were irradiated (5 minutes \times 3) in capped polypropylene slide holders with citrate buffer (pH 6), using a microwave oven (750 W) to unmask antigenic sites.

Rabbit polyclonal anti-TRAIL (Santa Cruz Biotechnology, Santa Cruz, CA) and anti-DR5 (Novus Biologicals, LLC, Littleton, CO) were used at 1:20 working dilution. Each antibody was applied and sections incubated overnight at 4°C in a humidified chamber. Immunocomplexes were subsequently detected with secondary antibody and then with streptavidin-peroxidase complexes for 15 minutes each at room temperature (LSAB2/HRP kit; Dako, Denmark, A/S Produktionsvej, Glostrup, Denmark). After rinsing with phosphate-buffered saline, sections were exposed to 0.1% 3,3'-diaminobenzidine and 0.02% hydrogen peroxide solution (DAB substrate kit; Vector Laboratories, Burlingame, CA) for 4 minutes. Sections were lightly counterstained with Meyer hematoxylin.

Evaluation of immunohistochemistry

All slides were coded and evaluated without knowledge of the patient's identity, clinical status, and group identification (blinded). Immunostained sections were examined with a light microscopy. Two of the authors (R.L. and C.L.), each with \geq 10 years' experience in immunohistochemistry techniques and TMJ disc tissue microscopic evaluation, performed the assessment of the TMJ disc immunostained sections on a mutual consensus basis, using a double-headed microscope.

Stain intensity and the proportion of immunopositive cells were examined by light microscopy and recorded for both TRAIL and DR5 antibodies. Three different TMJ disc tissue compartments were analyzed: the anterior band (AB), intermediate band (IB), and the posterior disc attachment (PDA). Intensity of staining was graded on a scale of 0-4, according to the following assessment: 0 = no detectable staining; 1 = weak staining; 2 = moderate staining; 3 = strong staining; 4 = very strong staining. The percentage of TRAIL and DR5 immunopositive cells (extent score [ES]) were also independently evaluated and scored as a percentage of the final number of the 200 cells in 4 categories: 0 = \leq 5%; 1 = 6%-30%; 2 = 31%-50%; 3 = \geq 51%; 4 = $>$ 75%. Counting was performed at \times 200 magnification. The final staining score (FSS) was derived from the sum of the intensity score and the ES.

Positive and negative control

Positive and negative controls were performed to test the specific reaction of primary antibodies used in this

study. For positive control testing, sections from gastric cancer tissue were immunohistochemically analyzed.²² Strong positive immunolabeling for TRAIL and DR5 was both membranous and cytoplasmic in these sections. For negative control testing, sections of TMJ displaced discs were randomly drawn from ADDwoR and ADDwR samples. These were then treated with normal rabbit serum instead of the specific antibodies.

Statistical analysis

The data were analyzed using Mann-Whitney *U* tests. *P* values of $<$.05 were considered to be statistically significant. The Mann-Whitney *U* test was used to compare protein expression (TRAIL and DR5) as an FSS among disc specimens. Comparisons were made based on the anatomic region of the disc of the specimens of patients affected by ADDwR or ADDwoR. All data were analyzed with the SPSS program (release 16.0; SPSS, Chicago, IL).

RESULTS

All TMJ patients had been unsuccessfully treated with other various interventions for at least 6 months before surgery. Diseased TMJ disc sections, stained with hematoxylin (routine staining) showed a different severity of morphologic damage, ranging from an altered collagen bundle architecture to fragmentation of the collagen bundles. A change in cell population ratios was also observed. Chondrocyte-like cells increased in prevalence in the severely damaged discs, whereas fibroblast-like cells decreased. However, all in all, a decrease in cellularity was noted in the more damaged discs. In contrast, the control discs showed preservation of multidirectional collagen bundles, predominately fibrocyte-like cell populations with few chondrocyte-like cell aggregates, and absence of clefts and/or fraying.

Immunohistochemical reactivity for TRAIL was detected in the cytoplasm of the TMJ disc cells, and the expression of DR5 was recognized in the cell membrane and cytoplasm. Immunolabeling for TRAIL and DR5 was found in all of the disc sections, but they were expressed in most of the samples with different patterns of reactivity according to the topography and kind of disc displacement. Disc tissues from ID (both ADDwR and ADDwoR) exhibited a much higher percentage of TRAIL- and DR5-positive cells, as well as stain intensity, than the normal tissue, though with regional variation according to the portion of the disc. The FSS was consistently higher for ADDwoR than ADDwR in every portion of the disc, for the sections stained both with TRAIL and with DR5 antibodies.

Table I presents TRAIL and DR5 mean FSS for each portion of the disc (AB, IB, and PDA) and type of ID (ADDwR and ADDwoR). Table II shows TRAIL and

Table I. Final staining score in temporomandibular joint disc of patients with internal derangement (ID). Final staining score (sum of stain intensity and extent score) mean value, standard deviation (SD), median, and standard error (SE) for tumor necrosis factor–related apoptosis-inducing ligand (TRAIL) and its receptor DR5 immunolabeling according to the type of ID

	Mean	SD	Median	SE
TRAIL				
ADDwR				
AB	3	0.77	3	0.23
IB	4	1.18	2	0.35
PDA	6	0.89	5	0.26
ADDwoR				
AB	4	0.81	3	0.30
IB	5	0.81	4	0.30
PDA	7	0.81	6	0.30
DR5				
ADDwR				
AB	3	0.77	3	0.23
IB	3	1.00	3	0.30
PDA	4	1.09	4	0.33
ADDwoR				
AB	3	0.81	3	0.30
IB	4	0.81	4	0.30
PDA	6	1.15	6	0.43

ADDwR, Anterior disc displacement with reduction; ADDwoR, anterior disc displacement without reduction; AB, anterior band; IB, intermediate band; PDA, posterior disc attachment.

DR5 the mean number of stained cells or ES in each region of the disc. Posterior disc attachment (Fig. 2) showed a higher FSS and ES for TRAIL and DR5 both in ADDwR and in ADDwoR discs than the other 2 bands (Fig. 3). Also, the mean number of stained cells (ES) was higher in the PDA than the other 2 regions of the disc both for TRAIL in ADDwR and ADDwoR and for DR5 in ADDwoR. Almost all disc cells of the PDA were strongly immunolabeled by TRAIL antibody both in ADDwR and in ADDwoR discs (Fig. 2). In contrast, the IB demonstrated a moderate to strong staining pattern in some cells (Fig. 3). Highly significant differences ($P < .001$) were obtained when comparing TRAIL FSS between PDA, IB, and AB both for ADDwR and ADDwoR (Table I). PDA showed the highest TRAIL FSS, AB the lowest, and IB a middle value, both for ADDwR and for ADDwoR discs. The DR5 FSS values were generally lower than TRAIL except for the PDA in the ADDwoR (Table I). A moderate to strong staining pattern for DR5 was observed in the disc cells of most cases, PDA showed a higher DR5 FSS than the other 2 portions of the disc, especially in ADDwoR discs (Fig 4). When comparing each portion of the disc with the others, TRAIL showed statistically significant differences both for ADDwR and for ADDwoR. How-

Table II. Extent score in temporomandibular joint disc of patients with internal derangement (ID). Extent score (percentage of immunopositive cells) mean value, standard deviation (SD), median, and standard error (SE), for tumor necrosis factor–related apoptosis-inducing ligand (TRAIL) and its receptor DR5 immunolabeling according to the type of ID

	Descriptive statistic				Mann-Whitney U test
	Mean	SD	Median	SE	
TRAIL					
ADDwR					
AB	35.9	4.8	28	1.44	AB vs. IB *
IB	52.2	5.6	47	1.71	IB vs. PDA ***
PDA	70.8	5.1	64	1.56	PDA vs. AB ***
ADDwoR					
AB	54.1	6.36	44	2.40	AB vs. IB *
IB	55.1	5.52	48	2.08	IB vs. PDA ***
PDA	78.1	2.85	73	1.07	PDA vs. ***
DR5					
ADDwR					
AB	36.7	4.14	29	1.25	AB vs. IB NS
IB	34.3	2.20	31	0.66	IB vs. PDA NS
PDA	40.4	3.36	36	1.01	PDA vs. AB NS
ADDwoR					
AB	39.2	4.30	33	1.62	AB vs. IB *
IB	38.8	3.28	35	1.24	IB vs. PDA *
PDA	61.5	5.96	55	2.25	PDA vs. AB ***

Abbreviations as in Table I.

P values obtained by Mann-Whitney U test on TRAIL and DR5 expressions when comparing the 2 different types of IDs (ADDwR and ADDwoR, respectively) between regions (AB, IB, and PDA):

** $P < .01$;

* $P < .05$;

*** $P < .001$; NS, not significant.

ever, for DR5, only ADDwoR showed significant differences when comparing the 3 areas of the disc, whereas ADDwR did not (Table II).

In control discs, few scattered cells were immunolabeled by TRAIL and DR5. Significant differences between the 3 regions of the disc were not seen in these normal disc specimens ($P > .05$). Although the immunoreaction products for TRAIL and DR5 were few, they were detected in all cell populations (i.e., fibroblast-like cells, fibrochondrocytes, and chondrocyte-like cells) in the PDA, and in chondrocyte-like cells and fibroblast-like cells in the AB and IB.

DISCUSSION

There appears to be a wide consensus regarding the relationship between TMJ disc position and disc degeneration.²³⁻²⁷ It seems that these degenerative changes, just as with other joints, are influenced by the type and degree of disc displacement. The more advanced the internal derangement, the more deteriorated the disc configuration will be.²⁸ However, to date molecular

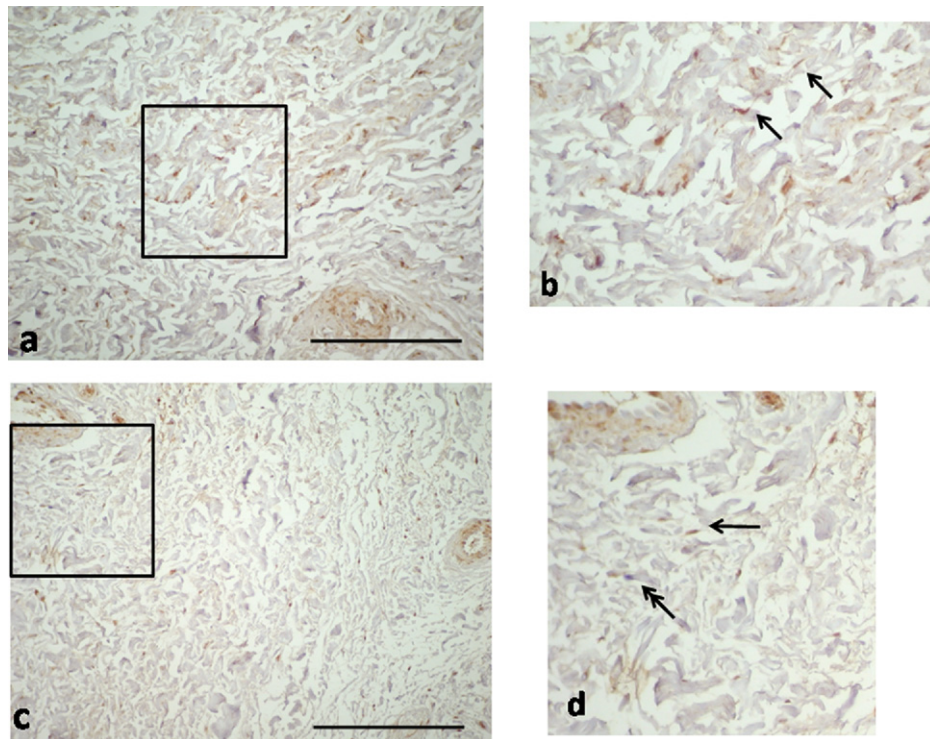


Fig. 2. Immunostaining for tumor necrosis factor-related apoptosis-inducing ligand in the posterior disc attachment. Microphotographs from temporomandibular joint disc of patients affected by disc displacement without reduction (a) and with reduction (c). (b) Magnification of the box of in a. (d) Magnification of the box in c. Arrow = fibroblast; double-headed arrow = immunonegative staining. Bar = 100 μ m.

events that lead to TMJ disc degeneration are still unclear, at least regarding cellularity loss. A series of chemical mediators and cytokines have been reported to play a major role in various TMJ degenerative changes. Among these, TNF- α , a cytokine closely related to TRAIL, has been detected in the synovial fluid and tissue of patients with IDs and has been correlated with osteoarthritis, synovial inflammation, and pain leading to an unsuccessful clinical outcome after TMJ irrigation.²⁹⁻³⁸ Its expression has also been related to apoptosis of chondrocytes in the mandibular condyle. Notwithstanding these studies and the fact that TNF- α represents one of the 3 major apoptosis-inducing factors, no study has extensively addressed its implication in TMJ disc cell apoptosis.

In other joints, such as intervertebral disc (IVD), tissue apoptotic cell death has been suggested as being a major contributing factor of herniated disc tissue degeneration because apoptosis increased with the severity of disc pathologic findings.^{12,15,39-41} Moreover, evidence of a dose-dependent relationship between apoptosis and nonphysiologic mechanical loading in herniated IVD has been provided. Some investigations have shown that the highest amount of cell death in

IVD is observed in those areas mostly affected by disc deformation.^{14,42} Thus, results from these studies suggest a pivotal role for disc displacement leading to induction of cell apoptosis and extracellular matrix degradation, which can lead to IVD degeneration.^{12,41}

Among the 3 major apoptosis-inducing factors that are known to trigger apoptosis through distinct signal pathways, TRAIL and its receptors have gained interest recently in IVD degeneration. Zhang et al.⁴³ reported a stronger expression of DR4 (one of the TRAIL receptors) in all samples of degenerative herniated discs versus normal discs. In addition, DR4 expression at various stages of disc herniation was positively correlated with the degeneration progress. Bertram et al.¹⁴ argued that protein and gene expression of TRAIL and the death receptors DR4 and DR5 correlate with the progression of degeneration in human intervertebral discs.^{14,15} According to their findings, the authors argued that disc cells inherit the molecular machinery to induce IVD apoptosis, and TRAIL/DR4/DR5 axis is an important molecular mediator of apoptosis induction in disc tissue.¹⁴

Findings from the present study demonstrate that TRAIL, a member of the TNF family, and its receptor

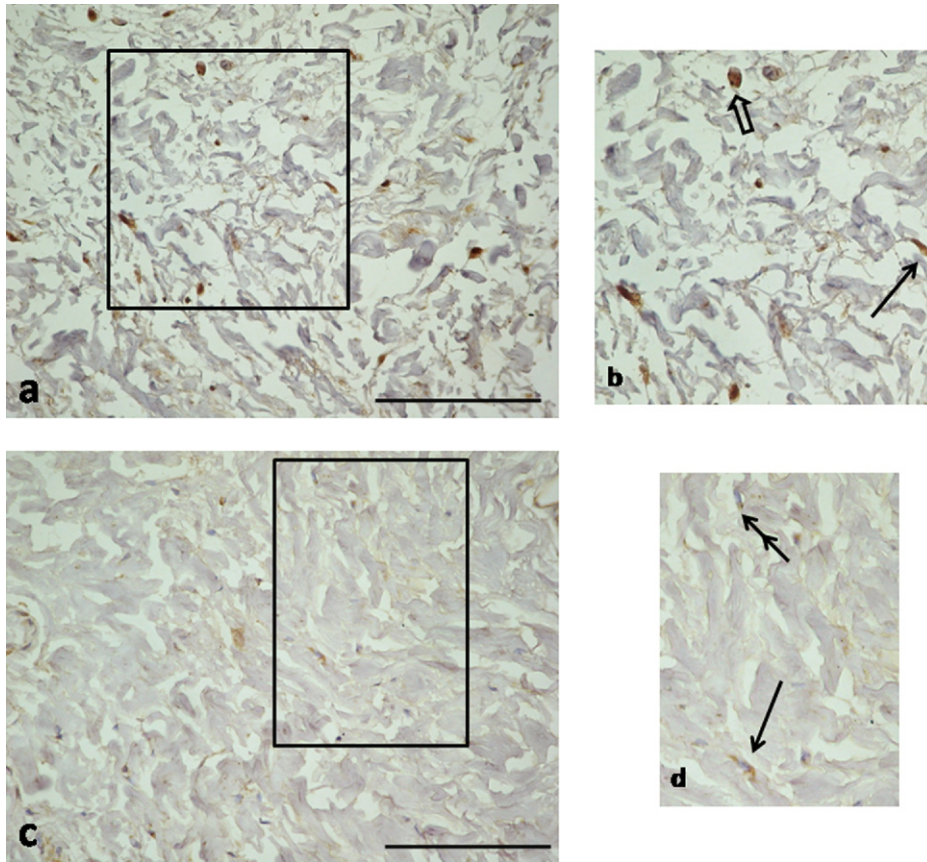


Fig. 3. Immunostaining for tumor necrosis factor-related apoptosis-inducing ligand in the intermediate band of the disc. Microphotographs from temporomandibular joint disc of patients affected by disc displacement without reduction (a) and with reduction (c). (b) Magnification of the box of in a. (d) Magnification of the box in c. Arrow = fibroblast; open arrow = fibrochondrocyte; double-headed arrow = immunonegative staining. Bar = 100 μ m.

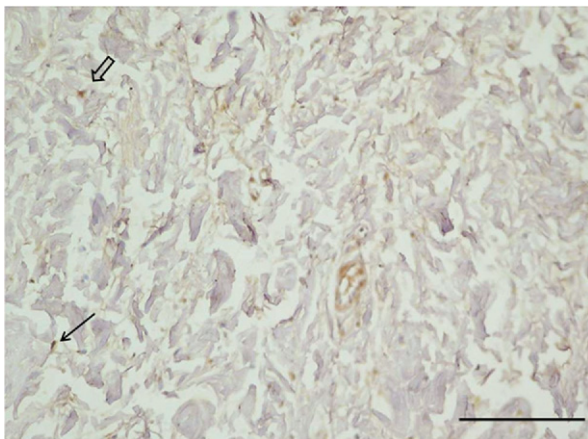


Fig. 4. Immunostaining for death receptor 5 in the intermediate band of the disc. Microphotographs from temporomandibular joint disc of patients affected by disc displacement with reduction. Arrow = fibroblast; open arrow = fibrochondrocyte. Bar = 100 μ m.

DR5 are overexpressed in excised displaced TMJ discs. These overexpressions increase with the type of disc displacement and show regional variation, in that the bilaminar zone represents the area with a higher final staining score. Furthermore, the present results show that TRAIL and DR5 expression dramatically change in displaced human TMJ disc, in that the prevalence of immunopositive cells increase in the following order: normal, ADDwR, and ADDwoR. Moreover, regional variation in the zones of the disc was appreciated, as there was a higher up-regulation in the pPDA at least regarding TRAIL.

Interestingly, these results support earlier imaging findings on TMJ disc degeneration that argue that disc degeneration starts from the posterior portion of the disc.^{44,45} In magnetic resonance imaging studies that investigated the signal intensities (SI) of TMJ displaced discs, the SI of the posterior bands were found to be higher than those of the ABs and increased with the progress of internal derangement. Thus, data are accumulating that disc degeneration begins in the posterior

band of the disc.⁴⁴ Consistent with this, we found significantly higher FSS grading in the PDA, suggesting that, in this area, there are more cells undergoing apoptosis and, presumably this is an area that shows initial degenerative changes.

To our knowledge, this is the first study to address the question of a zonal distribution of TRAIL and DR5 within displaced TMJ discs as well as correlating these findings with the different kinds of ID. All in all, this study provides new insights relevant to the presence and distribution of apoptosis in TMJ displaced discs. The observed correlation of TRAIL/DR5 expression with increased severity of TMJ disc displacement suggests a possible pivotal role of the TRAIL/DR5 system. Thus additional studies to establish their importance are encouraged.

REFERENCES

- Whyte AM, McNamara D, Rosenberg I, Whyte AW. Magnetic resonance imaging in the evaluation of temporomandibular joint disc displacement—a review of 144 cases. *Int J Oral Maxillofac Surg* 2006;35:696-703.
- Nebbe B, Major PW. Prevalence of TMJ disc displacement in a pre-orthodontic adolescent sample. *Angle Orthod* 2000;70:454-63.
- Katzberg RW, Westesson PL, Tallents RH, Drake CM. Anatomic disorders of the temporomandibular joint disc in asymptomatic subjects. *J Oral Maxillofac Surg* 1996;54:147-53; discussion 153-5.
- Sato S, Goto S, Kawamura H, Motegi K. The natural course of nonreducing disc displacement of the TMJ: relationship of clinical findings at initial visit to outcome after 12 months without treatment. *J Orofac Pain* 1997;11:315-20.
- Milam SB. Pathophysiology and epidemiology of TMJ. *J Musculoskelet Neuronal Interact* 2003;3:382-90; discussion 406-7.
- Zardeneta G, Milam SB, Schmitz JP. Iron-dependent generation of free radicals: plausible mechanisms in the progressive deterioration of the temporomandibular joint. *J Oral Maxillofac Surg* 2000;58:302-8; discussion 309.
- Eberhard D, Bantleon HP, Steger W. Functional magnetic resonance imaging of temporomandibular joint disorders. *Eur J Orthod* 2000;22:489-97.
- Leonardi R, Loreto C, Barbato E, Caltabiano R, Lombardo C, Musumeci G, et al. MMP-13 (collagenase 3) localization in human temporomandibular joint discs with internal derangement. *Acta Histochem* 2008;110:314-8.
- Matsumoto T, Tojyo I, Kiga N, Hiraishi Y, Fujita S. Expression of ADAMTS-5 in deformed human temporomandibular joint discs. *Histol Histopathol* 2008;23:1485-93.
- McCoy JM, Gotcher JE, Chase DC. Histologic grading of TMJ tissues in internal derangement. *Cranio* 1986;4:213-8.
- Alstergren P. Cytokines in temporomandibular joint arthritis. *Oral Dis* 2000;6:331-4.
- Park JB, Kim KW, Han CW, Chang H. Expression of Fas receptor on disc cells in herniated lumbar disc tissue. *Spine* 2001;26:142-6.
- Bhardwaj A, Aggarwal BB. Receptor-mediated choreography of life and death. *J Clin Immunol* 2003;23:317-32.
- Bertram H, Nerlich A, Omlor G, Geiger F, Zimmermann G, Fellenberg J. Expression of TRAIL and the death receptors DR4 and DR5 correlates with progression of degeneration in human intervertebral disks. *Mod Pathol* 2009;22:895-905.
- Wang D, Liu M, Song H, Wang M, Yang K, Zhang Y. Expression of Bax and caspase-3 and apoptosis in human lumbar intervertebral disc degeneration. *Zhongguo Xiu Fu Chong Jian Wai Ke Za Zhi* 2008;22:421-5.
- Wiley SR, Schooley K, Smolak PJ, Din WS, Huang CP, Nicholl JK, et al. Identification and characterization of a new member of the TNF family that induces apoptosis. *Immunity* 1995;3:673-82.
- Pitti RM, Marsters SA, Ruppert S, Donahue CJ, Moore A, Ashkenazi A. Induction of apoptosis by Apo-2 ligand, a new member of the tumor necrosis factor cytokine family. *J Biol Chem* 1996;271:12687-90.
- Sheridan JP, Marsters SA, Pitti RM, Gurney A, Skubatch M, Baldwin D, et al. Control of TRAIL-induced apoptosis by a family of signaling and decoy receptors. *Science* 1997;277:818-21.
- Pan G, Ni J, Wei YF, Yu G, Gentz R, Dixit VM. An antagonist decoy receptor and a death domain-containing receptor for TRAIL. *Science* 1997;277:815-8.
- Pan G, O'Rourke K, Chinnaiyan AM, Gentz R, Ebner R, Ni J, et al. The receptor for the cytotoxic ligand TRAIL. *Science* 1997;276:111-3.
- Loreto C, Musumeci G, Leonardi R. Chondrocyte-like apoptosis in temporomandibular joint disc internal derangement as a repair-limiting mechanism. An in vivo study. *Histol Histopathol* 2009;24:293-8.
- Hu JK, Yang K, Li CM, Zhang B, Chen ZX, Chen XZ, et al. The expression of TRAIL and its receptors in gastric cancer and the apoptotic effect of rh-TRAIL on SGC7901 cells. *Oncol Rep* 2009;21:681-8.
- Kopp S. Clinical findings in temporomandibular joint osteoarthritis. *Scand J Dent Res* 1977;85:434-43.
- Leonardi R, Loreto C, Barbato E, Polimeni A, Caltabiano R, Lo Muzio L. A histochemical survey of the human temporomandibular joint disc of patients with internal derangement without reduction. *J Craniofac Surg* 2007;18:1429-33.
- Nitzan DW, Nitzan U, Dan P, Yedgar S. The role of hyaluronic acid in protecting surface-active phospholipids from lysis by exogenous phospholipase A(2). *Rheumatology (Oxford)* 2001;40:336-40.
- Oberg T, Carlsson GE, Fajers CM. The temporomandibular joint. A morphologic study on a human autopsy material. *Acta Odontol Scand* 1971;29:349-84.
- Westesson PL, Bronstein SL, Liedberg J. Internal derangement of the temporomandibular joint: morphologic description with correlation to joint function. *Oral Surg Oral Med Oral Pathol Oral Radiol Endod* 1985;59:323-31.
- Taskaya-Yilmaz N, Ogutcen-Toller M. Magnetic resonance imaging evaluation of temporomandibular joint disc deformities in relation to type of disc displacement. *J Oral Maxillofac Surg* 2001;59:860-5; discussion 865-6.
- Gulen H, Ataoglu H, Haliloglu S, Isik K. Proinflammatory cytokines in temporomandibular joint synovial fluid before and after arthrocentesis. *Oral Surg Oral Med Oral Pathol Oral Radiol Endod* 2009;107:e1-4.
- Hamada Y, Holmlund AB, Kondoh T, Nakaoka K, Sekiya H, Shiobara N, et al. Severity of arthroscopically observed pathology and levels of inflammatory cytokines in the synovial fluid before and after visually guided temporomandibular joint irrigation correlated with the clinical outcome in patients with chronic closed lock. *Oral Surg Oral Med Oral Pathol Oral Radiol Endod* 2008;106:343-9.
- Hamada Y, Kondoh T, Holmlund AB, Sakota K, Nomura Y, Seto K. Cytokine and clinical predictors for treatment outcome of visually guided temporomandibular joint irrigation in patients with chronic closed lock. *J Oral Maxillofac Surg* 2008;66:29-34.

32. Fredriksson L, Alstergren P, Kopp S. Tumor necrosis factor- α in temporomandibular joint synovial fluid predicts treatment effects on pain by intra-articular glucocorticoid treatment. *Mediators Inflamm* 2006;2006:59425.
33. Matsumoto K, Honda K, Ohshima M, Yamaguchi Y, Nakajima I, Micke P, et al. Cytokine profile in synovial fluid from patients with internal derangement of the temporomandibular joint: a preliminary study. *Dentomaxillofac Radiol* 2006;35:432-41.
34. Ogura N, Tobe M, Sakamaki H, Nagura H, Abiko Y, Kondoh T. Tumor necrosis factor- α increases chemokine gene expression and production in synovial fibroblasts from human temporomandibular joint. *J Oral Pathol Med* 2005;34:357-63.
35. Kaneyama K, Segami N, Sun W, Sato J, Fujimura K. Analysis of tumor necrosis factor- α , interleukin-6, interleukin-1 β , soluble tumor necrosis factor receptors I and II, interleukin-6 soluble receptor, interleukin-1 soluble receptor type II, interleukin-1 receptor antagonist, and protein in the synovial fluid of patients with temporomandibular joint disorders. *Oral Surg Oral Med Oral Pathol Oral Radiol Endod* 2005;99:276-84.
36. Kaneyama K, Segami N, Nishimura M, Suzuki T, Sato J. Importance of proinflammatory cytokines in synovial fluid from 121 joints with temporomandibular disorders. *Br J Oral Maxillofac Surg* 2002;40:418-23.
37. Fu K, Ma X, Zhang Z, Chen W. Tumor necrosis factor in synovial fluid of patients with temporomandibular disorders. *J Oral Maxillofac Surg* 1995;53:424-6.
38. Shafer DM, Assael L, White LB, Rossomando EF. Tumor necrosis factor- α as a biochemical marker of pain and outcome in temporomandibular joints with internal derangements. *J Oral Maxillofac Surg* 1994;52:786-91; discussion 91-2.
39. Haschtman D, Stoyanov JV, Gedet P, Ferguson SJ. Vertebral endplate trauma induces disc cell apoptosis and promotes organ degeneration in vitro. *Eur Spine J* 2008;17:289-99.
40. Kohyama K, Saura R, Doita M, Mizuno K. Intervertebral disc cell apoptosis by nitric oxide: biological understanding of intervertebral disc degeneration. *Kobe J Med Sci* 2000;46:283-95.
41. Park JB, Lee JK, Park SJ, Kim KW, Riew KD. Mitochondrial involvement in Fas-mediated apoptosis of human lumbar disc cells. *J Bone Joint Surg Am* 2005;87:1338-42.
42. Zhang L, Niu T, Yang SY, Lu Z, Chen B. The occurrence and regional distribution of DR4 on herniated disc cells: a potential apoptosis pathway in lumbar intervertebral disc. *Spine* 2008;33:422-7.
43. Zhang L, Niu T, Yang SY, Lu Z, Chen B. The occurrence and regional distribution of DR4 on herniated disc cells: a potential apoptosis pathway in lumbar intervertebral disc. *Spine* 2008;33:422-7.
44. Orhan K, Nishiyama H, Tadashi S, Murakami S, Furukawa S. Comparison of altered signal intensity, position, and morphology of the TMJ disc in MR images corrected for variations in surface coil sensitivity. *Oral Surg Oral Med Oral Pathol Oral Radiol Endod* 2006;101:515-22.
45. Perez del Palomar A, Doblare M. An accurate simulation model of anteriorly displaced TMJ discs with and without reduction. *Med Eng Phys* 2007;29:216-26.

Reprint requests:

Rosalia Leonardi
Istituto di II Clinica Odontoiatrica
Città Universitaria
Policlinico Università di Catania
Via S. Sofia n.78
Catania 95123
Italy
rleonard@unict.it