

This is an open-access article distributed under the terms of the Creative Commons Attribution License, which permits unrestricted use, distribution, and reproduction in any medium, provided the original author(s) and source are credited.



ISSN: 2161-0932

Gynecology & Obstetrics

**The International Open Access
Gynecology & Obstetrics**

Executive Editors

Natalie Luzina Rasgon
Stanford University, USA

Pamela D. Berens
University of Texas - Houston Medical School, USA

Stephen Robert Kovac
Emory University, USA

Enrique Hernandez
Temple University, USA

Robert R. Freedman
Wayne State University, USA

Available online at: OMICS Publishing Group (www.omicsonline.org)

This article was originally published in a journal by OMICS Publishing Group, and the attached copy is provided by OMICS Publishing Group for the author's benefit and for the benefit of the author's institution, for commercial/research/educational use including without limitation use in instruction at your institution, sending it to specific colleagues that you know, and providing a copy to your institution's administrator.

All other uses, reproduction and distribution, including without limitation commercial reprints, selling or licensing copies or access, or posting on open internet sites, your personal or institution's website or repository, are requested to cite properly.

Digital Object Identifier: <http://dx.doi.org/10.4172/2161-0932.1000128>

Uterine Myxoid Leiomyosarcoma Associated with Multiple Myomas in a Fertile Woman: A Case Report

Vito Leanza*, Maria Cristina Teodoro, Alfio D'Agati, Ilaria Marilli, Gianluca Leanza, Giuseppe Zarbo and Carlo Pafumi

Department of Surgery, Catania University, Italy

Abstract

A 37 year old woman was admitted to our university hospital for menometrorrhagia. The case history showed that the patient had menometrorrhagia for six months; moreover, during the abdominal examination we found a mass occupying the hypogastric and mesogastric area. The tumefaction was hard and it reached the level of the umbilicus. On combined vaginal-abdominal examination a mass on the anterior wall and multiple myomata were felt; the uterus was found to have been enlarged to the size equivalent to 18 weeks pregnancy; adnexa regular were felt. During the surgery multiple myomas were found. The largest, 10 cm diameter, was soft in consistence with a gelatinous structure. Total abdominal hysterectomy with preservation of adnexa was performed (Figure 1). Histopathological result gave evidence of myxoid leiomyosarcoma in the largest myoma, whereas the others fibroid nodes were without atypia.

Introduction

Uterine sarcomas account for 3% of uterine cancers. Uterine sarcomas comprise leiomyosarcoma, endometrial stromal sarcoma, adenocarcinoma, undifferentiated endometrial sarcoma, and their variants [1]. The rarity of these tumors has prevented the performance of large epidemiological studies to identify risk factors. Data regarding parity, onset of menarche, or age at menopause as risk factors are inconclusive [2]. Myxoid leiomyosarcoma (MLMSs) is an uncommon tumor, in most cases recognized only after surgery. Rubin et al. reported 18 cases of soft tissue leiomyosarcomata in which myxoidstroma occupied >50% of the tissue examined. In their study patients ranged in age from 22 to 84 years old (median, 57.5 yrs) and female patients outnumbered male patients 14 to 4 [3]. When MLMSs is associated with multiple myomata, the gross appearance of the malignant mass differs from others for a soft, necrotic and gelatinous aspect. In the past, the presence of 10 or more mitoses per 10 high-power fields (HPFs) was considered key to establish the diagnosis of leiomyosarcoma. Even though mitotic index is an important feature in the assessment of malignancy, several studies based on large series of uterine smooth muscle tumors (U-SMTs) have shown that mitotic activity alone is not predictive of poor outcome in these tumors [4-6]. Current criteria for diagnosis of classic leiomyosarcomas requires assessment of the number of m.f./10 HPFs, nuclear atypia, and tumor cell necrosis (TCN), in recognition of the fact that a variety of exogenous and endogenous hormones can influence the mitotic index and development of TCN [7]. With ultrasound examination topographic limits are normal, while the internal structure is inhomogeneous and hypoechoic compared to either the fibroid node or uterine wall. The doppler flow showed that intratumoral resistance index (RI) is significantly lower in uterine sarcomas than in leiomyomas, but the result is not significant in all cases. When a cut-off value of 0.5 for the RI is considered, the detection rate for uterine malignant mass is 67%. In this study we report a case of uterine myxoid leiomyosarcoma associated with multiple myomas in a fertile woman [8].

Case Report

A 37 year old female, (para 1 spontaneous delivery) was admitted to our university hospital complaining a story of abdominal and pelvic pain, and menometrorrhagia lasting for 6 months. During this period the patient had been undergoing intensive therapy with iron drugs and folates. At the admission blood tests showed: Hemoglobin 11.5 g/dl; Iron 31 µg/dl; Red Blood Cells 4.320.000/µL; White Blood Cells 7.900/µL; Platelets 285.000/µL. Upon abdominal examination, hypochondriac organs were regular size; a mass occupying the hypogastric and

mesogastric was felt. The consistence was hard and it reached the level of the umbilicus. On vaginal examination, uterus was 18 weeks size and a mass was felt on anterior wall, multiple myomas were felt as well. The adnexa were regular. Speculum examination showed a regular cervix and vagina with clots coming from the uterine orifice. With ultrasound examination uterus appeared increased in size (longitudinal: 180 mm; transversal: 107 mm; sagittal diameter: 108 mm). Four myomata were detected. The three myomata were subserous: of the right angle of the uterus fundus (42 mm), of the left one (34 mm) and of the left side wall of the uterus (59 mm). The Doppler flow study was regular for all the masses (RI: 0.8). The greatest myoma was irregular in structure and inhomogeneous, the ultrasound aspect was hypoechoic compared with either fibroid node or uterine wall. In the sick tissue vascularization had spread to every part, mainly inside the cancer, instead in the remaining three myomata there was predominant peripheral vascularization.

The "Pfannestiel" Transversal laparotomy under general anesthesia was performed. In surgery, as in the ultrasonographic examination, uterus was found increased in size and multiple myomata were detected. The biggest myoma (10 cm large) had a grayish color and a gelatinous consistence; whereas the smaller ones were whitish and

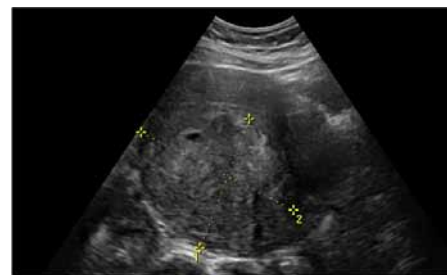


Figure 1: Image of Total abdominal hysterectomy.

*Corresponding author: Vito Leanza, Department of Surgery, Catania University, Italy, E-mail: vito.leanza@gmail.com

Received July 03, 2012; Accepted August 24, 2012; Published August 27, 2012

Citation: Leanza V, Teodoro MC, Agati AD, Marilli I, Leanza G, et al. (2012) Uterine Myxoid Leiomyosarcoma Associated with Multiple Myomas in a Fertile Woman: A Case Report. Gynecol Obstet 2:128. doi:10.4172/2161-0932.1000128

Copyright: © 2012 Leanza V, et al. This is an open-access article distributed under the terms of the Creative Commons Attribution License, which permits unrestricted use, distribution, and reproduction in any medium, provided the original author and source are credited.

hard. Adnexa were regular in size and shape. Total hysterectomy with preservation of adnexa was performed. Her post-operative course was uneventful. No transfusions were performed. After four days the patient was discharged. Neoplasm infiltrated the surrounding myometrium with cellular moderate atypia was found. The remained nodes were typical myomata. Endometrium was proliferative. Micropolypoid cervicitis was observed too. Further histological examination verified a borderline tumor within myxoid leiomyosarcoma and cotyledoned leiomyoma.

Discussion

The limit between benign and malignant tumors is not always defined. Even benign nodes can be associated with malignant masses. Histologically many types of leiomyomata have been recognized, although the aspect is macroscopically comparable. The great cellularity of myomata may leads to confusion with leiomyosarcomata.

Among various subtypes, the following are considered [9]:

1. **Atypical leiomyomata** are characterized by moderately to severely pleomorphic multinucleated tumor cells with low mitotic counts and absence of coagulative tumor cell necrosis. If multinucleated cells are numerous, the terms "bizarre" or "symplastic" leiomyoma have been applied. These tumors are also confused with leiomyosarcoma, which have a higher mitotic count [10].
2. **Epithelioid leiomyoma** include leiomyoblastoma, clear cell leiomyoma, and plexiform leiomyoma [11]. The clinical behaviour of the Epithelioid leiomyomas is varied. Small tumors without cytologic atypia and with circumscribed margins, extensive hyalinization, low mitotic activity, and clear cells are considered benign.
3. **Lipoleiomyoma** contains large areas of fat. These areas may be well circumscribed or diffused. A pure lipoma is uncommon. These tumors should not be confused with mixed mesodermal sarcoma.
4. **Leiomyoma with tubules** is uncommon. Histologically, epithelium-lined tubules are noted. Mesothelial differentiation also occurs.
5. **Myxoid leiomyoma** contains an amorphous myxoid substance producing a soft translucent appearance. The margins are well circumscribed and mitotic figures are absent.
6. **Cotyledoned leiomyoma or Sternberg Tumor** is a very rare variant of uterine smooth muscle tumor characterized by the presence of congestal exophytic placental tissue. Cotyledonoid leiomyoma has a peculiar gross appearance which usually raises the suspicion of sarcoma. To avoid overtreatment of such cases, intraoperative frozen section is a mandatory and helpful procedure [12].

Many leiomyomata undergo degeneration (sarcomatous transformation). Malignant transformation can occur even in relatively small leiomyomata. These secondary changes occur as the myoma outgrows its blood supply and are termed hyaline, myxomatous, calcific, cystic, fatty, carneous (red), and sarcomatous. The mildest change is hyaline degeneration, found in 65% of myomas. Its appearance is homogeneous, with loss of the whorled pattern and cellular detail as the smooth muscle cells are replaced by fibrous connective tissue. Myxomatous change occurs in 15% of tumors, and calcific degeneration occurs in 4% to 10%, more commonly in older women.

Cystic degeneration is found in 4% of leiomyomas and results from coalescence of hyalinised areas with liquefaction. Fatty degeneration occurs rarely, but may result from late stage hyaline degeneration.

Patients with a leiomyosarcoma with a leiomyomata component usually have favorable prognosis. Immunohistochemical examination of p53, p16 and Ki-67 is considered as a useful tool for identification of malignant focus [13]. This case report offers to consider mainly two aspects related to the diagnosis and the treatment. Regarding diagnosis, we have to consider three stages: the pre-operative, the intra-operative and the final result. Pre-operative clinical diagnosis is difficult to perform and vaginal bimanual examination cannot disclose the malignancy of the mass. Ultrasounds are useful for the diagnosis of the mass, but in many cases the difference between leiomyoma with benign degeneration and leiomyosarcoma is very tricky. Doppler flowmetry is helpful when there is a suspicion of malignancy; moreover, in many cases it is not discriminating. Intra-operatively, the macroscopic appearance of gelatinous aspect and its infiltrating characteristic tend towards malignancy. Histologic result is considered the final diagnosis; nevertheless, in such a case the doubts remain and it confirms the old phrase: "natura non facit saltus" (nature doesn't take steps), meaning that changes are gradual and limits are sometimes difficult to find.

Conclusion

This case report is very interesting due to the rarity of this pathology occurring in women of fertile age. Uterine MLMs are often difficult to recognize, owing to their mild cytologic atypia and a low mitotic index.

When many nodes are discovered and alterations of aspect found, the malignancy must be suspected and an operation must be performed. A correct diagnosis and treatment may save the woman with a favorable prognosis and good quality of life.

These results suggest that the intratumoral RI detected by color and pulsed doppler ultrasonography by themselves could be poor for the preoperative differential diagnosis of uterine sarcoma.

Acknowledgment

Valentina Pafumi has carried out English language editing for this article.

References

1. Tse KY, Crawford R, Ngan HY (2011) Staging of uterine sarcomas. *Best Pract Res Clin Obstet Gynecol* 25: 733-749.
2. Christopherson WM, Williamson EO, Gray LA (1972) Leiomyosarcoma of the uterus. *Cancer* 29: 1512-1517.
3. Rubin BP, Fletcher CD (2000) Myxoid leiomyosarcoma of soft tissue, an underrecognized variant. *Am J Surg Pathol* 24: 927-936.
4. Chang E, Shim SI (1998) Myxoid leiomyosarcoma of the uterus: a case report and review of the literature. *J Korean Med Sci* 13: 559-562.
5. Hendrickson MR, Kempson RL (2000) A diagnostic approach to smooth muscle tumours of the uterus. *Current Diagnostic Pathology* 6: 21-30.
6. Oliva E, Clement PB, Young RH (2002) Mesenchymal tumours of the uterus: selected topics emphasizing diagnostic pitfalls. *Current Diagnostic Pathology* 8: 268-282.
7. Burch DM, Tavassoli FA (2011) Myxoid leiomyosarcoma of the uterus. *Histopathology* 59: 1144-1155.
8. Szabó I, Szánthó A, Csabay L, Csapó Z, Szirmai K, et al. (2002) Color Doppler ultrasonography in the differentiation of uterine sarcomas from uterine leiomyomas. *Eur J Gynaecol Oncol* 23: 29-34.
9. Toledo G, Oliva E (2008) Smooth muscle tumors of the uterus: a practical approach. *Arch Pathol Lab Med* 132: 595-605.
10. Sung CO, Ahn G, Song SY, Choi YL, Bae DS (2009) A typical leiomyomas of the uterus with long-term follow-up after myomectomy with immunohistochemical

analysis for p16INK4A, p53, Ki-67, estrogen receptors, and progesterone receptors. *Int J Gynecol Pathol* 28: 529-534.

11. Kurman RJ, Norris HJ (1976) Mesenchymal tumors of the uterus. VI. Epithelioid smooth muscle tumors including leiomyoblastoma and clear-cell leiomyoma: a clinical and pathologic analysis of 26 cases. *Cancer* 37: 1853-1865.
12. Saeed AS, Hanaa B, Faisal AS, Naila AM (2006) Cotyledonoid dissecting leiomyoma of the uterus: a case report of a benign uterine tumor with sarcomalike gross appearance and review of literature. *Int J Gynecol Pathol* 25: 262-267.
13. Yanai H, Wani Y, Notohara K, Takada S, Yoshino T (2010) Uterine leiomyosarcoma arising in leiomyoma: clinicopathological study of four cases and literature review. *Pathol Int* 60: 506-509.

Submit your next manuscript and get advantages of OMICS Group submissions

Unique features:

- User friendly/feasible website-translation of your paper to 50 world's leading languages
- Audio Version of published paper
- Digital articles to share and explore

Special features:

- 200 Open Access Journals
- 15,000 editorial team
- 21 days rapid review process
- Quality and quick editorial, review and publication processing
- Indexing at PubMed (partial), Scopus, DOAJ, EBSCO, Index Copernicus and Google Scholar etc
- Sharing Option: Social Networking Enabled
- Authors, Reviewers and Editors rewarded with online Scientific Credits
- Better discount for your subsequent articles

Submit your manuscript at: <http://www.omicsonline.org/submission/>

