

Staphylococcal osteomyelitis treated with Ilizarov technique and antibiotic: a case report

C. Puma Pagliarello, V. Pavone, G. Testa, G. Condorelli, G. Sessa

Orthopaedic Clinic, AOU Policlinico-Vittorio Emanuele, Catania, Italy

ABSTRACT: Osteomyelitis is a dangerous and unforeseeable event in the treatment of bone fractures. In a 38-year-old patient, surgical treatment for leg fractures due to a domestic accident was complicated by osteomyelitis. To treat this severe complication, the following modality was followed: hardware removal, wide resection of the dead bone with debridement of the infected tissue, the implant of cement antibiotic-load spacer to fill the space, and a mono-axial external fixation. Subsequently, at the resolution of the infection, an Ilizarov external fixator was used, and a proximal tibia osteotomy was performed to obtain a distraction osteogenesis, while the gap at the distal tibia segment after the cement spacer removal was compressed. At the removal of the Ilizarov fixator, the clinical response was reasonable, but radiographically there was not a clear evidence of bone healing at the site of the previous fracture.

— **Key words:** Osteomyelitis, Infection, Leg fracture, External fixator, Ilizarov.

INTRODUCTION

Infections are one of the most important and fearsome complications following a fracture treatment. Surgical treatments, even if carefully performed, are still exposed to a high rate of infection. This unlucky event can involve different areas: hardware, bone, and soft tissues. The incidence of infection in orthopaedic trauma ranges from 5% to 10% depending on the location, the severity of the injury, the type of fracture, and the presence of microorganisms at the site of fracture¹.

Osteomyelitis is one of the most dangerous complications, and its treatment is a challenge for the orthopaedic surgeon. There is still no scientific evidence to guide treatment of osteomyelitis¹.

In the literature, many types of treatments are suggested in the management of infected non-unions of bones.

The Masquelet technique is widely used for the treatment of post-traumatic long-bone osteomyelitis².

The “non-contact plate method”³ is another type of treatment proposed.

We report a case of osteomyelitis treated by the Ilizarov technique. The Ilizarov technique has been used in the UK for the last 20 years in the management of in-

fectured non-union of long bones. This method uses K-wires inserted percutaneously, which are implanted and tensioned to provide a strong frame construct⁴.

CASE PRESENTATION

A 38-year-old patient with a no significant clinical history was admitted for a tibia fracture 43-C3 (A.O. classification) due to a domestic accident. Due to the involvement of soft-tissue, Tscherne type 2 fracture classification⁵ was initially treated in emergency with a skeletal-calcaneus traction. An open reduction internal fixation was performed after 10 days. The patient was administered general anaesthesia. We performed a lateral access to the distal part of the fibula. The fibula fracture was reduced with screws and a plate. Then, using a mini antero medial access to the distal region of the tibia, an open reduction and internal fixation with a plate and screws was performed together with two inter-fragmentary screws. During the post-operative controls two months after surgery, we noticed a surgical-swab dehiscence and an ulcer in the peri-malleolar region that had purulent secretion. The radiographic control showed fracture consolidation retar-

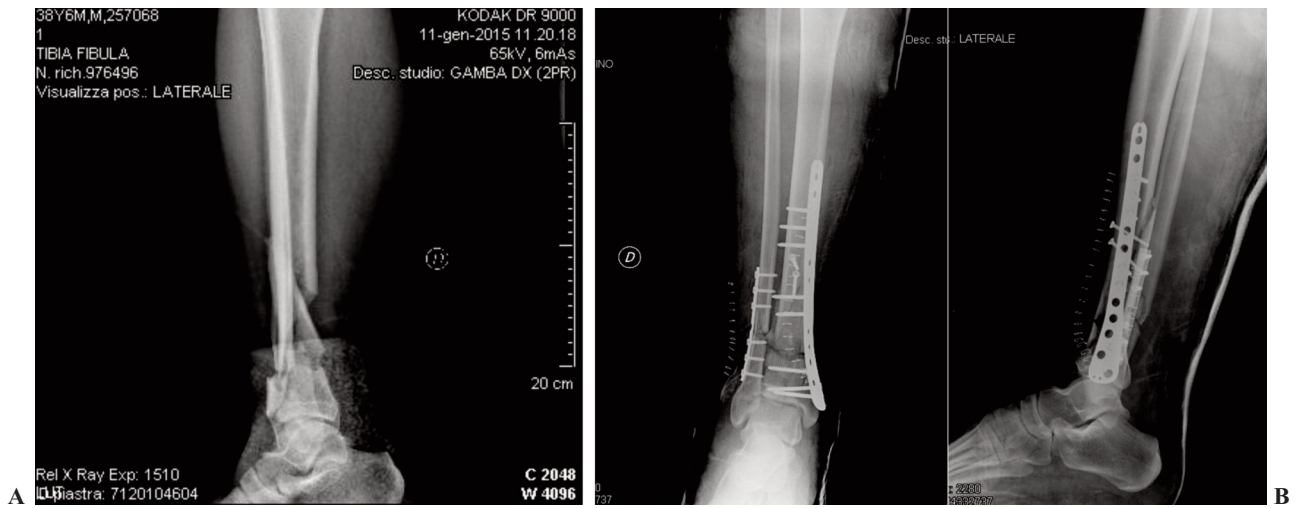


Fig. 1. A, X-ray at Emergency Department showing complex plurifragmentary fractures of the distal third of the right tibia and fibula. B, Post-operative X-ray in AP and LL views of the complex fracture treated with screws and plates.

dation. The bloody PCR values during this period reached values of 218.7 mg/L (cut off 5 mg/l), and a wound swab gave results to positive *Staphylococcus aureus* beta-lactamase resistant infection. So, the patient was hospitalized again after three months. Rifampicin 600 mg BID was administered for seven days, then a moxifloxacin 400 mg/die therapy was started. A second surgery was performed using the incision of the previous surgical wound. We removed the hardware, resected 3 cm of the dead bone with wide debridement of the infected scarred soft tissue, implanted cement antibiotic-load spacer to fill the space, and a mono-axial external fixation was carried out to stabilize the bones. The intra-operative swab results were again positive to *Staphylococcus aureus* beta-lactamase resistant. The patient continued antibiotic therapy after the demission until the subsequent bloody control (PCR values, leucocytes) was found to be negative. The patient was hospitalized for a

third time three months after the second surgery for a substitution of the external fixator. The mono-axial fixator was removed as the cement spacer. The bone margins were debrided, a proximal tibia and fibula osteotomy was performed, and an Ilizarov external fixator was used to compress the distal segment and to allow the osteogenetic distraction of the proximal segment. We proceeded with an elongation of 1 mm per day; after 30 days, 3 cm of bone elongation was reached. Five months after the last surgery, there were no radiographical or laboratory signs of infection neither, the limb length difference was corrected, the Ilizarov fixator was removed, and a short leg plaster cast was applied for three weeks. At the last follow-up at six months, the patient presented a reasonable clinical picture, but the radiographic control showed no clear sign of reparative callus at the fracture. At present, the patient is walking with a leg brace.

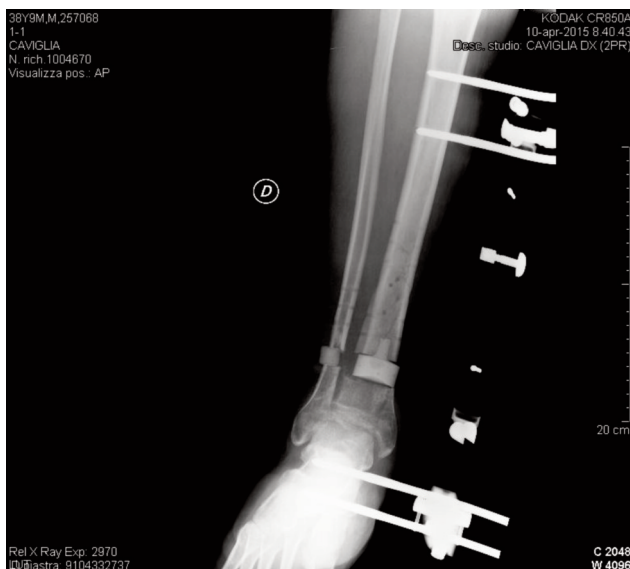


Fig. 2. Post-operative X-ray after infected bone resection, antibiotic-load spacer, and monoaxial fixator.

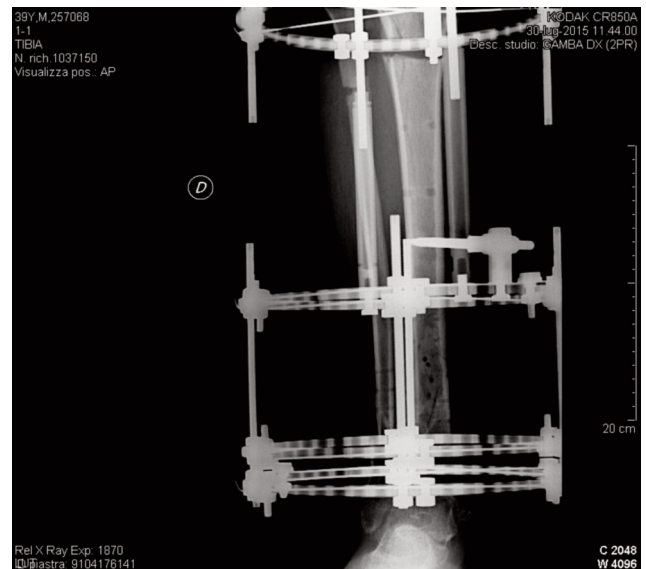


Fig. 3. Ilizarov treatment, proximal tibia, and fibula osteotomy; distal segment compression.

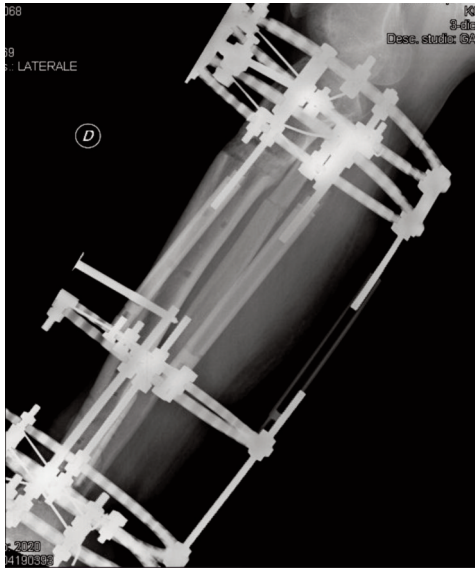


Fig. 4. Radiographic control five months after the Ilizarov treatment.

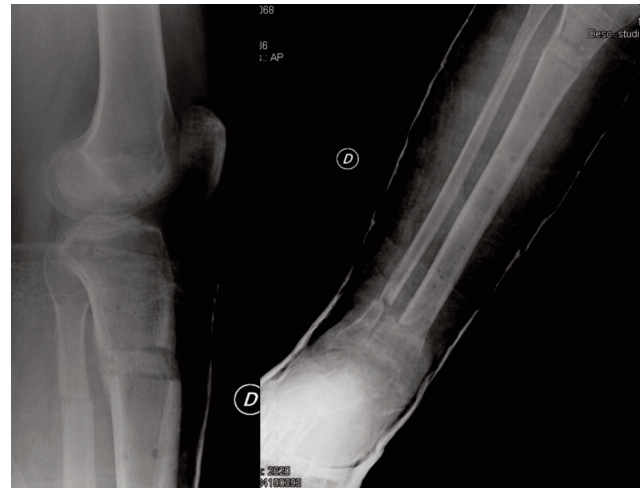


Fig. 5. Radiographic control after Ilizarov fixator removal and cast application; proximal and distal segment.

DISCUSSION

The Ilizarov technique combined with an appropriate antibiotic treatment is a good option for the surgical treatment of leg osteomyelitis.

In the literature, the results using the Ilizarov technique for the treatment of long-bone osteomyelitis, demonstrate a rate of success of more than 86%⁶⁻⁸.

The Ilizarov technique has been demonstrated to be comparable or better compared with other surgical techniques reported in the literature^{9,10}.

The wide debridement of the bone and the soft tissue allow the removal of infection and non-vital tissue, reducing the risk of recurrent infections and the increase of post-operative complication such as delayed union, nonunion, and vascular thrombosis¹¹. The use of an Ilizarov fixator allows the bone-gap recovery after the dead bone resection and the infected tissue debridement.

The possibility of early deambulation is another advantage of this type of treatment. The early deambulation represents a psychological benefit for the patient compared to other types of treatments. The mechanical stresses also represent a stimulation for bone remodeling¹².

CONCLUSION

Ilizarov technique and antibiotic treatment represented a good strategy to manage Staphylococcal osteomyelitis, characterized by early deambulation without recurrent infections.

CONFLICT OF INTERESTS:

The Authors declare that they have no conflict of interests.

REFERENCES

1. Walter G, Kemmerer M, Kappler C, Hoffmann R. Treatment algorithms for chronic osteomyelitis. *Dtsch Arztebl Int* 2012; 109(14): 257-264.
2. Chadayammuri V, Hake M, Mauffrey C. Innovative strategies for the management of long bone infection: a review of the Masquelet technique. *Patient Saf Surg* 2015; 9(1): 32.
3. Alemdar C, Azboy I, Atiç R, Özkul E, Gem M, Kapukaya A. Management of infectious fractures with "Non-Contact Plate" (NCP) method. *Acta Orthop Belg* 2015; 81(3): 523-529.
4. Shahid M, Hussain A, Bridgeman P, Bose D. Clinical Outcomes of the Ilizarov method after an infected tibial non union. *Arch Trauma Res* 2013; 2(2): 71-75.
5. Tschern H, Oestern HJ. A new classification of soft-tissue damage in open and closed fractures. *Unfallheilkunde* 1982; 85(3): 111-115.
6. Onyekwelu I, Hasan S, Chapman BC. Ilizarov external fixator for stump salvage in infected nonunions. *Orthopedics* 2013; 36(8): e990-e994.
7. El-Rosasy MA. Ilizarov treatment for pseudarthrosis of the tibia due to haematogenous osteomyelitis. *J Pediatr Orthop B* 2013; 22(3): 200-206.
8. Bibbo C. Reverse sural flap with bifocal Ilizarov technique for tibial osteomyelitis with bone and soft tissue defects. *J Foot Ankle Surg* 2015; 53(3): 344-349.
9. Mauffrey C, Hake ME, Chadayammuri V, Masquelet AC. Reconstruction of Long Bone Infections Using the Induced Membrane Technique: Tips and Tricks. *J Orthop Trauma* 2015.
10. Scholz AO, Gehrman S, Glombitza M, Kaufmann RA, Bostelmann R, Flohe S, Windolf J. Reconstruction of septic diaphyseal bone defects with the induced membrane technique. *Injury* 2015; 46: S121-S124.
11. Yin P, Zhang L, Zhang L, Li T, Li Z, Li J, Zhou J, Yao Q, Zhang Q, Tang P. Ilizarov bone transport for the treatment of fibular osteomyelitis: a report of five cases. *BMC Musculoskelet Disord* 2015; 16(1): 242.
12. Nomura S, Takano-Yamamoto T. Molecular events caused by mechanical stress in bone. *Matrix Biol* 2000; 19(2): 91-96.