



Contents lists available at ScienceDirect

## International Journal of Surgery Case Reports

journal homepage: [www.casereports.com](http://www.casereports.com)

## Delayed presentation of a metastatic choroidal melanoma to the liver: The latency of an elective metastatic localization



Antonio Pesce<sup>a</sup>, Gaetano Piccolo<sup>b,\*</sup>, Teresa Rosanna Portale<sup>a</sup>, Gaetano La Greca<sup>a</sup>, Stefano Puleo<sup>a</sup>

<sup>a</sup> Department of Surgical Sciences, Organ Transplantation and Advanced Technologies, University of Catania, Via S. Sofia 84, 95123 Catania, Italy

<sup>b</sup> Department of Surgery, University of Catania, Via S. Sofia 78, 95123 Catania, Italy

## ARTICLE INFO

## Article history:

Received 7 June 2015

Accepted 15 July 2015

Available online 13 August 2015

## Keywords:

Choroidal melanoma

Liver metastases

Gastrointestinal symptoms

## ABSTRACT

**INTRODUCTION:** Choroidal melanoma is the most common primary intraocular malignant tumour and the second most common type of primary malignant melanoma in the body. Biologically, cutaneous and ocular melanoma may be considered different, in terms of both metastatic diffusion and metastatic latency. The principal target organ for metastasis of the ocular melanoma is the liver. This distinctive behaviour is also sustained by different metastatic latency, as some patients present with metastatic ocular melanoma several years after the treatment of the primary tumor.

**PRESENTATION OF CASE:** A 60 year-old male who had undergone left ocular enucleation for choroid melanoma 20 years ago was referred to our department with a three months history of diffuse abdominal pain, fever, weight loss and massive ascites. Abdominal ultrasonography (US) and total body computed tomography (CT) scan were performed and revealed diffuse liver metastases, associated with peritoneal carcinosis, bilateral adrenal metastases and a large mass in the left kidney compatible with another secondary localization. An ultrasound guided fine needle agobiopsy (FNA) of liver lesions was performed and the pathological findings led to the diagnosis of liver metastasis from choroidal melanoma. The patient died a few weeks later for hepatic failure.

**DISCUSSION:** Currently, there is no consensus regarding the optimal follow-up in terms of screening modality or time interval after the treatment of the primary ocular melanoma.

**CONCLUSION:** Patients with gastrointestinal symptoms and a history of choroidal melanoma should be investigated for the presence of gastrointestinal or liver metastases, although the original primary malignancy was diagnosed years before the patient's presentation.

© 2015 The Authors. Published by Elsevier Ltd. on behalf of Surgical Associates Ltd. This is an open access article under the CC BY-NC-ND license (<http://creativecommons.org/licenses/by-nc-nd/4.0/>).

### 1. Introduction

The incidence of malignant melanoma continues to increase dramatically worldwide, at an overall rate of about 30% in the last 10 years [1]. In 2014, an estimated 76,100 new cases will be diagnosed and about 9710 patients will die of melanoma in the United States [1].

Melanoma is increasing in men more rapidly than any other malignancy, and in women more rapidly than any other malignancy except lung cancer (respectively 33% for men and 23% for women) [1]. In Europe, the incidence varies in different areas, with higher rates in the countries of Northern Europe (12–20 per 100,000 per year) than in the Mediterranean area (3–5 per 100,000 per year) [2].

Choroidal melanoma is the most common primary intraocular malignant tumour and the second most common type of primary malignant melanoma in the body [3]. Biologically, cutaneous and ocular melanoma may be considered different, in terms of both metastatic diffusion and metastatic latency [4]. The principal target organ for metastasis of the ocular melanoma is the liver [4].

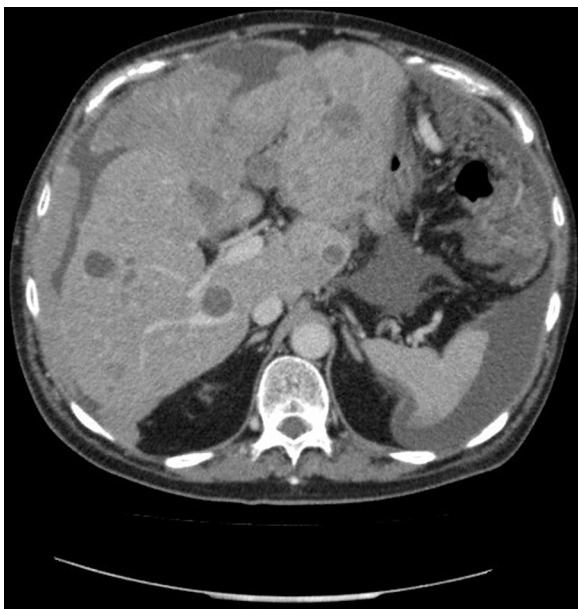
In contrast, cutaneous melanoma spreads primarily to lymph nodes and soft tissues with only a lower incidence of hepatic diffusion (14–20%) [5]. This distinctive behaviour is also sustained by a different metastatic latency [4].

We report a case of metastatic choroidal melanoma after twenty years from surgical removal.

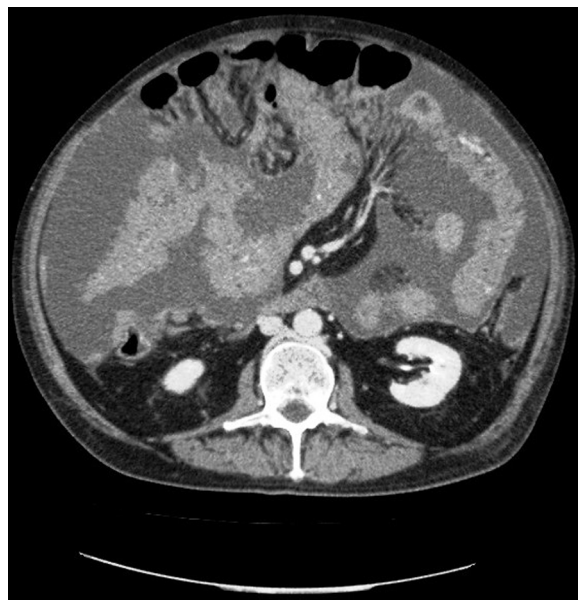
### 2. Presentation of case

A 60 year-old male who had undergone left ocular enucleation for choroid melanoma 20 years ago was referred to our department with a three months history of diffuse abdominal pain, fever, weight loss (> 10 kg) and massive ascites. The histopathological

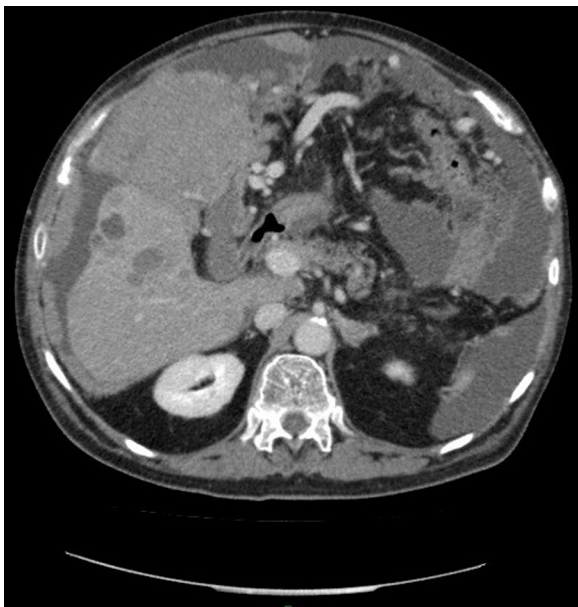\* Corresponding author. Fax: +39 953782912.  
E-mail address: [schaky@hotmail.it](mailto:schaky@hotmail.it) (G. Piccolo).



**Fig. 1.** Multiple liver metastases by choroidal melanoma.



**Fig. 3.** Peritoneal carcinosis with massive ascites.



**Fig. 2.** A large mass involving the gallbladder and the anterior surface of the liver.

examination of the enucleated left eye showed a mixed-cell-type choroidal melanoma without intrascleral or vascular involvement. The size of the melanoma was 10 mm in thickness and 13 mm in diameter. Since then, the patient had been followed up regularly by an ophthalmologist. The last follow-up at 15 years after eye enucleation was negative for recurrence or metastatic diffusion. At the admission, laboratory tests were normal, except for increase CA-125 marker. Abdominal ultrasonography (US) and total body computed tomography (CT) scan were performed and revealed diffuse liver metastases in both lobes with a tendency to confluence, a large mass involving the gallbladder, associated with peritoneal carcinosis, bilateral adrenal metastases and a large mass in the left kidney (5 cm of diameter) compatible with another secondary localization (Figs. 1–3). EGDS and colonoscopy were performed in order to exclude other primitive malignant cancers. An ultrasound guided fine needle agobiopsy (FNA) of liver lesions was performed

and the pathological findings led to the diagnosis of liver metastasis from choroidal melanoma (S-100 protein, vimentin, HMB-45 and Melan A antibodies positive). Percutaneous evacuative paracentesis was also performed and the cytology confirmed the diagnosis. A protocol of systemic chemotherapy was started but the patient died a few weeks later for hepatic failure.

### 3. Discussion

Visceral metastases represent an advanced stage of melanoma and patients that develop metastatic disease continue to have a poor prognosis with a 5-year survival of under 10% [1].

Liver metastases are usually associated with even worse outcomes, with a median survival of few months [6]. Choroidal melanoma is the second most common type of primary malignant melanoma in the body and the liver is the principal target organ for metastases [3].

Among patients that developing metastases, liver metastases can be found in about 90% of the cases and often as a first and only metastatic site in approximately 40% of patients [3].

Metastatic melanoma to the gall bladder is extremely rare and is associated with a very poor prognosis [7,8], delayed metastases to brain, pancreas, adrenal glands and ovaries have also been reported [9–14].

The correct treatment of hepatic metastases from ocular and cutaneous melanoma is still object of debate. The recent development of novel agents have demonstrated better efficacy than traditional chemotherapy. Ipilimumab, a monoclonal antibody directed to the immune checkpoint receptor termed “cytotoxic T lymphocyte antigen-4 (CTLA-4)” has been shown to improve overall survival in patients with metastatic melanoma; similarly vemurafenib (a selective B-Raf inhibitor) and trametinib (a selective inhibitor of MEK1/MEK2) were also demonstrated to improve survival among patients with metastatic melanoma [15,16].

The other operative treatment options include hepatic resection, hepatic intra-arterial chemotherapy, chemoembolization and hepatic perfusions [17].

Nowadays in literature there aren't randomized controlled studies to define the role of surgery in the treatment of hepatic metastases from melanoma.

**Table 1**  
Cases of delayed presentation of metastatic choroidal melanoma to the liver.

Authors	Site	Age	Tumor size	Histology	Treatment of primary tumor	DFI	Liver metastases	Treatment	Liver recurrences	Survival
Gunduz [19]	Left eye	16 year-old Woman	10 × 8 mm	Mixed cell choroidal melanoma	Enucleation	25 years	Multiple left liver metastases	Left lobectomy	After 4 years in the right lobe treated by wedge resection	DFS at 2 years
Meda [20]	Left eye	40 year-old Woman	8 × 4 mm	NS	BRT with Cobalt 60	11 years	Single liver metastases	Metastasectomy + CHT	After 2 years in the right lobe treated by metastec-tomy + RT + CHT	Dead after 5 years for: pulmonary, adrenal gland and bone metastases
Hosonuma [21]	Left eye	50 year-old Man	10 × 8 mm	Spindle cell choroidal melanoma	BRT with Cobalt 60	18 years	Single liver metastases	Metastasectomy + omentectomy	-	Alive at 2 years
Orlando [22]	Right eye	42 year-old Woman	12 × 8 mm	Mixed cell choroidal melanoma	Enucleation	7 years	Multiple liver metastasis	Explorative laparoscopy + CHT	-	Dead after few months for hepatic failure
Our case	Right eye	60 year-old Man	12 × 10 mm	Spindle cell choroidal melanoma	Enucleation	20 years	Multiple liver metastasis + gallbladder and biliary system	None	-	Dead after 3 months for hepatic failure

DFI: disease free interval; DFS: disease free survival; NBRT: brachiradiotherapy with Cobalt 60; RT: radiotherapy; CHT: systemic chemotherapy; S: non specified.

In the era of the peri-operative chemotherapy and of the “target” therapy, the rules governing the treatment of the hepatic metastasis are changed. Therefore in the contest of improving surgical techniques, many surgeons have applied principles of hepatic metastasectomy to the treatment of other types of non-colorectal and non-neuroendocrine metastasis [3].

Although in colorectal cancer, it seems to be clear that hepatic resection is the only possibility of treatment associated with long-term survival and that all patients with resectable disease should be offered hepatic resection, these recommendations still need to be demonstrated for liver metastasis from melanoma. As reported by a recently systematic review, radical resection of liver metastases from melanoma appears to improve overall survival (OS) compared with non-operative management (22–66 months vs 4–12 months), but then, there is an high rate of tumor recurrences [3].

Three times as many, patients with ocular than cutaneous melanoma underwent resection for liver metastases, these differences can be found in a different radical resection rate and in a different recurrence site [3].

In literature there is the perception that liver metastases from ocular melanoma seem to be more frequently multiples and it is more difficult to obtain an R0 resection.

Many patients with ocular metastatic melanoma achieve only a R1-R2 resection after metastasectomy [3] and more likely recur within the liver, whereas patients with a cutaneous primary tumor more often develop extrahepatic involvement [18].

For the same reasons, the 5-year survival rate is also different with a worse prognosis for patients with liver metastases from cutaneous than ocular melanoma [18].

This distinctive behaviour is also sustained by a different metastatic latency to the liver. In ocular melanoma synchronous disease accounts for less than 1% of the cases [6], the majority of patients will develop liver metastasis during the subsequent follow-up period and some of these will present with metastatic ocular melanoma to the liver several years after the treatment of the primary tumor (Table 1).

**4. Conclusion**

Currently, there is no consensus regarding the optimal follow-up, in terms of screening modality or time interval and there is no convincing evidence that surveillance improves overall survival.

On the other hand, seems to be essential to draw up a correct follow-up program after resection of ocular melanoma and after resection of subsequent liver metastasis to achieve optimal outcome. Therefore, patients with gastrointestinal symptoms and a history of choroidal melanoma should be investigated for the presence of gastrointestinal or liver metastases, although the original primary malignancy was diagnosed years before the patient’s presentation.

**Conflicts of interest**

All authors have no conflict of interest.

**Author disclosure informations**

The authors declare that they have no competing interests.

**Author’s contributions**

AP and GP drafted the article; TRP and SP supervised the writing of the paper. All authors read and approved the final manuscript.

Antonio Pesce: Participated substantially in conception, design, and execution of the study, also drafted and edited the manuscript.

Gaetano Piccolo: Participated substantially in conception, design, and execution of the study, also drafted and edited the manuscript.

Gaetano La Greca: Contributed to literature review on the issue and critically reviewed and supervised the manuscript, providing a great contribution.

Stefano Puleo: Participated substantially in conception, design, and execution of the study, also drafted and edited the manuscript.

Teresa Rosanna Portale: Critically reviewed the paper.

### Sources of funding

There has been no sources of funding for our research.

### Ethical approval

The patient has given his written consent.

### Consent

The patient has given his written consent.

### Guarantor

Gaetano Piccolo M.D.

### References

- [1] R. Siegel, J. Ma, Z. Zou, A. Jemal, Cancer statistics, *CA Cancer J. Clin.* 64 (2014) 9–29.
- [2] A.M. Forsea, V. Del Marmol, A. Stratigos, A.C. Geller, Melanoma prognosis in Europe: far from equal, *Br. J. Dermatol.* 171 (July (1)) (2014) 179–182.
- [3] D.M. Albert, Diagnosis of choroidal melanoma, in: Albert, Jakobiec (Eds.), *Principles and Practice of Ophthalmology*, 1st ed., W.B. Saunders Co., Philadelphia, PA, 1994, pp. 3197–3198.
- [4] J.M. Aubin, J. Rekman, F. Vandenbroucke-Menu, R. Lapointe, R.J. Fairfull-Smith, R. Mimeault, F.K. Balaa, G. Martel, Systematic review and meta-analysis of liver resection for metastatic melanoma, *Br. J. Surg.* 100 (August (9)) (2013) 1138–1147.
- [5] U. Leiter, F. Meier, B. Schitteck, C. Garbe, The natural course of cutaneous melanoma, *J. Surg Oncol.* 86 (July (4)) (2004) 172–178.
- [6] D. Gomez, C. Wetherill, J. Cheong, L. Jones, E. Marshall, B. Damato, S.E. Coupland, P. Ghaneh, G.J. Poston, H.Z. Malik, S.W. Fenwick, The liverpool uveal melanoma liver metastases pathway: outcome following liver resection, *J. Surg. Oncol.* 109 (July (6)) (2014) 542–547.
- [7] S. Crippa, G. Bovo, F. Romano, C. Mussi, F. Uggeri, Melanoma metastatic to the gallbladder and small bowel: report of a case and review of the literature, *Melanoma Res.* 14 (2004) 427–430.
- [8] S.R. Agarwal, I. Bhattacharya, Y.V. Patil, A.D. Amrapurkar, Choroidal melanoma metastasizing to the biliary system: a diagnostic dilemma, *Indian J. Med. Paediatr Oncol.* 30 (October (4)) (2009) 138–140.
- [9] P. Vitri, C. Caravati, S. Guzzetti, S. De Angelis, G. Buzzi, R. Gornati, Adrenal metastasis of choroidal melanoma: a case report, *Ann. Ital. Chir.* 65 (September–October (5)) (1994) 537–541.
- [10] E. Midena, V. de Belvis, A.P. Dei Tos, C. Antonini, Isolated brain metastasis of malignant choroidal melanoma 27 years after enucleation, *Arch. Ophthalmol.* 117 (November (11)) (1999) 1553–1556.
- [11] A.K. Achtaopoulos, A.P. Mitsos, E.T. Detorakis, N.V. Georgakoulis, E.E. Drakonaki, V.P. Kozobolis, Late isolated brain metastasis following enucleation for choroidal melanoma, *Ophthalmic Surg. Lasers Imaging* 36 (March–April (2)) (2005) 151–154.
- [12] G. Santeusano, L. Ventura, A. Mauriello, M. Carosi, L.G. Spagnoli, P. Maturo, L. Terranova, C. Romanini, Isolated ovarian metastasis from a spindle malignant melanoma of the choroid 14 years after enucleation prognostic implication of the keratin immunophenotype, *Appl. Immunohistochem. Mol. Morphol.* 8 (December (4)) (2000) 329–333.
- [13] V.E. Rey-Caballero, B. Lopez-Gonzalez, J.L. Garcia-Benitez, A. Boix-Fos, A.M. Diaz-Lagama, Solitary ovarian metastasis from ocular melanoma, *Am. J. Obstet. Gynecol.* 191 (Jul (1)) (2004) 368–369.
- [14] V.D. Mandato, B. Kobal, A. Di Stefano, J. Sinkovec, A. Levicnik, G.B. La Sala, S. Rakar, Choroidal melanoma metastasized to the ovary: case report and review of the literature, *Eur. J. Gynaecol. Oncol.* 31 (1) (2010) 109–113.
- [15] P.B. Chapman, A. Hauschild, C. Robert, J.B. Haanen, P. Ascierto, J. Larkin, R. Dummer, C. Garbe, A. Testori, M. Maio, D. Hogg, P. Lorigan, C. Lebbe, T. Jouary, D. Schadendorf, A. Ribas, S.J. O'Day, J.A. Sosman, J.M. Kirkwood, A.M. Eggermont, B. Dreno, K. Nolop, J. Li, B. Nelson, J. Hou, R.J. Lee, K.T. Flaherty, G.A. McArthur, BRIM-3 study group. Improved survival with vemurafenib in melanoma with BRAF V600E mutation, *N Engl. J. Med.* 364 (2011) 2507–2516.
- [16] K.T. Flaherty, C. Robert, P. Hersey, P. Nathan, C. Garbe, M. Milhem, L.V. Demidov, J.C. Hassel, P. Rutkowski, P. Mohr, R. Dummer, U. Trezfer, J.M. Larkin, J. Utikal, B. Dreno, M. Nyakas, M.R. Middleton, J.C. Becker, M. Casey, L.J. Sherman, F.S. Wu, D. Ouellet, A.M. Martin, K. Patel, D. Schadendorf, METRICS study group. Improved survival with MEK inhibition in BRAF-mutated melanoma, *N. Engl. J. Med.* 367 (2012) 107–114.
- [17] S.S. Agarwala, A.M. Eggermont, S. O'Day, J.S. Zager, Metastatic melanoma to the liver: a contemporary and comprehensive review of surgical, systemic, and regional therapeutic options, *Cancer* 120 (March (6)) (2014) 781–789.
- [18] T.M. Pawlik, D. Zorzi, E.K. Abdalla, B.M. Clary, J.E. Gershenwald, M.I. Ross, T.A. Aloia, S.A. Curley, L.H. Camacho, L. Capussotti, D. Elias, J.N. Vauthey, Hepatic resection for metastatic melanoma: distinct patterns of recurrence and prognosis for ocular versus cutaneous disease, *Ann Surg. Oncol.* 13 (May (5)) (2006) 712–720.
- [19] K. Gündüz, J.A. Shields, C.L. Shields, T. Sato, M.J. Mastrangelo, Surgical removal of solitary hepatic metastasis from choroidal melanoma, *Am J Ophthalmol.* 125 (March (3)) (1998) 407–409.
- [20] N. Meda, C. Cotta, D. Donnarieix, F. Bacin, Late metastases of malignant choroidal melanoma after curietherapy: two case reports, *J. Fr. Ophtalmol.* 27 (May (5)) (2004) 485–488.
- [21] K. Hosonuma, K. Sato, H. Takagi, T. Mashimo, T. Saruya, H. Takahashi, K. Horiuchi, M. Honma, M. Mori, Hepatic metastasis from choroidal malignant melanoma developing 15 years after enucleation, *Nihon Shokakibyō Gakkai Zasshi.* 102 (September (9)) (2005) 1201–1206.
- [22] R. Orlando, F. Lumachi, Late liver metastases of choroidal melanoma detected by laparoscopy, *In Vivo* 22 (November–December (6)) (2008) 807–809.

### Open Access

This article is published Open Access at [sciedirect.com](http://sciedirect.com). It is distributed under the [IJSCR Supplemental terms and conditions](#), which permits unrestricted non commercial use, distribution, and reproduction in any medium, provided the original authors and source are credited.