

Role of MDCT and VR reconstructions in the diagnosis and characterization of maxillary cystic lesions.

Poster No.: C-0704
Congress: ECR 2011
Type: Scientific Exhibit
Authors: M. Coronella¹, P. V. Foti¹, F. Arcerito², G. vasta³, V. Guarrera¹, D. Gueli², G. Scavone¹, M. CAVALLARO⁴, G. C. Ettore³; ¹Catania/IT, ²Catania (CT)/IT, ³catania/IT, ⁴CATANIA/IT
Keywords: Head and neck, CT, Computer Applications-3D, Cavitation
DOI: 10.1594/ecr2011/C-0704

Any information contained in this pdf file is automatically generated from digital material submitted to EPOS by third parties in the form of scientific presentations. References to any names, marks, products, or services of third parties or hypertext links to third-party sites or information are provided solely as a convenience to you and do not in any way constitute or imply ECR's endorsement, sponsorship or recommendation of the third party, information, product or service. ECR is not responsible for the content of these pages and does not make any representations regarding the content or accuracy of material in this file.

As per copyright regulations, any unauthorised use of the material or parts thereof as well as commercial reproduction or multiple distribution by any traditional or electronically based reproduction/publication method ist strictly prohibited.

You agree to defend, indemnify, and hold ECR harmless from and against any and all claims, damages, costs, and expenses, including attorneys' fees, arising from or related to your use of these pages.

Please note: Links to movies, ppt slideshows and any other multimedia files are not available in the pdf version of presentations.

www.myESR.org

Purpose

Many lesions that occur in the maxillary bones have a cystlike appearance both on X-ray and on CT images. These lesions develop from both odontogenic and nonodontogenic origins. Most of them are benign but some may have different degrees of destructive potential locally.

Common benign cystic lesions include periapical (radicular) cysts, follicular (dentigerous) cysts, and odontogenic keratocyst.

Benign solid tumors include ameloblastomas, odontomas, ossifying fibromas and periapical cemental dysplasia.

Because maxillary lesions have a wide range of pathologic features but similar imaging appearances, patient age at manifestation, prevalence, location, cystic or solid manifestation and effects on adjacent structures, it is very important to make a differential diagnosis.

In all of these cases MDCT scanning and Volume Rendering reconstructions are very helpful to define their location, their borders and internal architecture, their effects on adjacent structures them, making it possible to narrow the differential diagnosis.

Methods and Materials

71 patients, aged 18-75 years, underwent imaging evaluation in our department between February and September 2009. These lesions are usually asymptomatic. In most patients diagnosis was occasional, sequent to an ortopantomographic exam performed because of toothache or other reasons. These patients sequently underwent MDCT scanning, performed using a Light Speed Plus (GE) multislice CT scanner, provided with Dentascan reconstruction software. The study technique comprised preliminary antero-posterior and lateral scanograms performed with the following acquisition parameters: 120 Kv and 200 mA. The subsequent axial scans were acquired using the sequent scan protocol: thickness 1,25 mm; increment 0,6 mm; feed 3,75 mm/s, rotation time 600 ms; Pitch 0,75:1; SFOV 25 cm; matrix 512x512; reconstruction algorithm with high spatial resolution (for the bone), WW 40, WL 40, gantry inclination of 0°. CT scans were obtained with the patients in the supine position, using a head holder. The acquired data were transferred to a work-station dedicated to Dentascan reconstructions. We used the following reconstruction parameters: SFOV 12,7 cm; oblique reconstructions thickness 1:0mm; panoramic reconstructions thickness 1:0mm; WL 800; WW 3200.

We documented different kinds of cystic and cystlike lesions located in the maxillary bones: 35 inflammatory cysts, 15 medial line cysts, 12 nasopalatine duct cysts, 8 cystic ameloblastomas, 1 neoplastic cyst.

Results

Cystic and Cystlike lesion of the maxillary bones are primarily ellipsoid, radiolucent and clearly demarcated from adjacent bone. Sometimes mineralization may produce lesions with varying degrees of opacity.

Odontogenic Keratocyst

Odontogenic keratocysts are believed to arise from the dental lamina and other sources of odontogenic epithelium. They represent 5%-15% of all maxillary cysts. Most odontogenic cysts are found during the 2nd to 4th decades of life, although they can occur at any age.

At X-ray and CT scanning an odontogenic keratocyst usually appears as a unilocular radiolucent or hypoattenuated lesion with smooth corticated borders that is often associated with an impacted tooth.

Although odontogenic keratocysts are commonly located in the body and ramus of the mandibula, they may occur anywhere in the maxilla. They may have an aggressive growth, showing irregular borders and a multilocular appearance, and they can cause cortical thinning, tooth displacement and tooth resorption.

Follicular (Dentigerous) Cysts

Follicular cysts are the most common type of noninflammatory odontogenic cyst and the most common cause of a pericoronal radiolucent area associated with an impacted tooth.

A dentigerous cyst forms when fluid accumulates between the follicular epithelium and the crown of the developing or unerupted tooth. Most dentigerous cysts manifest in adolescents and young adults, often around an unerupted third molar.

These cysts are very able to expand asymptotically, displacing or resorbing adjacent teeth or bone.

At plain radiography on CT images they appear as well-defined round or ovoid, corticated, radiolucent or low-attenuating lesions around the crown of unerupted teeth.

Radicular (Periapical) Cysts

The radicular cyst are the most common maxillary cysts. They are most often seen in patients between 30 and 50 years old and usually are asymptomatic. A periapical cyst is the last step of inflammatory events following the formation of a periapical inflammatory lesion secondary to pulpal necrosis in a tooth.

At plain radiography and CT scanning they appear as round, unilocular, radiolucent or low-attenuating lesions in the periapical region. Usually they are less than 1 cm in diameter and bordered by a rim of cortical bone. The associated tooth usually has a large carious lesion. The cyst may displace adjacent teeth or cause mild root resorption (fig. 1-4).

Ameloblastoma

Ameloblastomas are benign epithelial neoplasms representing 10% of odontogenic tumours. These neoplasms develop from odontogenic epithelium, including dental follicular lining epithelium, and are locally aggressive. Typical Ameloblastoma manifests in the 3rd or 5th decades of life. Most Ameloblastomas occur in the posterior ramus of the mandible and the largest may infiltrate adjacent tissues interrupting of the bone cortex. They can vary in their radiographic appearance.

Some Ameloblastomas appear like unilocular lesions and in this case it is very difficult to distinguish them from keratocystics. Other ameloblastomas are multilocular with internal septa and honeycomb or soap bubble appearance. CT findings include cystic areas of low attenuation with isoattenuating solid regions (Fig. 5-7).

Ossifying Fibroma

Benign fibro-osseous lesions occur commonly in the jaw. Ossifying fibromas are typically encapsulated, circumscribed, benign neoplasm made up of connective tissue that contains parts of osteoid, bone, cementum and cementum-like calcified tissue.

Most ossifying can result in bone expansion with facial asymmetry.

At radiography fibromas can appear radiolucent, opaque or of mixed opacity, depending on the degree of calcifications within the mass. Lesions may appear lucent initially; if untreated they will exhibit opaque foci tending to coalesce. Initially it may be possible to observe a surrounding lucent line, representing the fibrous capsula. The latter lesion may present an a sclerotic radiopaque rim.

At CT scan they appear like low-attenuation or high-attenuation mass according their degree of calcification.

Images for this section:

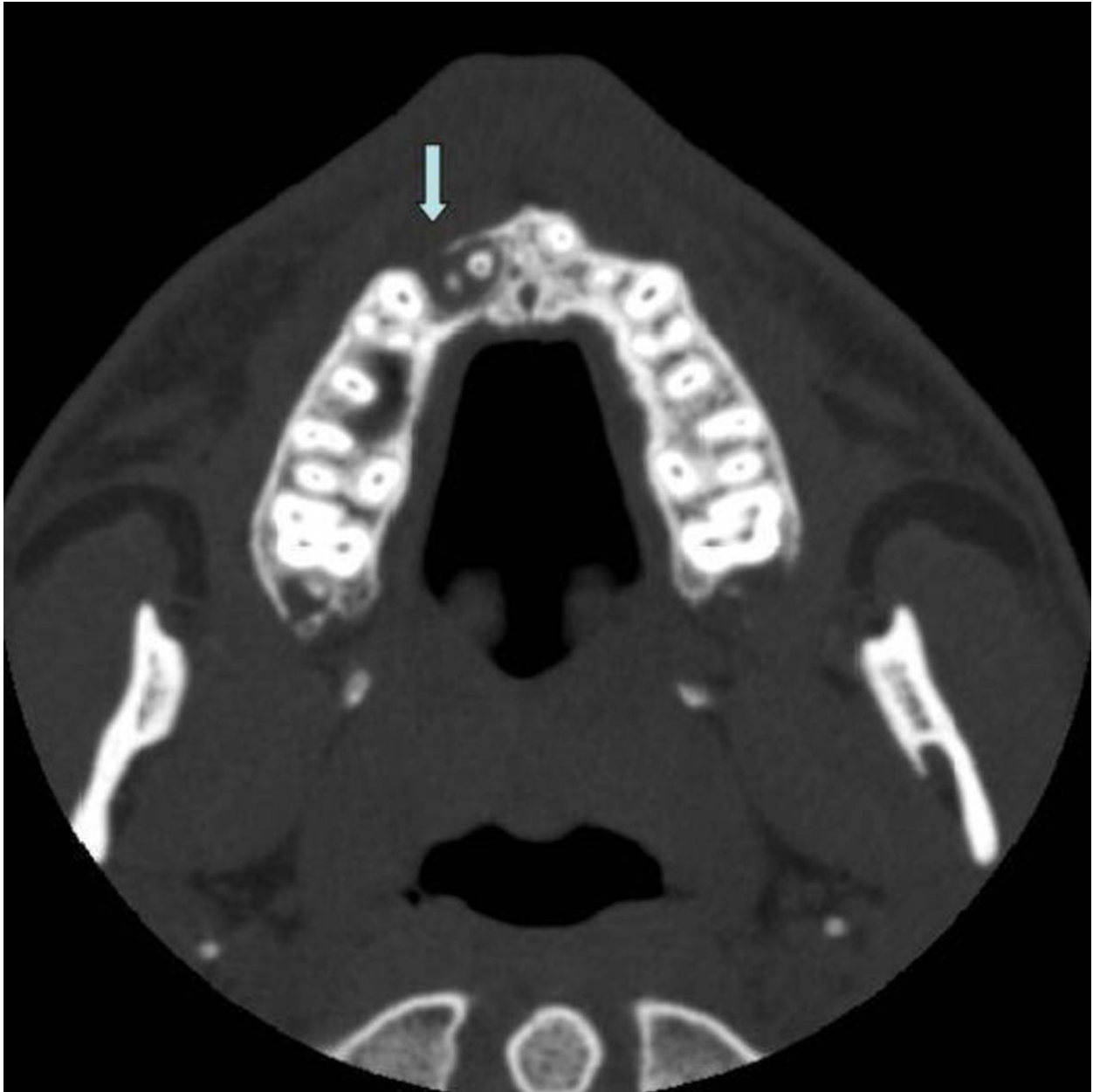

Fig. 1: Radicular cyst in a 15 year old boy. CT scan images reveal a boneless area surrounding the root apices of the superior right incisors, contiguous with the nasopalatine foramen. This cystic lesion, with a maximum diameter of 11 mm, reduces the thickness interrupting the vestibular cortical bone

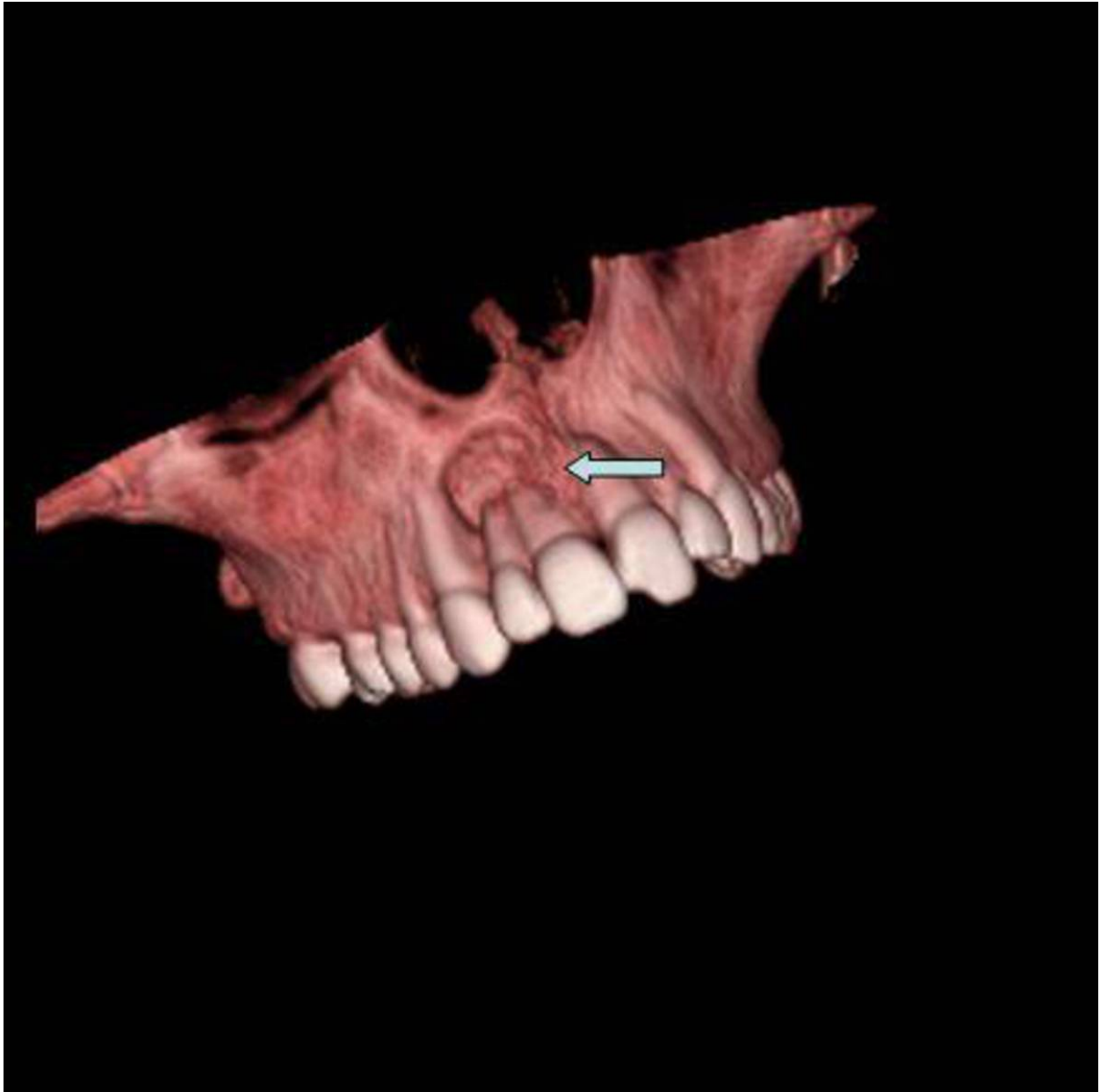


Fig. 2: Radicular cyst in a 15 year old boy. CT scan images reveal a boneless area surrounding the root apices of the superior right incisors, contiguous with the nasopalatine foramen. This cystic lesion, with a maximum diameter of 11 mm, reduces the thickness interrupting the vestibular cortical bone

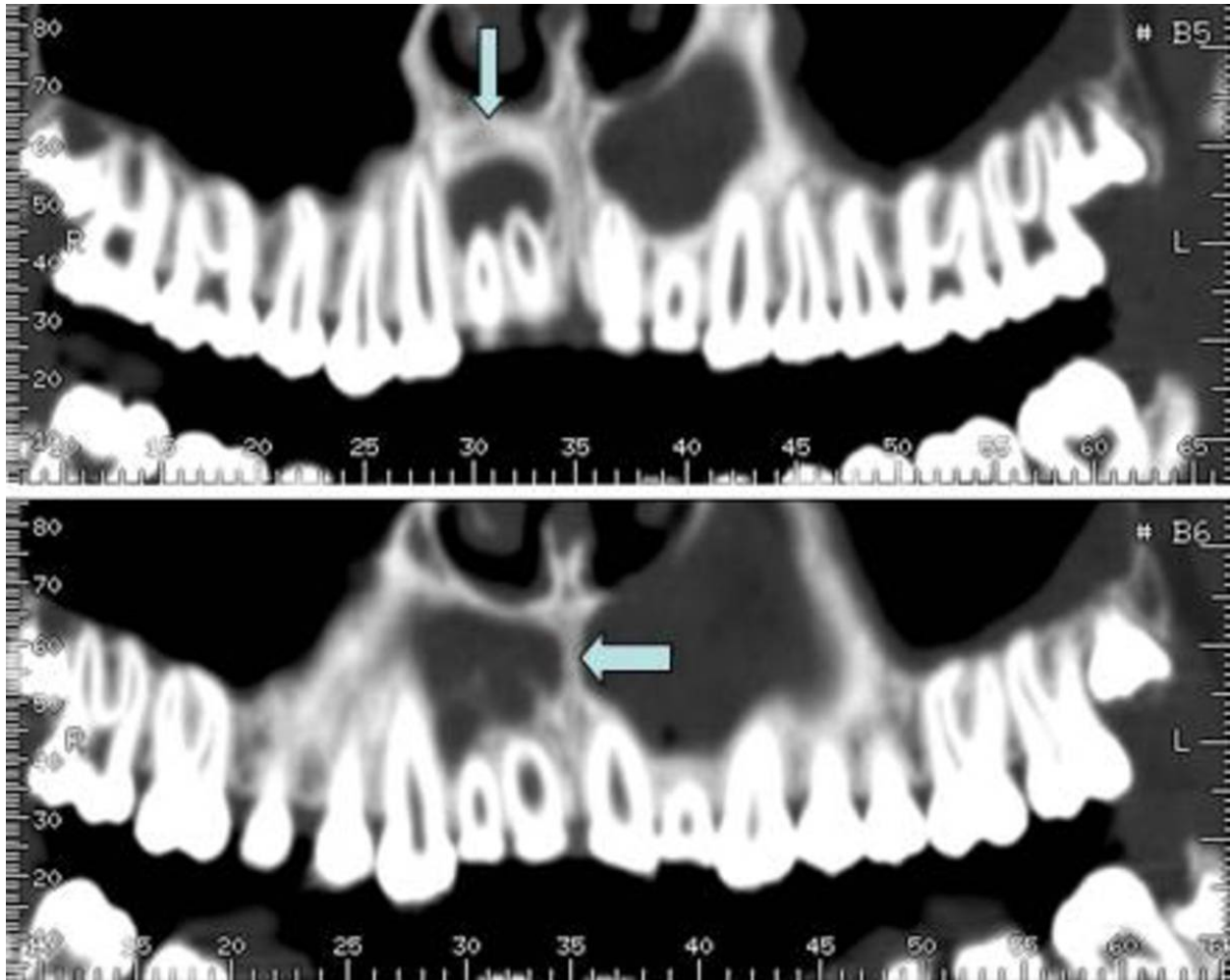


Fig. 3: Radicular cyst in a 15 year old boy. CT scan images reveal a boneless area surrounding the root apices of the superior right incisors, contiguous with the nasopalatine foramen. This cystic lesion, with a maximum diameter of 11 mm, reduces the thickness interrupting the vestibular cortical bone

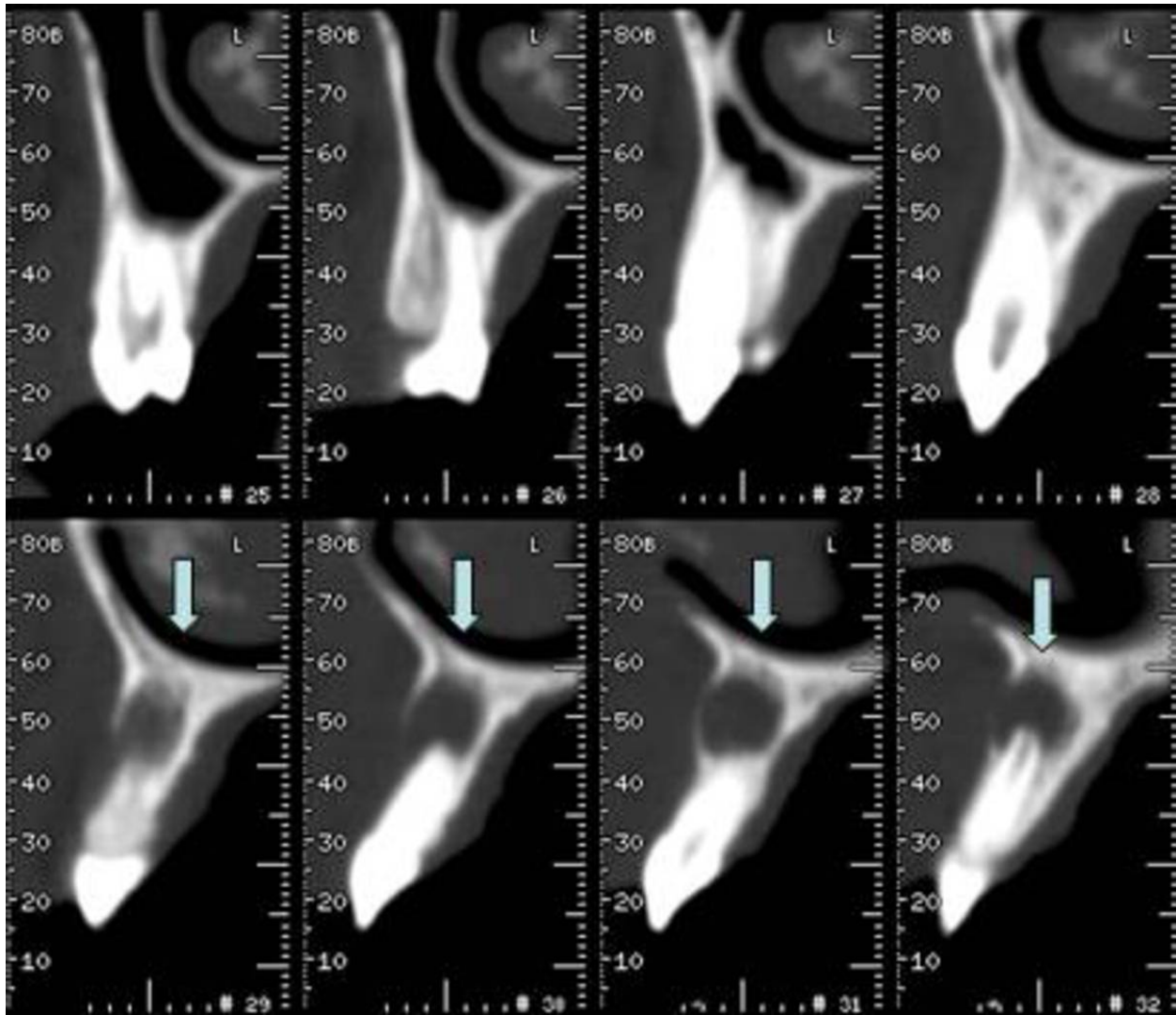


Fig. 4: Radicular cyst in a 15 year old boy. CT scan images reveal a boneless area surrounding the root apices of the superior right incisors, contiguous with the nasopalatine foramen. This cystic lesion, with a maximum diameter of 11 mm, reduces the thickness interrupting the vestibular cortical bone

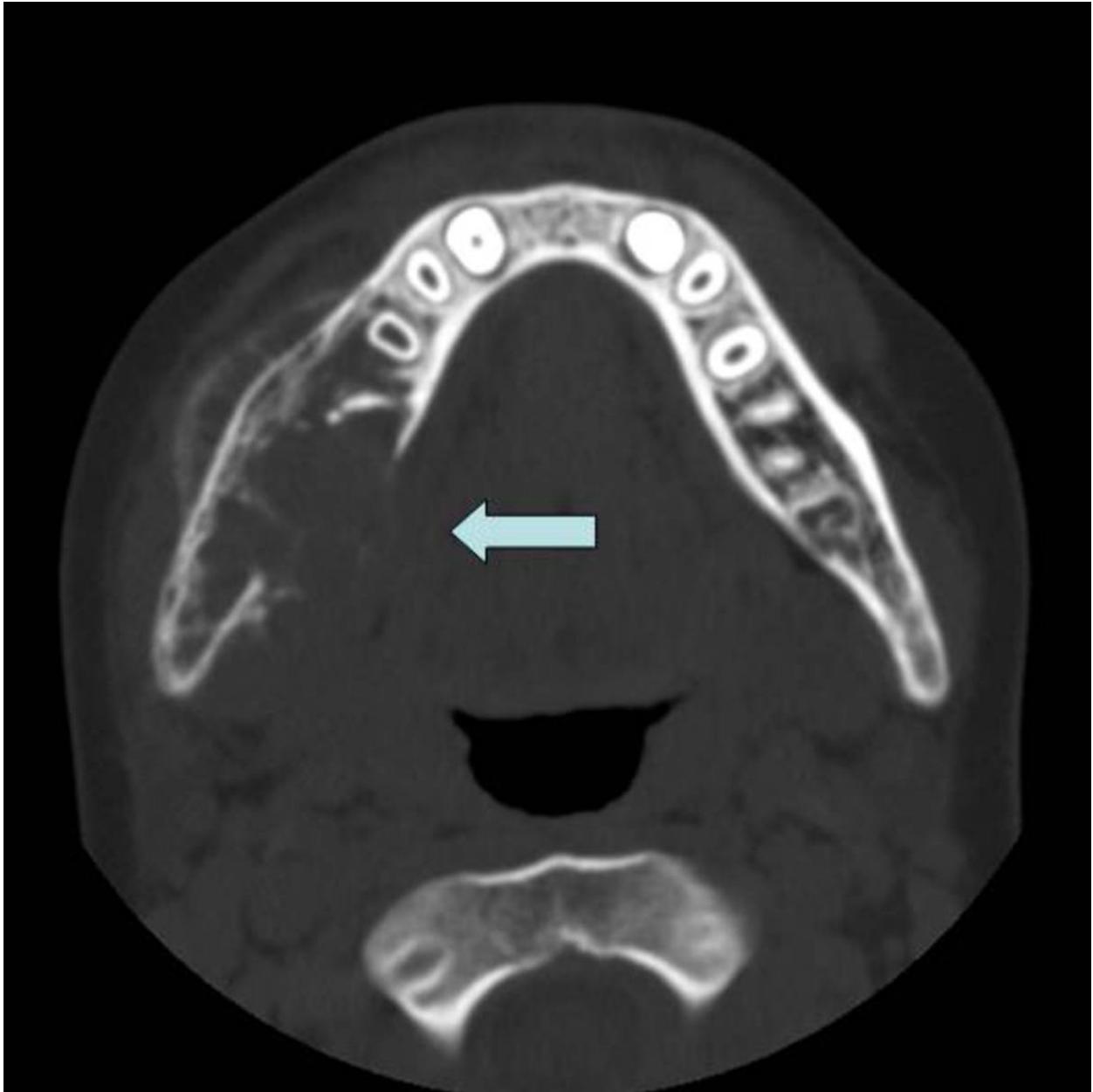


Fig. 5: Ameloblastoma in a 10-year old boy. CT axial image shows an asymmetry in the right mandibular side with the involvement of adjacent soft tissues.

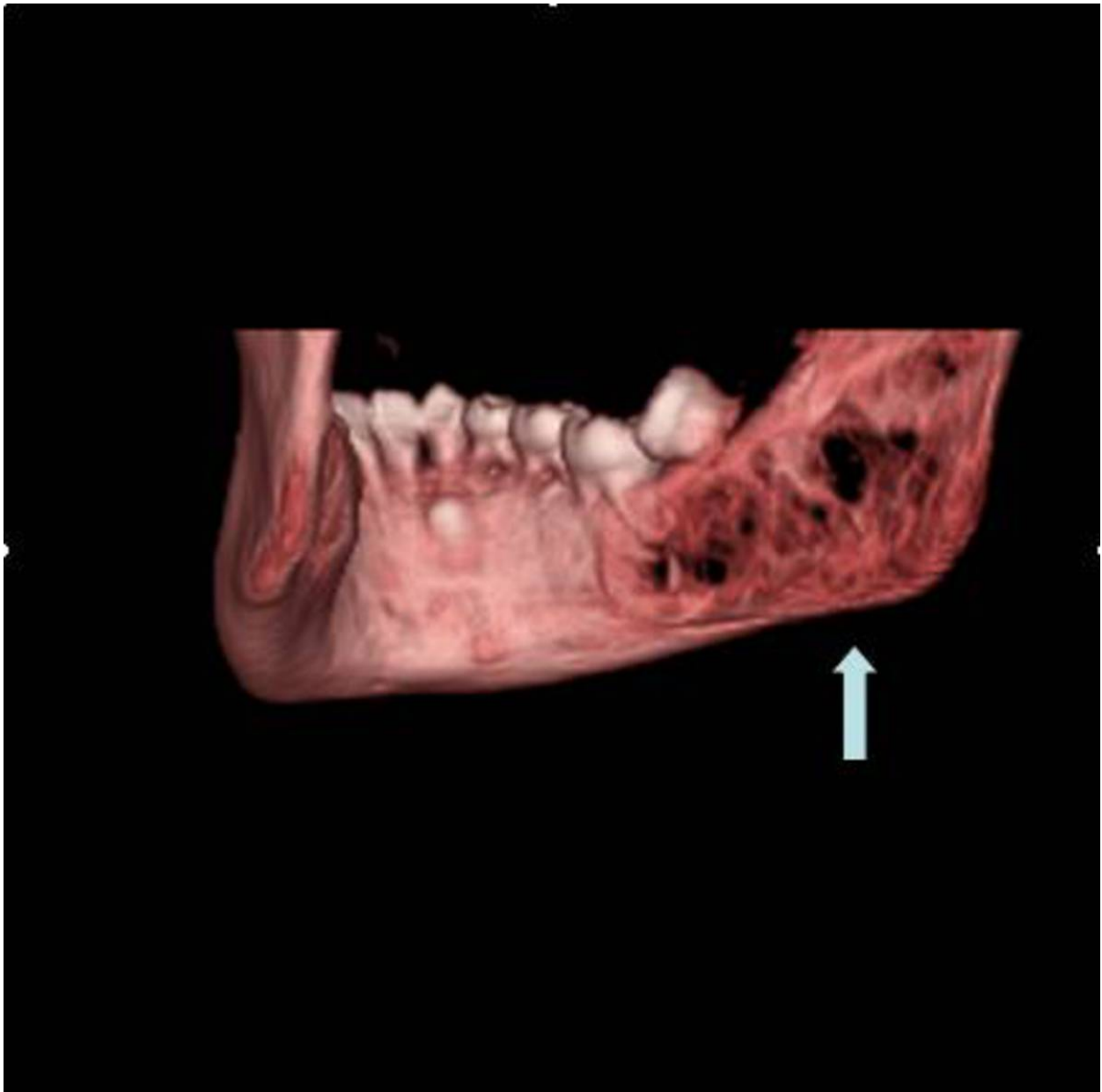


Fig. 6: 3D VR reconstruction shows in the molar-ramus region a large multilocular boneless area. This disomogeneous lesion (maximum diameter 40 mm) alters the internal bone structure which appears rarefacted and with "bubble-soap" septa.

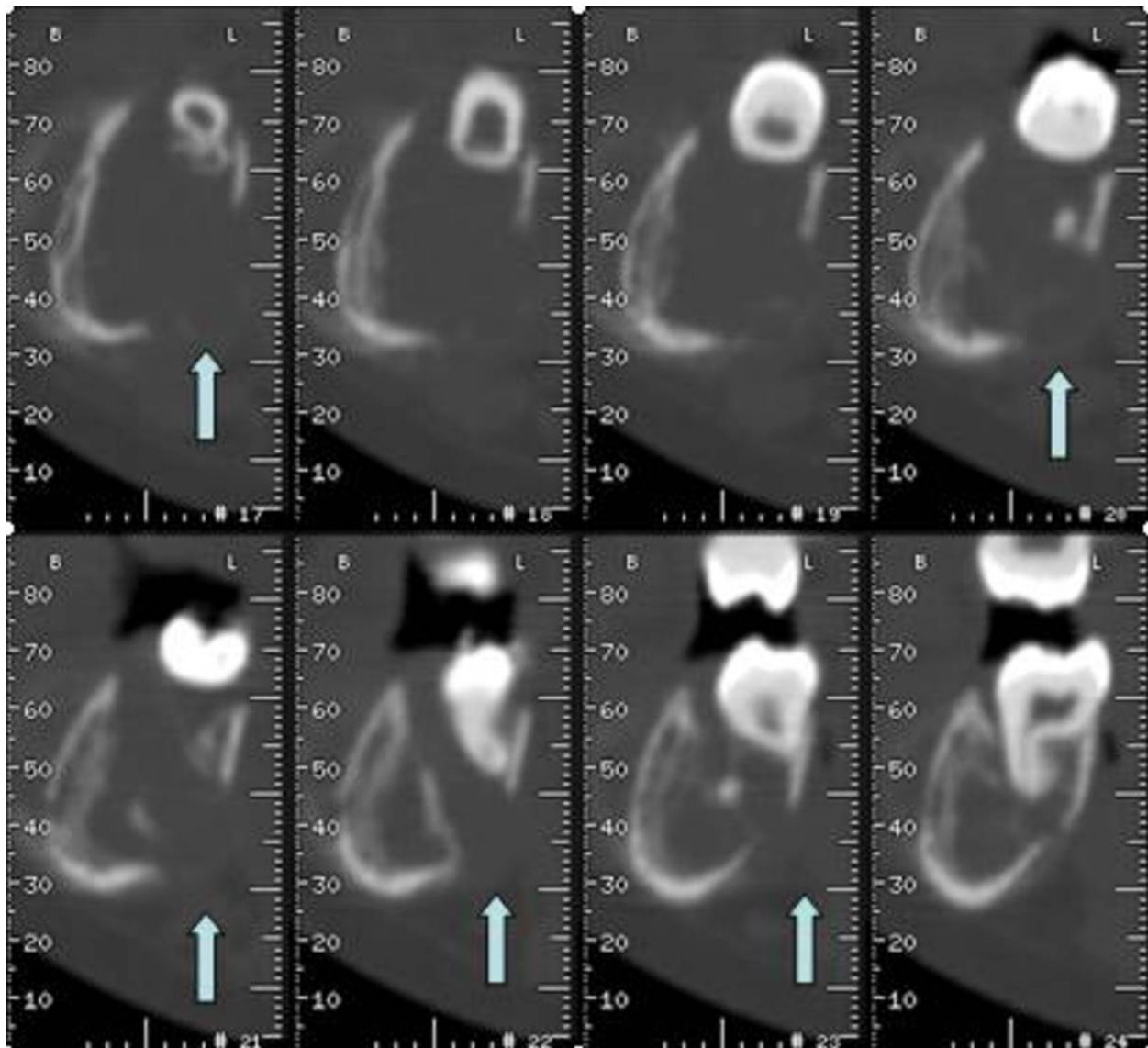


Fig. 7: In Dentascan parasagittal reconstructions we can observe that the lesion reduces the cortical thickness, swallowing the bone on both vestibular and lingual side, englobing the mandibular canal.

Conclusion

Cystic and cyst-like lesions of the maxillary bones can get similar imaging findings at X-ray scanning so they are often difficult to distinguish from one another with radiography.

Secondary imaging techniques are crucial for the differential diagnosis.

MDCT with dentaScan software and VR reconstruction are helpful to provide fundamental information about these lesions like localization, calcifications within the masses, contiguity relation with the bones and even interruption of the bone cortex, contiguity relation with nerves and other soft tissues

In most cases these lesions must be surgically removed and examined microscopically to accurately establish the diagnosis.

References

- 1) Goaz PW, White SC. Oral radiology: principles and interpretation 3rd ed. St Louis, Mo: Mosby-Year Book, 1994; 398-676.
- 2) Weber AL. Imaging of cysts and odontogenic tumors of the jaw. Radiol Clin North Am 1993; 31:101-120.
- 3) Oikarinen VJ. Keratocyst recurrences at intervals of more than 10 years: case reports. Br J Oral Maxillofac Surg 1990; 28:47-49.
- 4) Eisenberg E, Eisenbud L. Benign fibro-osseous diseases: current concepts in historical perspective. Oral Maxillofac Surg Clin North Am 1997; 9:551-561
- 5) Weber AL. Mandible. In: Som PM, eds. Head and neck imaging. 2nd ed. St Louis, Mo: Mosby-Year Book, 1991; 399.
- 6) [Raitz R](#), [Assunção Júnior JN](#), [Correa L](#), [Fenyo-Pereira M](#). Department of Biodentistry, Dental School, Ibirapuera University, São Paulo, Brazil. Parameters in panoramic radiography for differentiation of radiolucent lesions. *J Appl Oral Sci*. 2009 Sep-Oct;17(5):381-7.
- 7) [Raitz R](#), [Correa L](#), [Fenyo-Pereira M](#). Radiographic interpretation of unilocular radiolucent mandibular lesions. *Acta Odontol Latinoam*. 2009;22(2):123-8.
- 8) L. Barnes, J.W. Eveson, P. Reichart, D. Sidransky, Pathology and Genetics Of Head and Neck tumour, In: R. Kleihues, L.H Sobin, World Health Organization Classification of tumours, IARC Press; Lyon, France, 2005, pp. 299-300.

9) Rapidis AD, Andressakis DD, Stavrianos SD, et al: Ameloblastomas of the jaws: Clinicopathological review of 11 patients. Eur J Surg Oncol 30:998, 2004.

10) Bataineh A, Jordan I: Effect of preservation of the inferior borders on recurrence of ameloblastomas of the mandible. Oral Surg Oral Med Oral Pathol Oral Radiol Endod 90:155, 2000.

Personal Information