

## Microscopic and macroscopic anatomical features in healthy and osteoarthritic knee cartilage

G Musumeci<sup>1\*</sup>, P Castrogiovanni<sup>1</sup>, FM Trovato<sup>2</sup>, A Di Giunta<sup>3</sup>, C Loreto<sup>1</sup>, S Castorina<sup>1,3</sup>

### Abstract

#### Introduction

We illustrated the anatomical aspect of the cartilage in a healthy and osteoarthritic knee joint. Osteoarthritis is a disease of high ethical and economical importance. In advanced stages, the patients suffer from severe pain, restriction of mobility and inability to work. In this mini review, we described the current knowledge about the macroscopic and microscopic anatomical features in healthy and osteoarthritic knee cartilage.

#### Discussion

Adult articular cartilage has a low capacity to repair itself, and thus even minor injuries may lead to progressive damage and osteoarthritic joint degeneration, resulting in significant pain and disability. Numerous studies on human osteoarthritic tissue and in animal models have addressed the microscopic and macroscopic anatomical aspects of OA progression to get a better understanding of the pathophysiology of this disease. Further, imaging studies show the macroscopic anatomical changes and are important for the diagnosis of this disease.

#### Conclusion

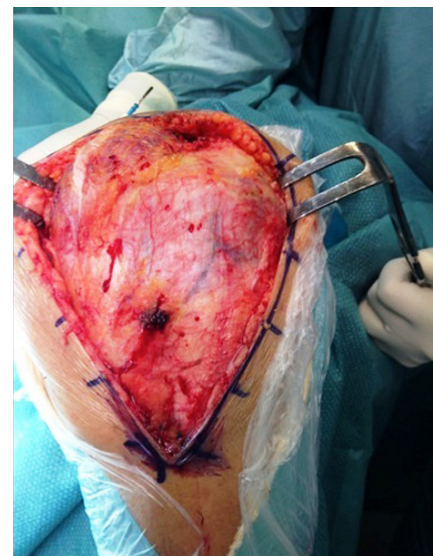
Further *in vivo* and *in vitro* studies must be carried out in order to improve the early diagnosis and the treatment of articular cartilage

defects, leading to a better clinical outcome for the patients affected.

#### Introduction

The knee joint is a relatively complex anatomical structure. The stability of this synovial (or diarthrodial) joint is maintained by a variety of ligaments and the presence of large muscle groups<sup>1</sup>. Both the femur and tibia are enclosed in a joint capsule (Figure 1) lined with synovial tissue. Between the condyles of the femur and the condylar surface of the tibia, there are two C-shaped pieces of cartilage called menisci (Figure 2), which serve as shock absorbers for the knee joint, located medially and laterally inside the joint<sup>2-4</sup>. The joint capsule of the knee is strengthened by different ligaments: the patellar ligament or patellar tendon, the lateral and medial retinaculum of the patella, the medial and lateral alar ligaments, the medial and lateral collateral ligaments, the popliteal ligaments and the anterior and posterior cruciate ligaments (ACLs and PCLs) (Figure 3). Between each muscle group, there are fluid-filled sacs called bursa and fat bodies, which reduce friction and lend added protection to the joint capsule. The knee works during normal activity such as walking or running, and even for support while standing. It can tolerate moderate stress without significant injury. However, the knee lacks support to withstand many types of injury, especially rotational forces such as those seen in many athletic activities. The most important connective tissue for the correct functioning of the knee joint is the cartilage. Cartilage is classified into three types according to the amount of its components:

elastic cartilage, hyaline cartilage and fibrocartilage<sup>5</sup>. Hyaline cartilage is a flexible connective tissue found in many areas of human and other animal bodies. It covers the opposing osseous ends of every synovial joint<sup>5-8</sup>, such as the knee joint, and it is found in the growth plate of the metaphysis<sup>9,10</sup>. Cartilage tissue has unique viscoelastic and compressive properties provided by the extracellular matrix, which is mainly composed of collagen type II and the large proteoglycan aggregate<sup>5-8</sup>. Articular cartilage is not innervated and lacks blood vessels. For this reason, knee injuries, even though minor, if involving the cartilage, may have delayed healing time. Nutrients in the synovial fluid and cellular repair components are transported to the chondrocytes by diffusion from the synovial fluid<sup>5-8</sup>. Only small defects, associated with minimal loss of matrix components, can be regenerated by hyaline cartilage.



**Figure 1:** Surgery of the left knee with joint capsule on site.

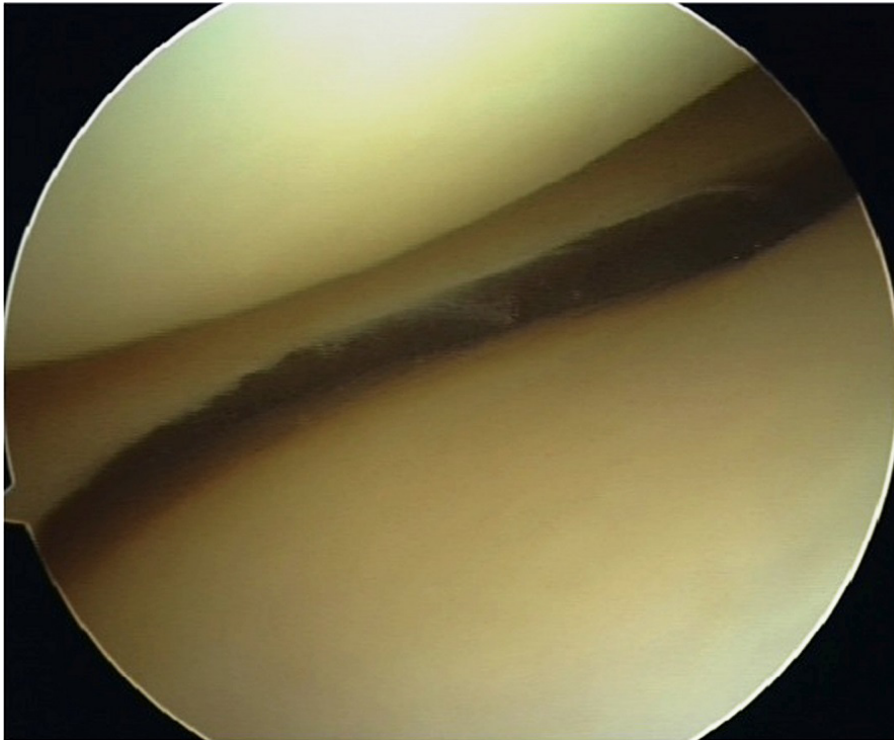
\* Corresponding Author

E-mail: g.musumeci@unict.it

<sup>1</sup> Department of Bio-Medical Sciences, Human Anatomy and Histology Division, University of Catania, Italy

<sup>2</sup> Department of Medical and Pediatric Sciences, Internal Medicine Division, University of Catania, Italy

<sup>3</sup> Fondazione Mediterranea "G.B. Morgagni", Catania, Italy



**Figure 2:** Arthroscopic image of the medial meniscus from right knee.

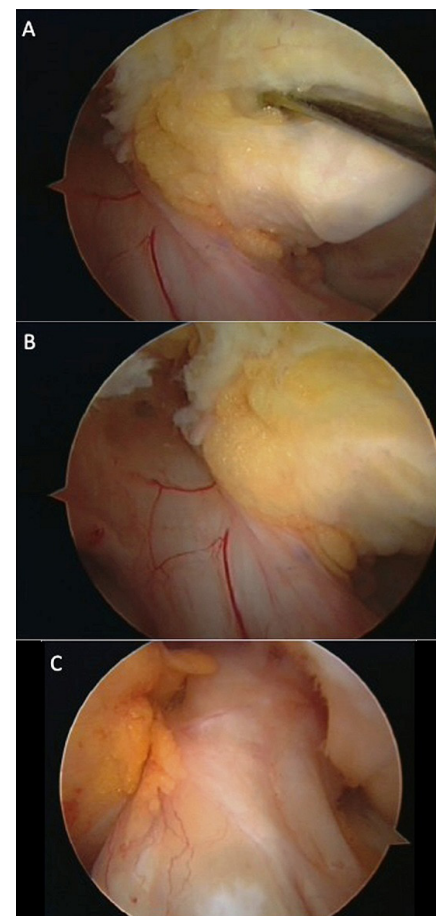
More extensive defects exceed the repair capacity, and consequently the damage becomes permanent. Osteoarthritis (OA) is a degenerative and progressive disease that leads to the loss of the structure and functionality of articular cartilage (Figure 4)<sup>11-15</sup>. There is an imbalance between anabolic and catabolic processes, but the precise mechanism of cartilage degradation in OA is still unclear, involving a complex interplay of genetic, environmental, metabolic and biochemical factors<sup>11-15</sup>. Many joints may be affected by OA; the most frequently involved joint is the knee that represents a major worldwide health problem<sup>11-15</sup>. OA is one of the most important diseases in the field of orthopaedics and is characterised by progressive loss of articular cartilage and formation of osteophytes, which lead to chronic pain and functional restrictions in the affected joints<sup>11-15</sup>. Different factors can be involved in the development of OA: mostly traumatic events are causative, but

there are other factors like genetic predisposition, defective position of joints, ageing, malnutrition, overuse and excessive body weight, which all lead to similar alterations in the joint cartilage<sup>16</sup>. Unfortunately, articular cartilage has a limited capacity for self-renewal. The regenerated tissue forming as a reaction to cartilage loss is mostly fibrous, and its mechanical capacities are significantly reduced compared to healthy hyaline cartilage. A major problem in OA research is that the disease is mostly not diagnosed until the progressed and pronounced alterations in the joint lead to pain and radiographically detectable changes<sup>17</sup>. Cartilage tissue from early-stage OA is not easily available since the disease is usually not yet clinically apparent. For this reason, a number of animal models of OA have been developed to examine the early features of cartilage degeneration<sup>11-15</sup>. While morphological and histological features of OA are well known, the underlying molecular mechanisms

are still not completely understood<sup>17</sup>. In this mini review, we described the current knowledge about the macroscopic and microscopic anatomical features in the healthy and osteoarthritic knee cartilage.

### Healthy hyaline cartilage

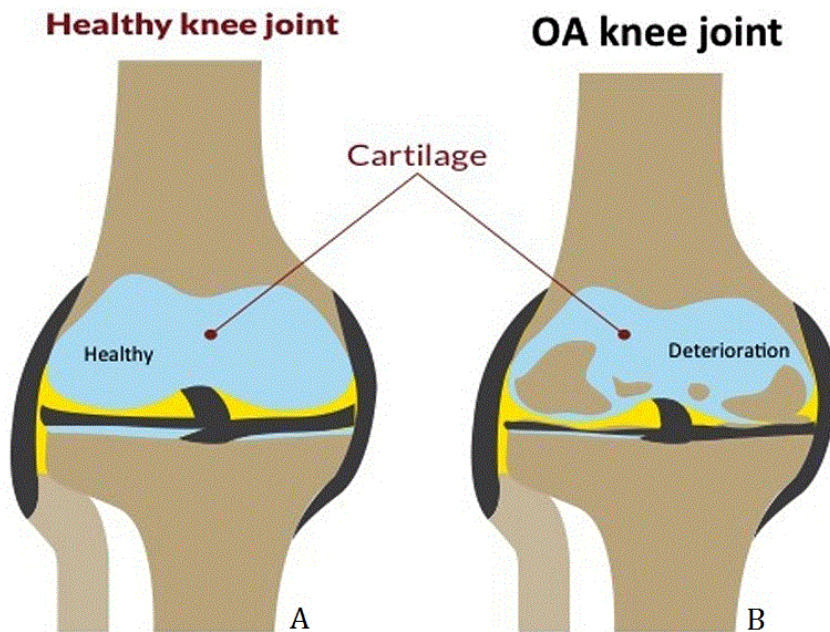
Healthy joint cartilage has a smooth surface without fissures. It is composed of four layers (Figure 5): superficial zone, intermediate zone (or middle zone), radial zone (or deep zone) and calcified cartilage zone (or calcified zone). In the superficial zone, cells are flat and spindle shaped and lie parallel to the joint surface<sup>17</sup>. Here, the collagen fibrils are also arranged



**Figure 3:** Arthroscopic images of anterior and posterior cruciate ligaments (A) ACL and PCL left knee joint. (B) ACL and PCL right knee joint. (C) ACL right knee.

Licensee OA Publishing London 2013. Creative Commons Attribution License (CC-BY)

**FOR CITATION PURPOSES:** Musumeci G, Castrogiovanni P, Trovato FM, Di Giunta A, Loreto C, Castorina S. Microscopic and macroscopic anatomical features in healthy and osteoarthritic knee cartilage. OA Anatomy 2013 Dec 01;1(3):30.



**Figure 4:** A graphic representation of the healthy cartilage (A) without signs of cartilage degeneration and OA cartilage (B) with deterioration of cartilage of the knee joint.

parallel to the surface. The superficial zone contains the highest proportion of collagen, which results in the high tensile modulus of the tissue and indicates that the main function is to resist the shear stress at the joint surface<sup>17</sup>.

The cells in the middle zone are round and form columns perpendicular to the cartilage surface, are embedded in an extracellular matrix (ECM) and characterised by randomly oriented collagen fibres<sup>17</sup>. The middle zone contains more proteoglycans, which exhibit repulsive negative charges that are neutralised by positive ions, leading to swelling pressures and its highly stable hydrated structure. The deep zone is located at the cartilage–bone interface, where the collagen fibres are aligned perpendicular to the surface. The cells are round and the columns open out to the tidemark, the border between non-calcified and calcified cartilage, which presents itself under the light optical microscope as an unbroken basophile line<sup>17</sup>. Further down, we

have first a zone of calcified cartilage and then subchondral bone.

Many healthy and untreated joints show also slight signs of cartilage degeneration like minor surface roughness and minimal fibrillation<sup>18</sup>. Histological alterations of degenerating cartilage are scored according to Mankin et al.<sup>19</sup> or a modified score by Sakakibara et al.<sup>20</sup> These scores evaluate various factors like tissue structure, cell morphology, matrix staining and appearance of the tidemark (Figure 6D). The highest possible scores meaning the most severe damage are 14 for the Mankin's score and 32 for the modified Mankin's score. Alterations to healthy joint cartilage usually do not exceed grades of 1–3<sup>21,22</sup>.

### Morphological and clinical signs of OA

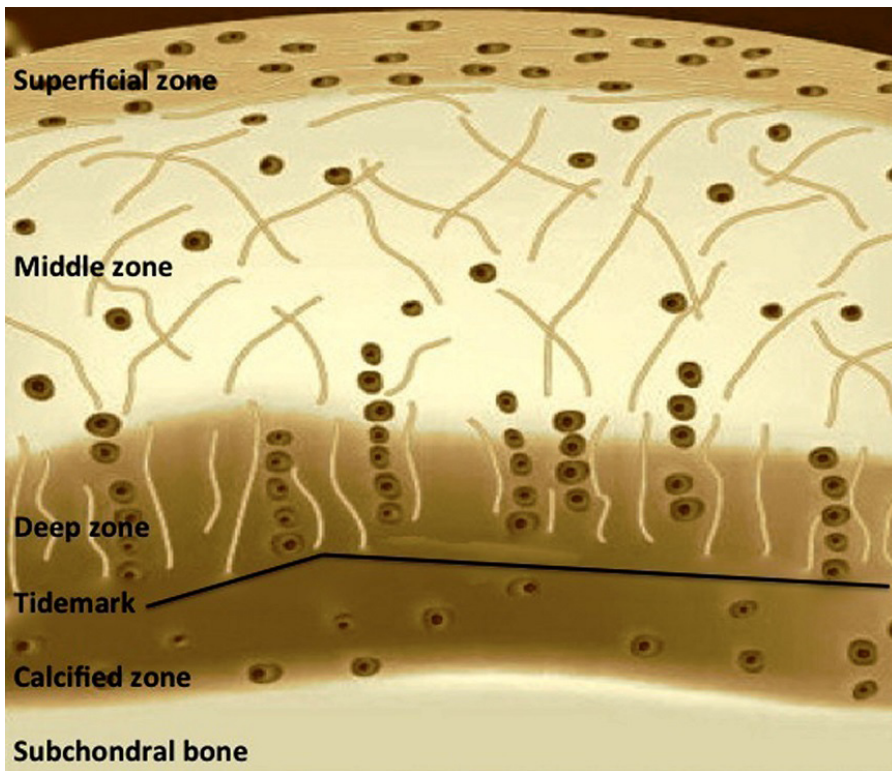
#### Microscopic aspect

While the surface of healthy hyaline cartilage (Figure 6A) appears white, shiny, elastic and firm, OA cartilage shows dull and irregular surface with

discolouration, softening and often more synovial fluid is produced<sup>23–25</sup>. Sometimes, newly invaded blood vessels can be found. Osteophytes were also found in early stages of the disease as Adams and Brandt showed<sup>25</sup> after anterior cruciate ligament transection (ACLT) in animal models, but became more pronounced in advanced stages of OA. While, in early OA, cartilage presents a thickening in line with hypertrophy, in far advanced disease stages, hypertrophic villi and full-thickness defect areas can be seen, where the cartilage is missing completely and the subchondral bone is exposed<sup>24,25</sup>. The subchondral plate itself is thicker and more dense<sup>25</sup>. Cartilage adjacent to severe OA lesions is also affected, though its degeneration seems to represent an earlier stage of disease.

At the early stage of the degeneration process (Figure 6B), minimal changes are detected in the cartilage surface, which is no longer smooth<sup>24</sup>. While glycosaminoglycans remain homogeneously distributed, mild fibrillations are found in the superficial zone<sup>26</sup>. As the disease progresses, there are changes in the cellular structure and a loss of proteoglycans shown by reduced safranin O staining<sup>18</sup>. The usually flat cells of the superficial zone first become round and hypertrophic and then disappear from the tissue. Cells of the intermediate and radial zones expose mild-to-moderate hypercellularity<sup>18,20</sup>. Multicellular chondrocyte clusters with large nuclei were found in the superficial zone, and necrotic chondrocytes with pyknotic nuclei in the intermediate and radial zones were found in experimental OA models<sup>17,27</sup>. Histological features of the OA synovial membrane include hyperplasia of synovial lining cells, thickening of the synovial membrane, infiltration of inflammatory cells and fibrosis<sup>20</sup>.

In advanced stages of OA (Figure 6C), the cartilage shows signs of complete rupture. The cartilage surface is rough and broken by fissures



**Figure 5:** Graphic representation of the healthy hyaline cartilage layers.

and cracks, which can reach down to the calcified zone<sup>28,29</sup>. Cells are arranged in clusters especially around fissures or disappear completely as the disease progresses. At the end, the organisation of cartilage is completely disordered and replaced by fibrocartilaginous, scar-like tissue with fibroblast-like cells<sup>26</sup>. In other cases, full-thickness defects develop, where the bone lacks the cartilage completely<sup>29</sup>. The loss of proteoglycan content reaches the deep zones, until the complete lack of proteoglycan, indicated by the inability of the matrix to stain for safranin O. The tidemark becomes unclear and finally is invaded by blood vessels from the subchondral bone, which penetrate into the calcified zone<sup>30</sup>. Pannus of various extent can overlay the damaged cartilage tissue<sup>23</sup>, which is described in detail by authors<sup>31</sup>. In electron microscopical analysis, researchers differentiated three cell types in OA cartilage. Type 1 cells

exhibited the normal phenotype with little endoplasmic reticulum and a homogeneous matrix<sup>17</sup>. Cells of type 2 were irregularly shaped and elongated. They were situated in a more fibrillated matrix and showed a larger amount of endoplasmic reticulum<sup>17</sup>. In the regions more affected, the authors found type 3 cells. This cell type showed pyknotic nuclei, sometimes partly dissolved cytoplasm and a strongly fibrillated surrounding matrix<sup>17</sup>.

The extent of damage to the articular cartilage seems to be highly dependent on the joint area, which can be explained by different loading conditions in distinct regions<sup>24</sup>. Authors observed the most severe changes in the medial tibial plateau of ACLT-treated rabbits<sup>21</sup>. Other authors found that the lateral tibial plateau was more strongly affected than the medial tibial plateau<sup>23</sup>. In all studies, though, the tibial plateau was more severely damaged than the

femoral condyles. The distribution pattern of cartilage defects seems to be species dependent and is supposedly dependent on the species-specific distribution of biomechanical forces.

The rate of progression seems also to be related to species and joint localisation. For example, some researchers<sup>21</sup> found a Mankin's grade of 9–10 as early as 3 weeks after ACLT in rabbits; such grades were observed in dogs not until 12 weeks after induction of OA<sup>23</sup>. Similar to macroscopic appearance, the degree of histological grading varies with the joint region analysed.

#### *Macroscopic aspect*

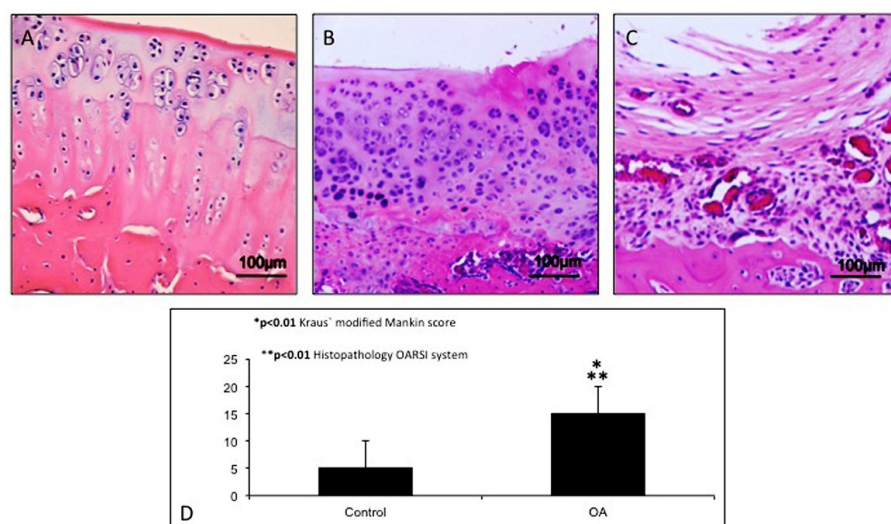
The narrowing of the joint space, the formation of osteophytes, thickening, fibrillation and cysts in the subchondral bone are radiographically visible changes. In animal models of OA, osteophytosis and subchondral sclerosis were detected radiographically 24 months after ACLT and progressed further between 2 and 3 years after ACLT<sup>32</sup>. In magnetic resonance imaging, osteophytes were also seen, the signal intensity of the menisci was altered and geodes (subchondral cyst) were detected in advanced stages<sup>31</sup>. Unfortunately, radiographs are not suitable to determine the degree of cartilage destruction<sup>26</sup>. The subchondral bone first shows bone loss in magnetic resonance imaging, which is then followed by increased bone density<sup>33</sup>.

#### *Discussion*

The authors have referenced some of their own studies in this review. These referenced studies have been conducted in accordance with the Declaration of Helsinki (1964), and the protocols of these studies have been approved by the relevant ethics committees related to the institution in which they were performed. All human subjects, in these referenced studies, gave informed consent to participate in these studies.

Licensee OA Publishing London 2013. Creative Commons Attribution License (CC-BY)

**FOR CITATION PURPOSES:** Musumeci G, Castrogiovanni P, Trovato FM, Di Giunta A, Loreto C, Castorina S. Microscopic and macroscopic anatomical features in healthy and osteoarthritic knee cartilage. OA Anatomy 2013 Dec 01;1(3):30.



**Figure 6:** (A) Microscopic signs of healthy knee hyaline cartilage. The histological (H&E staining) analysis of cartilage from a normal donor showed a preserved morphological structure with no signs of cartilage degradation. Moreover, the surface of healthy hyaline cartilage appears white, shiny, elastic and firm. Magnification  $\times 20$ ; scale bars:  $100\mu\text{m}$ . (B) Microscopic signs of OA knee hyaline cartilage. The histological (H&E staining) analysis of cartilage from OA donor demonstrated joint swelling and oedema and horizontal cleavage tears or flaps. The surface becomes dull and irregular and had minimal healing capacity. Moderate OA cartilage demonstrated structural alterations that included a reduction of cartilage thickness of the superficial and the middle zones. The structure of the collagen network is damaged, which leads to reduced thickness of the cartilage. The chondrocytes are unable to maintain their repair activity with subsequent loss of the cartilage tissue. Magnification  $\times 20$ ; scale bars:  $100\mu\text{m}$ . (C) Severe OA cartilage demonstrated deep surface clefts, disappearance of cells from the tangential zone, cloning, and a lack of cells in the intermediate and radial zones, which are not arranged in columns. The tidemark is no longer intact and the subchondral bone shows fibrillation. Magnification  $\times 20$ ; scale bars:  $100\mu\text{m}$ . (D) Analysis of histomorphometric parameters: Kraus' modified Mankin score and histopathology Osteoarthritis Research Society (OARSI) system. Both parameters confirmed the development of articular degenerative processes in OA cartilage compared to control cartilage ( $p < 0.01$ ). Data are reported as means  $\pm$  SEM. The Student's  $t$  test revealed a significant difference between control and OA cartilage ( $*p < 0.01$ ).

Adult articular cartilage has a low capacity to repair itself, and thus even minor injuries may lead to progressive damage and osteoarthritic joint degeneration, resulting in significant pain and disability. OA development takes place in consecutive steps of damage and attempted regeneration. Starting from the site of damage (e.g. for a trauma), the degeneration advances in depth and perimeter and can spread out over the whole affected

joint. Numerous studies on human osteoarthritic tissue and in animal models have addressed the microscopic and macroscopic anatomical aspects of OA progression to get a better understanding of the pathophysiology of this disease. Even if the speed of the degeneration process is highly different between species, as well as the biomechanical forces acting on the different joints, the advantage of animal models in OA studies

is definite. The data reported, however, showed that OA is a very complex disease, and it can be argued that the reasons leading to the progressive process are not finally understood. There might still be molecules involved in the process, which have not yet been studied or even identified. Though the knowledge about OA has grown enormously over the last years, possible targets for diagnosis and therapy will have to be evaluated. An interesting field of research in development is the non-invasive diagnosis of OA in body fluids like urine, serum and synovial fluid.

### Conclusion

Further *in vivo* and *in vitro* studies must be carried out in order to improve the early diagnosis and the treatment of articular cartilage defects, leading to a better clinical outcome for the patients affected.

### Acknowledgements

The study was funded by the Department of Bio-Medical Sciences, University of Catania. The authors thank Prof. Iain Halliday for commenting and making corrections to the article.

### Abbreviations list

ACLT, anterior cruciate ligament transection; ECM, extracellular matrix; OA, osteoarthritis

### References

- Blackburn TA, Craig E. Knee anatomy: a brief review. *Phys Ther*. 1980 Dec;60(12):1556–60.
- Musumeci G, Carnazza ML, Leonardi R, Loreto C. Expression of  $\beta$ -defensin-4 in “an *in vivo* and *ex vivo* model” of human osteoarthritic knee meniscus. *Knee Surg Sports Traumatol Arthrosc*. 2012 Feb;20(2):216–22.
- Musumeci G, Loreto C, Carnazza ML, Cardile V, Leonardi R. Acute injury affects lubricin expression in knee menisci. An immunohistochemical study. *Ann Anat*. 2013 Mar;195(2):151–8.
- Musumeci G, Leonardi R, Carnazza ML, Cardile V, Pichler K, Weinberg AM, et al. Aquaporin 1 (AQP1) expression in

- experimentally induced osteoarthritic knee menisci: an in vivo and in vitro study. *Tissue Cell*. 2013 Apr;45(2):145–52.
5. Musumeci G, Loreto C, Castorina S, Imbesi R, Leonardi R, Castrogiovanni P. Current concepts in the treatment of cartilage damage. A review. *Ital J Anat Embryol*. 2013;118(2):189–203.
  6. Musumeci G. The role of lubricin in normal and pathological joint tissue: A contemporary review. *OA Anatomy*. 2013 Feb;1(1):2.
  7. Musumeci G. The role of AQP1 in knee Osteoarthritis (OA): A contemporary review. *OA Arthritis*. 2013 Feb;1(1):2.
  8. Musumeci G, Loreto C, Castorina S, Imbesi R, Leonardi R, Castrogiovanni P. New perspectives in the treatment of cartilage damage. Poly(ethylene glycol) diacrylate (PEGDA) scaffold. A review. *Ital J Anat Embryol*. 2013;118(2):204–10.
  9. Pichler K, Musumeci G, Vielgut I, Martinelli E, Sadoghi P, Loreto C, et al. Towards a better understanding of bone bridge formation in the growth plate – an immunohistochemical approach. *Connect Tissue Res*. 2013;54(6):408–15.
  10. Musumeci G, Castrogiovanni P, Loreto C, Castorina S, Pichler K, Weinberg AM. Post-traumatic caspase-3 expression in the adjacent areas of growth plate injury site: a morphological study. *Int J Mol Sci*. 2013 Jul;14(8):15767–84.
  11. Musumeci G, Loreto C, Carnazza ML, Martinez G. Characterisation of apoptosis in articular cartilage derived from the knee joints of patients with osteoarthritis. *Knee Surg Sports Traumatol Arthrosc*. 2011 Feb;19(2):307–13.
  12. Musumeci G, Carnazza ML, Loreto C, Leonardi R, Loreto C.  $\beta$ -defensin-4 (HBD-4) is expressed in chondrocytes derived from normal and osteoarthritic cartilage encapsulated in PEGDA scaffold. *Acta Histochem*. 2012 Dec;114(8):805–12.
  13. Musumeci G, Loreto C, Carnazza ML, Coppolino F, Cardile V, Leonardi R. Lubricin is expressed in chondrocytes derived from osteoarthritic cartilage encapsulated in poly(ethylene glycol) diacrylate scaffold. *Eur J Histochem*. 2011;55(3):e31.
  14. Musumeci G, Loreto C, Carnazza ML, Strehin I, Elisseff J. OA cartilage derived chondrocytes encapsulated in poly(ethylene glycol) diacrylate (PEGDA) for the evaluation of cartilage restoration and apoptosis in an in vitro model. *Histol Histopathol*. 2011 Oct;26(10):1265–78.
  15. Musumeci G, Trovato FM, Pichler K, Weinberg AM, Loreto C, Castrogiovanni P. Extra-virgin olive oil diet and mild physical activity prevent cartilage degeneration in an osteoarthritis model. An “in vivo” and “in vitro” study on lubricin expression. *J Nutr Biochem*. 2013 Dec;24(12):2064–75.
  16. Swoboda B. Epidemiological arthrosis research. *Orthopade*. 2001 Nov;30(11):834–40.
  17. Lorenz H, Richter W. Osteoarthritis: cellular and molecular changes in degenerating cartilage. *Prog Histochem Cytochem*. 2006;40(3):135–63.
  18. Fernandes JC, Martel-Pelletier J, Lascau-Coman V, Moldovan F, Jovanovic D, Raynaud JP, et al. Collagenase-1 and collagenase-3 synthesis in normal and early experimental osteoarthritic canine cartilage: an immunohistochemical study. *J Rheumatol*. 1998 Aug;25(8):1585–94.
  19. Mankin HJ, Dorfman H, Lippiello L, Zarins A. Biochemical and metabolic abnormalities in articular cartilage from osteoarthritic human hips. II. Correlation of morphology with biochemical and metabolic data. *J Bone Joint Surg Am*. 1971 Apr;53(3):523–37.
  20. Sakakibara Y, Miura T, Iwata H, Kikuchi T, Yamaguchi T, Yoshimi T, et al. Effect of high-molecular-weight sodium hyaluronate on immobilised rabbit knee. *Clin Orthop Relat Res*. 1994 Feb;(299):282–92.
  21. Le Graverand MP, Eggerer J, Vignon E, Otterness IG, Barclay L, Hart DA. Assessment of specific mRNA levels in cartilage regions in a lapine model of osteoarthritis. *J Orthop Res*. 2002 May;20(3):535–44.
  22. Lippiello L, Hall D, Mankin HJ. Collagen synthesis in normal and osteoarthritic human cartilage. *J Clin Invest*. 1977 Apr;59(4):593–600.
  23. Lorenz H, Wenz W, Ivancic M, Steck E, Richter W. Early and stable upregulation of collagen type II, collagen type I and YKL40 expression levels in cartilage during early experimental osteoarthritis occurs independent of joint location and histological grading. *Arthritis Res Ther*. 2005;7(1):R156–65.
  24. McDevitt C, Gilbertson E, Muir H. An experimental model of osteoarthritis; early morphological and biochemical changes. *J Bone Joint Surg Br*. 1977 Feb;59(1):24–35.
  25. Adams ME, Brandt KD. Hypertrophic repair of canine articular cartilage in osteoarthritis after anterior cruciate ligament transection. *J Rheumatol*. 1991 Mar;18(3):428–35.
  26. Miosge N, Hartmann M, Maelicke C, Herken R. Expression of collagen type I and type II in consecutive stages of human osteoarthritis. *Histochem Cell Biol*. 2004 Sep;122(3):229–36.
  27. Marijnissen AC, van Roermund PM, Verzijl N, TeKoppele JM, Bijlsma JW, Lafeber FP. Steady progression of osteoarthritic features in the canine groove model. *Osteoarthritis Cartilage*. 2002 Apr;10(4):282–9.
  28. Veje K, Hyllested-Winge JL, Ostergaard K. Topographic and zonal distribution of tenascin in human articular cartilage from femoral heads: normal versus mild and severe osteoarthritis. *Osteoarthritis Cartilage*. 2003 Mar;11(3):217–27.
  29. Pfander D, Rahmzadeh R, Scheller EE. Presence and distribution of collagen II, collagen I, fibronectin, and tenascin in rabbit normal and osteoarthritic cartilage. *J Rheumatol*. 1999 Feb;26(2):386–94.
  30. Hayami T, Funaki H, Yaoeda K, Mitui K, Yamagiwa H, Tokunaga K, et al. Expression of the cartilage derived antiangiogenic factor chondromodulin-I decreases in the early stage of experimental osteoarthritis. *J Rheumatol*. 2003 Oct;30(10):2207–17.
  31. Shibakawa A, Aoki H, Masuko-Hongo K, Kato T, Tanaka M, Nishioka K, et al. Presence of pannus-like tissue on osteoarthritic cartilage and its histological character. *Osteoarthritis Cartilage*. 2003 Feb;11(2):133–40.
  32. Brandt KD, Braunstein EM, Visco DM, O'Connor B, Heck D, Albrecht M. Anterior (cranial) cruciate ligament transection in the dog: a bona fide model of osteoarthritis, not merely of cartilage injury and repair. *J Rheumatol*. 1991 Mar;18(3):436–46.
  33. Pastoureau PC, Chomel AC, Bonnet J. Evidence of early subchondral bone changes in the meniscectomised guinea pig. A densitometric study using dual-energy X-ray absorptiometry subregional analysis. *Osteoarthritis Cartilage*. 1999 Sep;7(5):466–73.

Licensee OA Publishing London 2013. Creative Commons Attribution License (CC-BY)

**FOR CITATION PURPOSES:** Musumeci G, Castrogiovanni P, Trovato FM, Di Giunta A, Loreto C, Castorina S. Microscopic and macroscopic anatomical features in healthy and osteoarthritic knee cartilage. *OA Anatomy* 2013 Dec 01;1(3):30.