

See discussions, stats, and author profiles for this publication at: <https://www.researchgate.net/publication/317766368>

Combination of amplatzer vascular plug 4 in occlusion of the left vertebral artery, with microspheres plus coils for embolization of...

Article in EuroMediterranean Biomedical Journal · January 2017

DOI: 10.3269/1970-5492.2017.12.13

CITATIONS

0

READS

13

7 authors, including:



[Nunzio Maria Angelo Rinzivillo](#)

University of Catania

6 PUBLICATIONS 2 CITATIONS

[SEE PROFILE](#)



[Guido Nicola Zanghi](#)

University of Catania

57 PUBLICATIONS 194 CITATIONS

[SEE PROFILE](#)

COMBINATION OF AMPLATZER VASCULAR PLUG 4 IN OCCLUSION OF THE LEFT VERTEBRAL ARTERY, WITH MICROSPHERES PLUS COILS FOR EMBOLIZATION OF THE DEEP CERVICAL BRANCHES FOR PRESURGICAL TREATMENT OF A HYPERVASCULAR C-5 METASTASIS: CASE REPORT AND REVIEW OF THE LITERATURE.

Antonio Basile¹, Serafino Maria Santonocito¹, Giuseppe Arturo Caltabiano¹, Marco Vittorio Pizzarelli¹, Salvatore Cicero², Nunzio Maria Angelo Rinzivillo³, [Guido Nicola Zanghì](#)³.

1. Garibaldi Centro Hospital, Radiology Department, Catania, Italy

2. Garibaldi Centro Hospital, Neurosurgery Department, Catania, Italy

3. Policlinic Vittorio Emanuele University Hospital, Surgery Department, University of Catania, Italy

ARTICLE INFO

Article history:

Received 12 January 2017

Revised 25 February 2017

Accepted 16 April 2017

Keywords:

Angiography; interventional-neuro; embolization; oncology; vertebral arteries.

ABSTRACT

Clinical use of Amplatzer Vascular Plug in central and peripheral vascular system has been extensively described in the literature. We present a case of occlusion of left vertebral artery (LVA) performed by deploying an Amplatzer Vascular Plug, in addition to microspheres plus coils for embolization of the deep cervical branches that feed a cervical metastasis involving the left VA. After the endovascular intervention, the patient underwent surgical resection of the lesion.

The application of the device, the use of multiple embolic materials, as well as the angiographic and clinical results of the procedure, were evaluated because not previously reported in the literature.

Hence, we provide an updated literature review about clinical use of Amplatzer Vascular Plug in supra-aortic vessels.

© EuroMediterranean Biomedical Journal 2017

1. Introduction

Clinical use of Amplatzer Vascular Plug in central and peripheral vascular systems has been extensively described in literature [1–6].

Therapeutic sacrifice of carotid artery (CA) or vertebral artery (VA) is a common and well-established endovascular procedure in the treatment of several cerebral pathologies, such as aneurysms or vascular malformations [7, 8]. This procedure is also potentially indicated preoperatively for reducing blood flow to head, neck or skull base neoplasms [9, 10].

In this article, we present a case of combined therapy for C5 vertebral metastasis involving the left VA, through VA sacrifice performed by inserting two Amplatzer Vascular Plugs 4 (a self-expanding nitinol mesh occlusion device) in the deep cervical branches, and microspheres plus coils for embolization, followed by surgical resection. Based on our research, this application of AVP 4 with embolization has not been previously described.

2. Case Report

A patient in her 50s was admitted to our Institution with a history of resistant low back pain for 6 months. She has undergone a multidetector computed tomography angiography (MDCTA) of the abdomen. A renal cell carcinoma was diagnosed, with a unique hyper-vascular cervical metastasis localized in C5 vertebral body (maximum diameter of 3 cm) with more than 50% compression of the spinal canal, and involvement of the left VA and C6 body as well (Figure 1 a and b). The Patient presented neck pain and limited neck rotation, forced to wear a collar, without any sign of neurologic deficit. Cervical spine MRI with gadolinium was performed as a diagnostic tool. After a multi-disciplinary evaluation, the patient was scheduled for pre-operative VA sacrifice plus deep cervical embolization of the branches feeding the metastasis (to reduce surgical blood loss), and neurosurgery intervention (total vertebrectomy of C5, and partial somatectomy of C6). Other treatment options, such as percutaneous augmentation or radiotherapy were excluded respectively,

* Corresponding author: Antonio Basile, antodoc@yahoo.com

DOI: 10.3269/1970-5492.2017.12.13

All rights reserved. ISSN: 2279-7165 - Available on-line at www.embj.org

due to the high risk of cement leakage, and the high risk of vertebral fracture, which would need immediate stabilization.

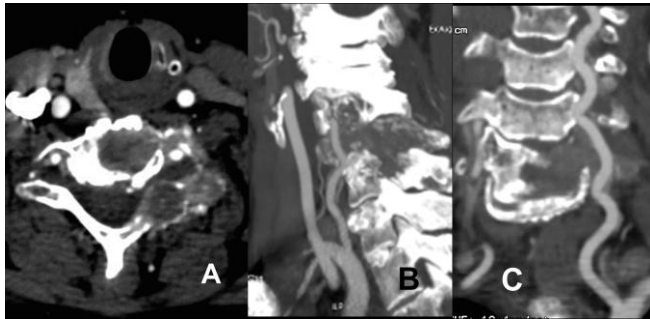


Figure 1 a and b - CT axial (a) and sagittal (b) images showing the C5 osteolytic metastasis involving the left VA, C5 body and partially C6.

3. Endovascular treatment

Before VA sacrifice, and after informed consent was signed, we performed the angiography and the fundamental angiographic balloon test occlusion (BTO). The BTO of the VA was performed with evaluation of either the blood velocity or blood flow direction in the ipsi-lateral P1 segments of the posterior cerebral artery. However, the most important criterion for passing the BTO was clinical [11].

The occlusion of the VA was achieved by deploying two AVP 4 into the distal and proximal extracranial portion of the vessel, through a 5Fr vertebral shaped catheter (Figure 2).

After the sacrifice of VA, the complete angiography demonstrated that the lesion was still fed by deep cervical branches; thus, embolization of the deep cervical branches feeding the lesion was performed with an additional procedure by using microspheres (300-500 μ m, Embozene® CeloNovaBioSciences, Germany) and micro-coils (Detach-18, Cook Medical, Denmark) (Figure 3 a and b). We decided to use microspheres because they are described as the best device in preoperative embolization of bone neoplasms; they also presented decreased chances of bleeding related to the delay time between embolization and surgery [12].

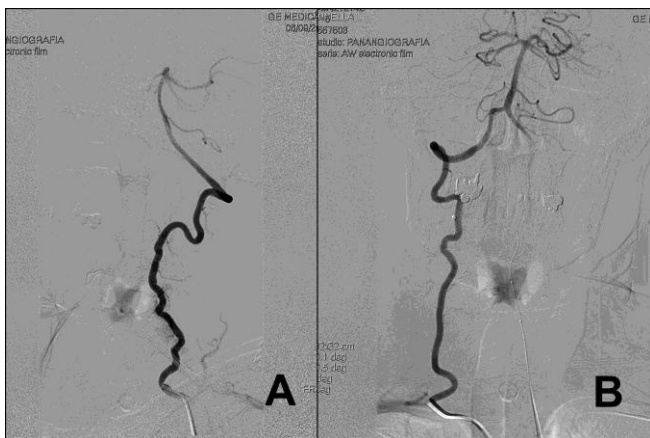


Figure 2 - Angiographic image showing the total occlusion of the left VA with two AVP 4.

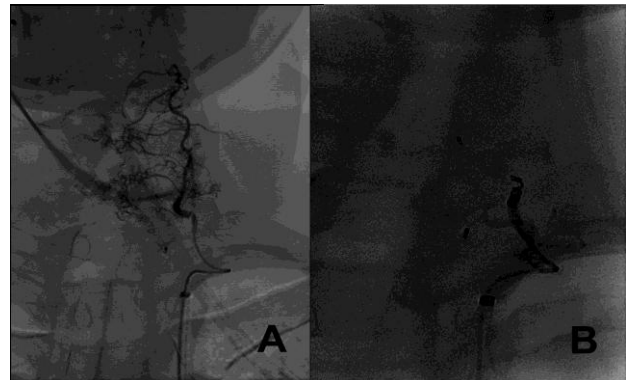


Figure 3 a and b - Selective angiography of deep cervical branches feeding the metastasis (a); post-embolization (microspheres plus coils) control (b).

4. Neurosurgical treatment

The patient finally underwent surgical resection of the lesion. The neurosurgeon decided to perform total vertebrectomy of C5 and partial somatectomy of C6. The surgery was performed in a single session, first by an anterior access and then by a posterior one. Vertebral bodies were replaced with titanium meshes and Poly-methyl-methacrylate (PMMA), plus a plate with intersomatic screws from C4 to C7. A heterologous dura mater patch was positioned in the site of somatectomy to mark the boundaries with superior and lateral anatomic structures (carotid arteries, esophagus and trachea). Finally, a posterior arthrodesis with titanium screws and bars was performed from C4 to C7. Surgery lasted approximately 20 hours, mainly due to the tumor's hard texture. The tumor removal was total without obvious signs of infiltration of the surrounding soft tissues (Figure 4). Histopathology verified metastasis of renal cancer

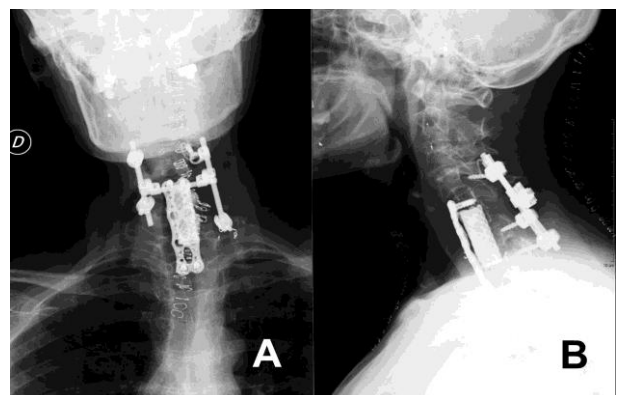


Figure 4 - CT sagittal reconstruction image showing the results of neurosurgical intervention.

5. Post-operative

After surgery, the patient had a mono-paresis of the left upper limb, a functional deficit of the C5-C6 nerve root and disappearance of post-operative pain. 15 days after neurosurgery, the patient underwent a left nephrectomy and then the removal of the primary tumor. The 6-month follow-up underlined an improvement of the mono-paresis and the patient was autonomous. The x-ray confirmed cervical alignment (Figure 4). The 6-month follow-up staging showed absence of disease progression.

6. Discussion

The sacrifice of supra-aortic trunks is contemplated for treatment of some encephalopathies such as aneurysms or vascular malformations [7, 8]. Endovascular embolization is a valid solution for therapeutic sacrifice of a major craniocerebral artery, because it offers some clear advantages over direct surgical ligation in terms of less invasiveness, morbidity and complications [10, 13, 14]. During the past decades, these surgeries were performed using detachable latex and silicone balloons, and subsequently with coils [12-16].

Coils were preferred over balloons to avoid possible complications, such as premature unintended detachment, and because detachable balloons were withdrawn from the market and are currently unavailable in many countries [7, 15, 18]. Coils provide a much less stable anchorage on the vessel wall and may be prone to migration and potentially create thromboembolic complications [15]. For these reasons, we gained experience from the literature with the use of AVP in neurovascular interventions; this device is easy to use, giving the possibility to resheath and reposition it for a precise placement and no risk of distal migration. Furthermore, the advent of AVP 4 and its possibility to be deployed within a 4-5 Fr diagnostic catheter, with a more delicate delivery system, permits to overcome some limitations of older versions, and the low navigability through tortuous vascular segments [6, 19]. The use of AVP 4 is extensively treated in literature. Many authors described in detail the peripheral embolization achieved by using AVP between 2005 and 2008 [2-6, 20, 21]. First publications on AVP neuro-applications date back to 2006 [9, 18, 22]. In the literature, there are 18 articles with 59 reported cases of AVP application in CAs or VAs or the thyrocervical trunk [1, 7-10, 15, 17-19, 23-33]; 1 case was cited in 2 different articles [17, 32], so we reported on a total of 58 patients.

In 46 cases, CAs were occluded: n=18 aneurysms or pseudoaneurysms (n=22 AVP I, n=7 AVP II, n=2 AVP 4) [1, 7-10, 15, 18, 23, 25-27, 32]; n=6 blowout syndrome (n=12 AVP I, n= 3 AVP II) [1, 8, 16]; n=8 arteriovenous fistula (AVF) (n=5 AVP I, n=5 AVP II, n=1 AVP III, n=5 AVP 4) [1, 10, 15, 24, 25, 31, 31]; n=7 preoperative for head and neck tumors (n=9 AVP I, n=2 AVP II, n=4 AVP 4) [9, 10, 32]; n=4 internal CA occlusion for hemorrhage (n=4 AVP I, n=4 AVP II, n=1 AVP 4) [25, 32]; n=1 palliative to reduce hemorrhagic risk (n=2 AVP 4) [9]; n=1 preoperative for vessel reconstruction (n=6 AVP I) [7]; n=1 for iatrogenic injury (n=2 AVP II) [32]. In all cases the ICA was treated. In 3 cases of traumatic AVF, in 1 case of pediatric congenital AVF and in 1 case of blowout syndrome, the external CA, the common CA and the facial artery were the sites for AVP deployment [1, 17, 30, 31].

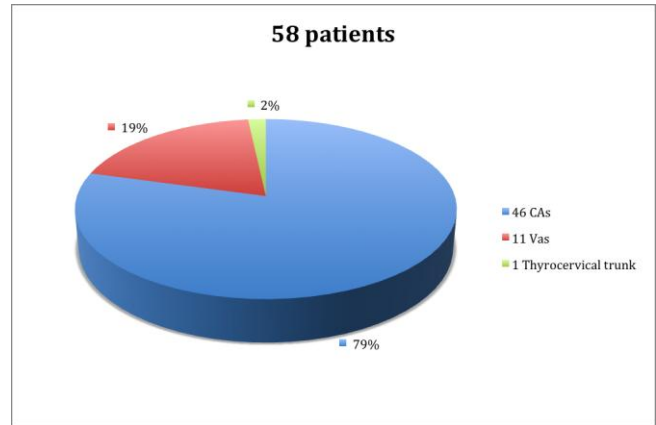


Figure 5 - Site's distribution

	n/N (%)
• CAs	46/58 (79)
Aneurysms or Pseudoaneurysms	18/58 (31)
Blowout syndrome	6/58 (10.3)
Arteriovenous fistula	8/58 (13.7)
Preoperative for H and N tumors	7/58 (12)
Occlusion for ICA hemorrhage	4/58 (6.9)
Palliative	1/58 (1.7)
Preoperative for vessel reconstruction	1/58 (1.7)
Iatrogenic injury	1/58 (1.7)
• VAs	11/58 (19)
Arteriovenous fistula	5/58 (8.6)
Preoperative for H&N tumors	4/58 (6.9)
Dissecting Aneurysms	1/58 (1.7)
Sub-arachnoid hemorrhage for aneurysm	1/58 (1.7)
• Thyrocervical Trunk (Pseudoaneurysm)	1/58 (1.7)*

* this value was approximate to 2% in the graph

Table 1 - Use of AVP in Supra-aortic Trunks

In n=11 cases, the VA was occluded: n=2 AVF between VA and internal jugular vein (n=2 AVP II) [25]; n=2 AVF between VA and vertebral vein (n=4 AVP I) [8, 29]; n=4 preoperative for head and neck tumors (n=8 AVP I, n=2 AVP II, n=2 AVP 4) [10, 25, 32]; n=1 dissecting aneurysm involving the origin of the posterior-inferior cerebellar artery (n=1 AVP I) [18]; n=1 to prevent endoleak in a stent-graft treatment on a traumatic subclavian AVF with pseudoaneurysm formation (n=1 AVP 4) [28]; n=1 sub-arachnoid hemorrhage for dissecting aneurysm (n= 2 AVP II) [32].

In n=1 case the thyrocervical trunk was treated for traumatic pseudoaneurysm (n=1 AVP 4) [1] (graphic 1, table 1).

In some cases, AVPs were used to obtain a more successful occlusion of the parent artery as an aid to the coils, when they were not totally occlusive by themselves [1, 10, 18, 25, 32, 33], but often they have been used unaccompanied [1, 8, 9, 17].

Only in 1 case AVP I, was used as an anchoring scaffold for coil-mediated parent vessel occlusion [18], and in 1 case it was combined with Onyx® (ev3, Irvine, CA) in an ICA aneurysm [27]. In only 1 case AVP 4 was deployed in a VA to prevent endoleak in a stent-graft treatment on a traumatic subclavian AVF with pseudoaneurysm formation [28], and in just 1 case AVP 1 was deployed in a pediatric patient for a congenital carotid-cavernous fistula [32, 34].

7. Conclusion

VP is an easy-to-use, effective and immediate (and then very useful in emergency situations) device for vessel occlusion.

In our case, the occlusion of the VA with the AVP 4 was combined with the embolization of deep cervical branches by using microspheres and coils. This application of both AVP 4 VA sacrifice with microspheres plus coils for embolization of the deep cervical branches, has not been previously described in the literature.

References

1. Guneyli S, Cinar C, Bozkaya H, Parildar M, Oran I. Applications of the Amplatzer Vascular Plug to various vascular lesions. *Diagn Interv Radiol* 2014.
2. Ferro C, Rossi UG, Bovio G, Petrocelli F, Seitun S. The Amplatzer vascular plug 4: preliminary experience. *Cardiovasc Intervent Radiol*. 2010; 33(4):844-8.
3. Laganà D, Carrafiello G, Mangini M, et al. Indications for the use of the Amplatzer vascular plug in interventional radiology. *Radiol Med* 2008; 113:707-18.
4. Rossi M, Rebonato A, Greco L, et al. A new device for vascular embolization: report on case of two pulmonary arteriovenous fistulas embolization using the amplatzer vascular plug. *Cardiovasc Intervent Radiol*. 2006; 29(5):902-6.
5. Leanza V, Zanghì G, Vecchio R, Leanza G. How to prevent mesh erosion in trans obturator tension-free incontinence cystocele treatment (TICT) : a comparative survey. *Journal Surgery Vol. 36, N. 1*, pag. 21-25, 2015.
6. Wang W, Li H, Tam MD, Zhou D, Wang DX, Spain J. The amplatzer vascular plug: a review of the device and its clinical applications. *Cardiovasc Intervent Radiol*. 2012; 35(4):725-40.
7. Geyik S, Cil BE, Yavuz K, Peynircioglu B, Saatci I, Cekirge S. Neuroapplication of Amplatzer vascular plug: a novel device for parent artery occlusion. *Neuroradiology*. 2008;50(2):179-83.
8. Ross IB, Buciu R. The vascular plug: a new device for parent artery occlusion. *AJNR Am J Neuroradiol* 2007; 28: 385-6
9. Macht S, Mathys C, Schipper J, Turowski B. Initial experiences with the Amplatzer Vascular Plug 4 for permanent occlusion of the internal carotid artery in the skull base in patients with head and neck tumors. *Neuroradiology*. 2012; 54(1):61-4.
10. Ong CK, Lam DV, Ong MT, Power MA, Parkinson RJ, Wenderoth JD. Neuroapplication of amplatzer vascular plug for therapeutic sacrifice of major cranio cerebral arteries: an initial clinical experience. *Ann Acad Med Singapore*. 2009; 38(9):763-8.
11. Sorteberg A, Bakke SJ, Boysen M, Sorteberg W. Angiographic balloon test occlusion and therapeutic sacrifice of major arteries to the brain. *Neurosurgery* 2008; 63:651-61.
12. Basile A, Rand T, Lomoschitz F, et al. Trisacryl gelatin microspheres versus polyvinyl alcohol particles in the preoperative embolization of bone neoplasms. *Cardiovasc Intervent Radiol*. 2004 Sep-Oct;27(5):495-502.
13. Leanza V, Zanghì G, Leanza G, Leanza A. A specific application of two psychological measures on pelvic organ prolapse patients. *Giornale Italiano di Ostetricia e Ginecologia Vol. XXXIV-N. 2*, pag. 82-86, 2015.
14. van der Schaarf IC, Brilstra EH, Buskens E, Rinkel GJ. Endovascular treatment of aneurysms in the cavernous sinus. A systematic review on balloon occlusion of the parent vessel and embolization with coils. *Stroke* 2002; 33:313-8.
15. Gralla J, Schroth G, Kickuth R, El-Koussy M, Do DD, Brekenfeld C. Closing the gap between coil and balloon in the neurointerventional armamentarium? Initial clinical experience with a nitinol vascular occlusion plug. *Neuroradiology* 2008; 50:709-14.
16. Graves VB, Perl J 2nd, Strother CM, Wallace RC, Kesava PP, Masaryk TJ. Endovascular occlusion of the carotid or vertebral artery with temporary proximal flow arrest and microcoils: clinical results. *AJNR Am J Neuroradiol*. 1997 Aug;18(7):1201-6.
17. Shankar JJ, Maloney WJ, Vandorpe R. Amplatzer vascular plug for occlusion of parent artery in carotid blowout with active extravasation. *Interv Neuroradiol*. 2011; 17(2):224-7.
18. Hoit DA, Schirmer CM, Malek AM. Use of the Amplatzer vascular plug as an anchoring scaffold for coil-mediated parent vessel occlusion: technical case report. *Neurosurgery*. 2006; 59(Suppl 1):ONSE171-2.
19. Yıldız AE, Peynircioğlu B, Cil BE. Applications of the Amplatzer Vascular Plug 4. *Diagn Interv Radiol*. 2012 Mar-Apr;18(2):225-30.
20. Farra H, Balzer DT. Transcatheter occlusion of a large pulmonary arteriovenous malformation using the Amplatzer vascular plug. *Pediatr Cardiol*. 2005; 26(5):683-685.
21. Çil B, Peynircioğlu B, Canyığıt M, Geyik S, Ciftçi T. Peripheral vascular applications of the Amplatzer vascular plug. *Diagn Interv Radiol*. 2008;14(1):35-9.
22. Tuite DJ, Kessel DO, Nicholson AA, Patel JV, McPherson SJ, Shaw DR. Initial clinical experience using the Amplatzer Vascular Plug. *Cardiovasc Intervent Radiol* 2007; 30:650-4.
23. Mangini M, Laganà D, Fontana F, et al. Use of Amplatzer Vascular Plug (AVP) in emergency embolisation: preliminary experience and review of literature. *Emerg Radiol*. 2008; 15(3):153-60.
24. Mordasini P, Schroth G, Brekenfeld C, Fung C, Hoppe H, Gralla J. Endovascular treatment of a traumatic direct carotid-cavernous fistula using the Amplatzer Vascular Plug II. *J Endovasc Ther*. 2010;17(4):564-8.
25. Mihlon F, Agrawal A, Nimjee SM, et al. Enhanced, Rapid Occlusion of Carotid and Vertebral Arteries Using the AMPLATZER Vascular Plug II Device: The Duke Cerebrovascular Center Experience in 8 Patients with 22 AMPLATZER Vascular Plug II Devices. *World Neurosurg*. 2015;83(1):62-8.

26. Scott DA, Keston P, White P, Sellar R. [Vascular plug for ICA occlusion in cavernous carotid aneurysms: technical note. *Neuroradiology*. 2008; 50\(9\):795-8.](#)
27. Schirmer CM, Hoit DA, Malek AM. [Amplatzer-onyx sandwich: a method for impermeable proximal cerebral vessel occlusion. *J Vasc Interv Radiol* 2008; 19\(3\):459-60.](#)
28. Peynircioglu B, Yurttutan N, Gulek B, Cil B, Yilmaz M. [Vertebral artery occlusion with Amplatzer vascular plug 4 to prevent subsequent endoleak in stent-graft treatment of subclavian artery gunshot injury. *Acta Radiol*. 2011; 52\(8\):850-8533.](#)
29. Crowley RW, Medel R, Dumont AS. [Traumatic high flow vertebral-venous fistula presenting with delayed ischemic stroke: endovascular management with detachable coils and Amplatzer Vascular Plugs. *Neurosurg Focus*. 2009;26\(3\).](#)
30. Hodgkinson JD, Cheshire N, Bicknell C, Hamady M. [A novel endovascular treatment for long-standing high-flow arteriovenous fistula. *J Vasc Surg*. 2015; 61\(5\):1321-3.](#)
31. Tanidir IC, Odemiş E, Güzeltaş A, Akdeniz C. [Percutaneous embolization of a carotico azygous fistula with the Amplatzer Vascular Plug 1. *Diagn Interv Radiol*. 2012;18\(4\):431-4.](#)
32. Banfield JC, Shankar JJ. [Amplatzer vascular plug for rapid vessel occlusion in interventional neuroradiology. *Interv Neuroradiol*. 2016; 22\(1\):116-21.](#)
33. Zanghi G, Di Stefano G, Caponnetto A, Vecchio R, la Naia A, La Terra A, Leanza V, Basile F. [Breast cancer and sentinel lymph node micrometastases: indications for lymphadenectomy and literature review. *Journal Surgery* Vol. 35, N. 11/12, pag. 260-65, 2014.](#)
34. Cacopardo B, Pinzone M, Berretta S, Fisichella R, Di Vita M, Zanghi G, Cappellani A, Nunnari G, Zanghi A. [Localized and systemic bacterial infection in necrotizing pancreatitis submitted to surgical necrosectomy or percutaneous drainage of necrotic secretions. *BMC Surg*. 13, Suppl.2, S50, 2013.](#)