

QUIZ SECTION

A Painful Nodule on the Leg: A Quiz

Fernando Cammisuli¹, Vito Catania¹, Maria Rita Nasca^{2*}, Andrea Failla¹ and Giuseppe Micali²

¹Department of Surgical Science, Transplant and Advanced Technologies Unit, and ²Dermatology Clinic, University of Catania, A.O.U. "Policlinico – Vittorio Emanuele", P.O. "Gaspere Rodolico", Via S. Sofia 78, IT-95123 Catania, Italy. *E-mail: nasca@policlinico.unict.it mnasca@fastwebnet.it

A 55-year-old Caucasian farmer presented with a 1-year history of a slowly enlarging nodule on his right leg. His family history and past medical history was unremarkable. The patient believed that the lesion had been caused by accidental penetration of a foreign body into the skin. At onset, the lesion was very small and painless, but later on its size increased and it became painful. Symptoms were unresponsive to non-steroidal anti-inflammatory drugs. At physical examination, a raised reddish, mobile multinodular plaque, with irregular borders, of about 1 cm in diameter, with a small crust surrounded by a whitish scale, was

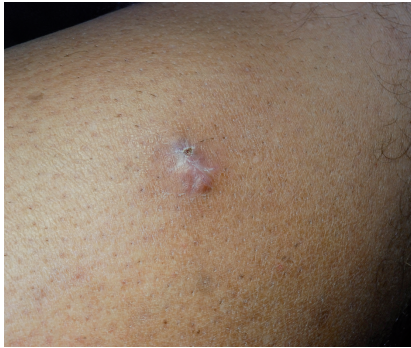

Fig. 1. Indurated, painful multinodular plaque located on the shin.

evident on the anterior surface of the leg (Fig. 1). Blood tests, also including tumour markers, were negative. The lesion was surgically excised and examined histologically (Fig. 2). The lesion extended beyond the resection margins. Immunohistochemistry was positive for Desmin, Smooth Muscle Actin (SMA), and H-Caldesmon, and negative for S-100 protein, CD34, and cytokeratins.

What is your diagnosis? See next page for answer.

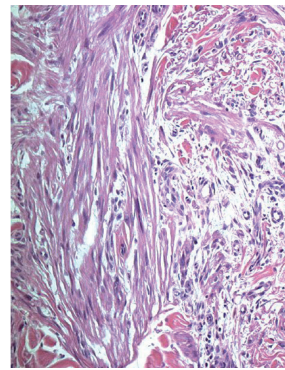


Fig. 2. Atypical proliferation of interlacing fascicles of markedly pleomorphic spindle cells in the dermis. Atypical cells with large eosinophilic cytoplasm and nuclear atypia. (Haematoxylin-Eosin stain: $\times 100$).

ANSWERS TO QUIZ

A Painful Nodule On The Leg: A Comment

Acta Derm Venereol 2015; 95: 633–635

Diagnosis: Low-grade cutaneous pilar leiomyosarcoma

Leiomyosarcomas (LMSs) represent about 5–10% of all sarcomas of soft tissues, which, in turn, account for only 0.7% of malignant tumours (1–3). Cutaneous LMSs may arise from cutaneous or subcutaneous tissue (4). Cutaneous pilar LMSs are painful neoplasms, which take origin from the arrectori pili muscle (5) and represent about 2–3% of all soft tissue sarcomas (6), with an overall incidence of 0.04%. Their anatomic localisation varies widely, but presentation on distal limbs is typical (7). They generally achieve a size of about 2 cm in diameter and clinically appear as tender skin-coloured and raised nodules that may sometimes develop central depressions (6) or ulcerations (4). Histopathology shows atypical eosinophilic spindle cells arranged in bundles or nests, with tumour grade defined according to tumour differentiation (size, cellularity, atypia), necrosis, and mitotic count (1, 5, 6). Subcutaneous involvement, albeit minimal, should always be carefully sought (8).

Unlike subcutaneous LMSs, that tend to be high-grade neoplasms and to achieve larger size, with a 50–70% recurrence risk and a 30% incidence of metastases (6), cutaneous LMSs are usually staged as low grade in about 71% of cases (compared to 18% only of the subcutaneous ones), tend to grow slowly and are usually confined to the dermis. Rate of local recurrence is about 30–50%. Metastases are rarely found and tumour-related death is unlikely. For these reasons, the denomination of “sarcoma” for this distinct clinical entity has recently been debated, and the term of “atypical intradermal smooth muscle neoplasm” has been suggested (9). Proper identification of the clinical subtype, beyond the assessment of local tumour extension and presence of metastases, is therefore essential in order to reliably predict a tentative prognostic evaluation.

Radical surgical excision remains the mainstay of treatment, whereas radiation therapy or chemotherapy should be reserved to palliation and for the management of metastatic disease. In the case we described, histological features and positive resection margins prompted a

subsequent surgical reexcision to assure complete local tumour clearance; in addition, a total body CT scan was performed in order to exclude the presence of distant metastases. During follow-up, which consisted of yearly clinical follow-up visits and CT scan, no local relapses or distant metastases were evident at 24 months.

The authors declare no conflict of interest.

REFERENCES

1. Abraham JA, Weaver MJ, Hornick JL, Zurakowski D, Ready JE. Outcomes and prognostic factors for a consecutive case series of 115 patients with somatic leiomyosarcoma. *J Bone Joint Surg Am* 2012; 94: 736–744.
2. Catania V, Consoli A, Cavallaro A, Liardo RL, Malaguarnera M. The neo-adjuvant treatment in gastrointestinal stromal tumor. *Eur Rev Med Pharmacol Sci* 2010; 14: 727–730.
3. Uccello M, Malaguarnera M, Giordano M, Leggio E, Catania VE, Consoli AS, et al. A large calcified retroperitoneal extraskeletal osteosarcoma with consequent bilateral hydronephrosis. *Eur Rev Med Pharmacol Sci* 2012; 16: 977–982.
4. Berzal-Cantalejo F, Sabater-Marco V, Pérez-Vallés A, Martorell-Cebollada M. Desmoplastic cutaneous leiomyosarcoma: case report and review of the literature. *J Cutan Pathol* 2006; 33: 29–31.
5. Fons ME, Bachhuber T, Plaza JA. Cutaneous leiomyosarcoma originating in a symplastic pilar leiomyoma: a rare occurrence and potential diagnostic pitfall. *J Cutan Pathol* 2011; 38: 49–53.
6. Fauth CT, Bruecks AK, Temple W, Arlette JP, DiFrancesco LM. Superficial leiomyosarcoma: a clinicopathologic review and update. *J Cutan Pathol* 2010; 37: 269–276.
7. Hashimoto H, Daimaru Y, Tsuneyoshi M, Enjoji M. Leiomyosarcoma of the external soft tissues. A clinicopathologic, immunohistochemical, and electron microscopic study. *Cancer* 1986; 57: 2077–2088.
8. Massi D, Franchi A, Alos L, Cook M, Di Palma S, Enguita AB, et al. Primary cutaneous leiomyosarcoma: clinicopathological analysis of 36 cases. *Histopathology* 2010; 56: 251–262.
9. Kraft S, Fletcher CD. Atypical intradermal smooth muscle neoplasms: clinicopathologic analysis of 84 cases and a reappraisal of cutaneous “leiomyosarcoma”. *Am J Surg Pathol* 2011; 35: 599–607.