

Pancreatitis Is a Silent Killer in Peritoneal Dialysis With Difficult Diagnostic Approach

Roberta Aliotta*, Luca Zanolì*, Itria Lauretta, Rosa Giunta, Silvia Ferrario, Stefania Rastelli, Sebastiano Rapisarda, Elnaz Rahbari and Francesco Rapisarda

Section of Nephrology, Department of Clinical and Experimental Medicine, Policlinico Universitario, University of Catania, Catania, Italy.

Clinical Medicine Insights: Case Reports
Volume 11: 1–5
© The Author(s) 2018
Reprints and permissions:
sagepub.co.uk/journalsPermissions.nav
DOI: 10.1177/1179547618765761



ABSTRACT: Until 2018, 236 cases of acute pancreatitis have been reported in patients who underwent peritoneal dialysis. Here, we presented a patient with double renal transplantation with chronic renal failure, under renal replacement therapy by peritoneal dialysis, who developed acute pancreatitis with abdominal pain, nausea, vomiting, leukocytosis with neutrophil left shift which is complicated by pancreatic pseudocyst, candida peritonitis, fungal sepsis, overlapping of *Acinetobacter baumannii* sepsis, and pneumonitis. After the percutaneous cystogastrostomy drainage of pancreatic pseudocyst, changes from peritoneal dialysis to hemodialysis, various thoracentesis, and polyantibiotics therapy, the resolution of the sepsis state was seen. The particular aspect of our case is the various comorbidity risks, severe pancreatitis associated with candida and *A baumannii* sepsis, and treatment strategy that lead to heal this kind of the high mortality rate condition.

KEYWORDS: Pancreatitis, pancreatic pseudocyst, peritonitis, sepsis

RECEIVED: November 19, 2017. **ACCEPTED:** February 26, 2018.

TYPE: Case Report

FUNDING: The author(s) received no financial support for the research, authorship, and/or publication of this article.

DECLARATION OF CONFLICTING INTERESTS: The author(s) declared no potential conflicts of interest with respect to the research, authorship, and/or publication of this article.

CORRESPONDING AUTHOR: Luca Zanolì, Section of Nephrology, Department of Clinical and Experimental Medicine, Policlinico Universitario, University of Catania, Via Santa Sofia 78, 95123 Catania, Italy. Email: zanolì.rastelli@gmail.com

Introduction

A search of the current literature was performed using the PubMed database which let us to take 168 articles, analyzing them and adding others from bibliography database, we obtained 236 cases of pancreatitis in peritoneal dialysis (PD) (17 case reports,^{1–17} 5 case series,^{18–22} 11 population-based studies^{23–33}).

In 15 articles it was documented the concomitance of peritonitis, from databases with reached that only 25 from 44 patients had concomitance peritonitis in PD.

Fungal infection is common in patients on PD. Peritonitis is an important complication of the PD; only in some cases the fungal peritonitis is recognized but with 15%–45% of mortality rate.³⁴

The clinical features of pancreatitis in patients with chronic kidney disease are no different from those in the general population. The only exception is the coexistence of peritonitis and pancreatitis which is clinically difficult to differentiate.²⁵

The incidence of acute and chronic pancreatitis is increased in PD for the high level of uremic toxin, local hypercalcemia, and toxicity of peritoneal dialysate.^{2,3} In these patients, the diagnosis is based on the clinical and radiological evaluations because of the altered level of pancreatic enzyme in PD. More often, acute pancreatitis is associated with complete healing without complications, but can complicate to pseudocyst formation in some other cases, which in some condition may require drainage intervention. Until now, there is no specific

treatment guideline for pancreatitis in PD, so we handled our case initially with empiric therapy and ensuing according to the dialysis liquid and blood culture results. The peculiarity of this case is represented by numerous morbidities that the patient developed simultaneously, with the genesis of a complex clinical picture, by the combination of infections due to *Candida albicans* and *Acinetobacter baumannii*.

Case Report

A 54-year-old woman was hospitalized for abdominal pain, nausea, vomiting, anorexia, and fever, in poor clinical condition, with fever, and unstable hemodynamic state.

Past medical history of the patient is as follows:

- Hepatitis C virus positive;
- Chronic glomerulonephritis caused by glomerulonephritis of unknown cause in 2002, on hemodialysis from 2007 to 2012, failure of first renal transplantation in 2008 for acute rejection, failure of second transplantation from living donor in 2012 for acute rejection, successive start of hemodialysis, and interrupted after 1 year for vascular access problems. On February 2013, peritoneal dialysis catheter was placed.
- Secondary hyperparathyroidism;
- Steno-obstructive vasculopathy, percutaneous transluminal angioplasty in subclavian vein on January 2013;
- Hypertension;
- Recently, she was hospitalized for acute pancreatitis, treated with antibiotics, and consequently temporarily

*R. A. and L. Z contributed equally to this work.



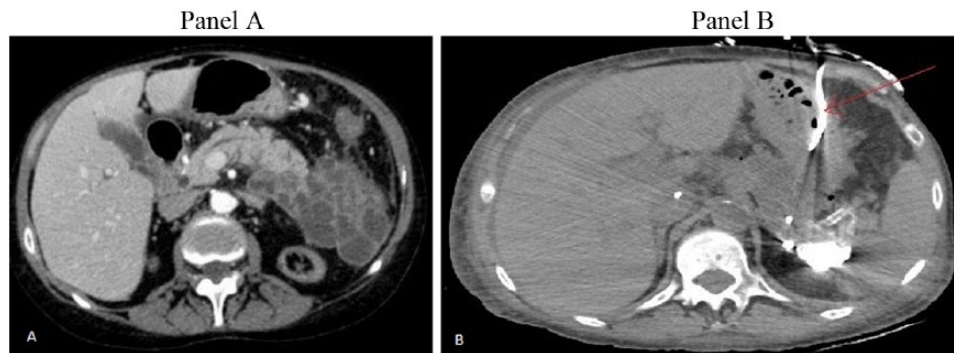


Figure 1. Panel A: pancreatic pseudocyst in abdominal computed tomographic scan. Panel B: abdominal magnetic resonance imaging, percutaneous cystogastrostomy drainage.

changed from peritoneal dialysis to hemodialysis (2 weeks).

Abdominal physical examination demonstrated epigastric and left lower quadrant tenderness. Blood examination showed leukocytosis with neutrophil left shift and increased levels of inflammatory markers.

Few hours after recovery, the patient underwent PD exchange; the liquid in the dialysis bag appeared yellow and cloudy. On the basis of the white blood cell count and peritoneal culture examination, we added tobramycin and vancomycin to peritoneal dialysate.

After 2 days from recovery, the peritoneal fluid culture was positive for *C albicans* peritonitis.

Therefore, the peritoneal catheter was removed, a right femoral central venous catheter (CVC) line was inserted, meropenem and anidulafungin were started, and tacrolimus was interrupted.

Contrast enhanced computed tomography (CT) scan of the abdomen and abdominal magnetic resonance imaging (MRI) without contrast evidence “numerous pseudo cystic formation containing the corpuscular liquid defined by a thick wall adherent to the corpo caudal of the pancreas, long to the anterior zone of the left renal, that extends from the retro cavity of the greater omentum in the anterior para renal to the left lateral conal interfacial” (Figure 1, panel A). Consequently, an acute complicated pancreatitis with pseudocyst was diagnosed.

A CT-guided percutaneous cystogastrostomy catheter was maintained to drain purulent fluid (Figure 1, panel B) for 25 days.

After 2 weeks from the recovery, for the dyspnea and hypoxia, due to pulmonary consolidation and severe bilateral pleural effusion, 3 times of plural effusion tapping was needed.

After 1 month of recovery, for the febrile peaks after the dialysis session, the CVC culture examination and hemoculture were positive to *Acinetobacter* so the patient at first developed candida peritonitis and then sepsis due to *A baumannii*. The blood examination revealed procalcitonin >200 ng/mL and β -D-glucan >523 pg/mL. The therapy was modified as

reported in Table 1. Despite the sepsis state was due to the femoral CVC infection, for the steno-obstructive pathology, it was not possible remove the femoral catheter.

A CT angiography, performed 6 weeks after recovery, evidenced the “complete thrombosis of the right subclavian vein, internal jugular vein with precaval tract stenosis and thrombosis of the left common femoral vein.” Images showed the abdominal presence “of the abscess formation in the left parietocolic facial in the mesosigma tract similar to the involvement of the left fallopian tube, small fluid collection like abscess formation between tail of the pancreas and the gastric lesser curvature.” A Tesio catheter was placed in jugular vein after dilatation procedure for jugular stenosis and the left femoral catheter was removed.

For the resistant anemia, it was necessary an hemotransfusion, while was also necessary fresh frozen plasma transfusion for the suspicion of disseminated intravascular coagulation state. The patient was discharged after 3 months in improved clinical conditions, feverless stable hemodynamic state, without respiratory problems and improved inflammatory index, and the resolution of abscess formation between tail of the pancreas and gastric lesser curvature due to antibiotic therapy. The patient went on hemodialysis, 1 month after discharge.

Discussion

Acute pancreatitis is divided in 3 states: (a) mild acute pancreatitis, characterized by absence of organ failure nor local or systemic complication; (b) moderately severe acute pancreatitis, characterized by organ failure that resolves within 48 hours and/or local or systemic complication without persistent organ failure; and (c) severe acute pancreatitis, characterized by persistence of organ failure (>48 hours). The incidence of pancreatitis is higher in end-stage renal disease state and in PD patients.

Icodextrin produces a chemical irritation in the peritoneum and pancreatic glands and can be the cause of pancreatitis.¹⁷ High intra-abdominal pressure caused by peritoneal fluid and nonphysiological composition that are able to promote the premature activation of the proteolytic pancreatic enzyme, local toxicity of peritoneal dialysate,^{35,36} and high level of uremic

Table 1. Therapeutic regimen.

DATE	ANTIMICROBIAL THERAPY
1st day	Fluconazole 400 mg daily intravenously + meropenem 1 g twice a day
2nd day	Fluconazole 200 mg daily intravenously + meropenem 1 g daily intravenously
3rd day	Fluconazole 200 mg daily intravenously + meropenem 1 g daily intravenously + ciprofloxacin 200 mg daily intravenously
4th day	Fluconazole 200 mg daily intravenously + meropenem 1 g daily intravenously + ciprofloxacin 200 mg daily intravenously + anidulafungin 100 mg daily intravenously
14th day	Tigecycline 50 mg twice a day intravenously + piperacillin/tazobactam 2.5 mg 3 times a day + anidulafungin 100 mg daily intravenously
19th day	Tigecycline 50 mg twice a day intravenously + anidulafungin 100 mg daily intravenously + linezolid 2 mg/mL intravenously
24th day	Meropenem 500 mg daily intravenously in HD days and meropenem 500 mg twice a day intravenously in non-HD days + anidulafungin 100 mg daily intravenously + linezolid 2 mg/mL intravenously
30th day	Meropenem 500 mg daily intravenously in HD days and meropenem 500 mg twice a day intravenously in non-HD days + anidulafungin 100 mg daily intravenously + teicoplanin 200 mg daily intravenously
32nd day	Tigecycline 50 mg twice a day intravenously three times a week + teicoplanin 200 mg daily intravenously only Saturday + fluconazol 200 mg daily 3 times a week + colomycin 500 000 IU daily intramuscular only Saturday
35th day	Tigecycline 50 mg twice a day intravenously 3 times a week + teicoplanin 200 mg daily intravenously only Saturday + fluconazol 200 mg daily 3 times a week + colomycin 500 000 IU daily intramuscular Tuesday and Thursday
37th day	Tigecycline 50 mg B.D intravenously three times a week + teicoplanin 200 mg daily intravenously three times a week after HD + fluconazol 200 mg daily three times a week + colomycin 500 000 IU daily intramuscular Tuesday and Thursday
40th day	Tigecycline 50 mg twice a day intravenously 3 times a week + teicoplanin 200 mg daily intravenously only Saturday + fluconazol 200 mg daily 3 times a week + colomycin 500 000 IU daily intramuscular 3 times a week after HD
44th day	Tigecycline 50 mg twice a day intravenously + teicoplanin 200 mg daily intravenously after HD 3 times a week + fluconazol 200 mg daily intravenously 3 times a week + colomycin 1 000 000 IU daily intramuscular 3 times a week
46th day	Tigecycline 50 mg twice a day intravenously + fluconazol 200 mg daily 3 times a week + colomycin 1 000 000 IU daily intramuscular 3 times a week after HD
51st day	Amphotericin B 150 mg daily intravenously three times a week + meropenem 500 mg 3 times a day intravenously + colomycin 1 000 000 IU daily intramuscular 3 times a week
58th day	Amphotericin 150 mg daily intravenously + meropenem 500 mg twice a day intravenously + colomycin 2 000 000 IU daily intramuscular 3 times a week + colomycin 2 500 000 IU daily intramuscular 3 times a week

Abbreviation: HD, hemodialysis.

toxin and local hypercalcemia are frequent causes of pancreatitis in PD.³⁵

Pancreatic dysfunction can be caused by the elevated gastrointestinal enzymes such as cholecystokinin, glucagon, and gastric inhibitory polypeptide that stimulate the oversecretion of pancreatic enzymes³⁷ and histologic lesion similar to chronic pancreatitis.³⁸

Acute pancreatitis manifests with a sudden sharp severe and persistent epigastric pain; nausea and vomiting that persist for different hours³⁹; fever; tachypnea; hypotension; and retroperitoneal hemorrhage such as Cullen sign and Grey Turner sign.²⁵

Acute pancreatitis can be diagnosed by the sudden onset of epigastric pain with back region radiation, increase in the serum amylase or lipase enzymes 3 times higher than normal range, and evidence of the pancreatitis in the imaging examinations such as CT or MRI.¹⁷ In patients on renal replacement therapy, it is necessary to evaluate the clinical and

radiological state to diagnose the pancreatitis for the association with high-level amylase and lipase without evidence of pancreatitis⁴⁰ because of the renal clearance changes. Icodextrin can decrease amylase activity so in PD patients, it is necessary to evaluate the lipase level instead of the amylase level. Pseudocyst formation is one of the complications related to 10% of the pancreatitis, usually 4 weeks after the acute state. Pancreatic tissue necrosis can progress toward liquefaction to develop the pseudocyst that can start in pancreatic duct or can be organized by the parenchymal necrosis that destroys the ducts with high dispersion of the pancreatic secretion. This formation can be associated with abdominal pain, duodenal or vascular obstruction, fistula formation to in adjacent organs, in pleural or pericardium cavity that may cause pleural effusion, or ascites, which can be diagnosed by imaging examination (CT and MRI). About 40% of the pseudocysts improve spontaneously. The other patients should be treated with surgery

Table 2. Evolution of serum amylase and lipase.

DATE	AMYLASE, U/L	LIPASE, U/L
1st day	137	713
2nd day (9 AM)	194	1189
2nd day (7 PM)	134	974
2nd day (9 PM)	120	806
3rd day	60	312
4th day	12	56
5th day	8	40

Few hours before admission, patient did an ambulatory control with normal pancreatic amylase (15 U/L). In the afternoon, the patient went to the hospital for abdominal pain. The sample of the afternoon evidenced amylase 137 U/L and lipase 713 U/L. Reaching a peak of amylase 194 U/L and lipase 1189 U/L, the picture laboratory normalized over 3 days.

methods, percutaneous or endoscopic cystogastrostomy drainage (Table 2).

Conclusions

In this clinical case, at first, the patient presented 1 episode of acute pancreatitis which demonstrated the increase in the pancreatic enzyme level, resolved within 3 days, whereas the second acute episode occurred in presence of normal amylase and lipase levels. Only the radiologic images (CT scan and MRI) demonstrated the presence of acute complicated pancreatitis with the “numerous communicated pseudo cystic formations.” This radiologic finding can be considered an acute idiopathic pancreatitis or a pancreatitis secondary to PD. The patient evidenced complicated candida peritonitis associated with acute pancreatitis and pseudocyst complicated by the overlap of pneumonitis and *A baumannii* sepsis.

Author Contributions

RA and LZ conceived and designed the experiments. LZ analyzed the data. RA wrote the first draft of the manuscript. IL, RG, SF, ER, SR, and SR contributed to the writing of the manuscript. RA, LZ, IL, RG, SF, ER, SR, and FR agree with manuscript results and conclusions and made critical revisions and approved final version. RA, LZ, IL, RG, SF, ER, SR, and SR jointly developed the structure and arguments for the paper. All authors reviewed and approved the final manuscript.

Disclosures and Ethics

As a requirement of publication, authors have provided to the publisher signed confirmation of compliance with legal and ethical obligations including but not limited to the following: authorship and contributorship, conflicts of interest, privacy and confidentiality, and (where applicable) protection of human and animal research subjects. The authors have read and confirmed their agreement with the ICMJE authorship and

conflict of interest criteria. The authors have also confirmed that this article is unique and not under consideration or published in any other publication, and that they have permission from rights holders to reproduce any copyrighted material. The external blind peer reviewers report no conflicts of interest.

REFERENCES

- Flynn CT, Chandran PKG, Shadur CA. Recurrent pancreatitis in a patient on CAPD. *Perit Dial Bull.* 1986;6:106.
- Rambausek M, Ziegler T, Ritz E. Incipient pancreatitis causing cloudy effluent in a patient on CAPD. *Perit Dial Bull.* 1986;6:160.
- Emder PJ, Howard NJ, Rosenberg AR. Non-ketotic hyperosmolar diabetic precoma due to pancreatitis in a boy on continuous ambulatory peritoneal dialysis. *Nephron.* 1986;44:355–357.
- De Boer B, Agar JWM. The role of hyperlipidemia in the etiology of pancreatitis in CAPD. *Perit Dial Int.* 1987;7:264.
- Singh S, Wadhwa N. Peritonitis, pancreatitis, and infected pseudocyst in a continuous ambulatory peritoneal dialysis patient. *Am J Kidney Dis.* 1987;9:84–86.
- Bourdaillez B, Andre JL, Broyer M, Davin JC, Landthaler G, Palcoux JB. Acute pancreatitis in 6 non-transplanted uremic children. *Pediatr Nephrol.* 1988;2:431–435.
- Lal SM, Fowler D, Losasso CJ, Berg GG. Coxsackie virus-induced acute pancreatitis in a long-term dialysis patient. *Am J Kidney Dis.* 1988;11:434–436.
- Burkart JM, Khanna R. A 69-year-old male with elevated amylase in bloody and cloudy dialysate. *Perit Dial Int.* 1993;13:142–148.
- Perez Fontan M, Pombo F, Soto A, Perez Fontan FJ, Rodríguez-Carmona A. Chylous ascites associated with acute pancreatitis in a patient undergoing continuous ambulatory peritoneal dialysis. *Nephron.* 1993;63:458–461.
- Ubara Y, Hara S, Katori H, et al. Acute pancreatitis in a CAPD patient in association with hemolytic anemia. *Perit Dial Int.* 1997;17:96–98.
- Nishida M, Okumura Y, Fujii M, et al. Pancreatitis and pancreatic abscess in a CAPD patient with severe malnutrition. *Nephrol Dial Transplant.* 2007;22:975–976.
- Ardalan MR, Shoja MM, Ghabili K, et al. Fulminant acute pancreatitis in a patient with familial Mediterranean fever on CAPD: what caused the pancreatitis? *Perit Dial Int.* 2009;29:676–678.
- Torregrosa De Juan E, Hernandez J, Pons R, et al. Repeated pancreatitis in peritoneal dialysis patient. *Nefrologia.* 2009;29:89.
- Fujinaga S, Nishizaki N, Hirano D, et al. Acute pancreatitis in a 2-year-old girl on peritoneal dialysis and using icodextrin solution. *Clin Nephrol.* 2010;75:89–90.
- Rubinstein S, Franjul R, Surana S, et al. Icodextrin-induced acute pancreatitis in a peritoneal dialysis patient: a case report and literature review. *Clin Nephrol.* 2016;86:283–286.
- Hayat A1, Thaneeru P, Priest P, Fogel J. Recurrent pancreatitis in an icodextrin-based peritoneal dialysis patient. Yet another case report. *N Z Med J.* 2013;126:67–69.
- Hamrahan M, Fülöp T, Mollae M, Lopez-Ruiz A, Juncos LA. Recurrent acute pancreatitis in a patient on peritoneal dialysis using 7.5% icodextrin. *Perit Dial Int.* 2012;32:568–570.
- Pitrone F, Pellegrino E, Mileto G, Consolo F. May pancreatitis represent a CAPD complication? Report of two cases with a rapidly evolution to death. *Int J Artif Organs.* 1985;8:235.
- Caruana RJ, Wolfman NT, Karstaedt N, Wilson DJ. Pancreatitis: an important cause of abdominal symptoms in patients on peritoneal dialysis. *Am J Kidney Dis.* 1986;7:135–140.
- Donnelly S, Levy M, Prichard S. Acute pancreatitis in continuous ambulatory peritoneal dialysis (CAPD). *Perit Dial Int.* 1988;8:187–190.
- Connacher AA, Stewart WK. Pancreatitis causes brownish-black peritoneal dialysate due to the presence of methaemalbumin. *Nephrol Dial Transplant.* 1987;2:45–47.
- Ford DM, Portman RJ, Lum GM. Pancreatitis in children on chronic dialysis treated with valproic acid. *Pediatr Nephrol.* 1990;4:259–261.
- Ergün T, Lakadamyal H. The CT frequencies of various non-traumatic acute abdominal emergencies in hemodialysis, peritoneal dialysis patients and the general population. *Eur J Radiol.* 2010;81:13–20.
- Rutsky EA, Robards M, Van Dyke JA, Rostand SG. Acute pancreatitis in patients with end-stage renal disease without transplantation. *Arch Intern Med.* 1986;146:1741–1745.
- Bruno MJ, van Westerloo DJ, van Dorp WT, et al. Acute pancreatitis in peritoneal dialysis and haemodialysis: risk, clinical course, outcome, and possible aetiology. *Gut.* 2000;46:385–389.

26. Quraishi ER, Goel S, Gupta M, Catanzaro A, Zasuwa G, Divine G. Acute pancreatitis in patients on chronic peritoneal dialysis: an increased risk? *Am J Gastroenterol.* 2005;100:2288–2293.
27. Lankisch PG, Weber-Dany B, Maisonneuve P, Lowenfels AB. Frequency and severity of acute pancreatitis in chronic dialysis patients. *Nephrol Dial Transplant.* 2008;23:1401–1405.
28. Gupta A, Yuan ZY, Balaskas EV, Khanna R, Oreopoulos DG. CAPD and pancreatitis: no connection. *Perit Dial Int.* 1992;12:309–316.
29. Pannekeet MM, Krediet RT, Boeschoten EW, Arisz L. Acute pancreatitis during CAPD in The Netherlands. *Nephrol Dial Transplant.* 1993;8:1376–1381.
30. Cakir B, Kirbaş I, Cevik B, Ulu EM, Bayrak A, Coşkun M. Complications of continuous ambulatory peritoneal dialysis: evaluation with CT. *Diagn Interv Radiol.* 2008;14:212–220.
31. Villacorta J, Rivera M, Alvaro SJ, Palomares JR, Ortuno J. Acute pancreatitis in peritoneal dialysis patients: diagnosis in the icodextrin era. *Perit Dial Int.* 2010;30:374–378.
32. Chen HJ, Wang JJ, Tsay WI, Her SH, Lin CH, Chien CC. Epidemiology and outcome of acute pancreatitis in end-stage renal disease dialysis patients: a 10-year national cohort study. *Nephrol Dial Transplant.* 2017;32:1731–1736.
33. Lee YC, Hung SY, Wang HH, et al. Different risk of common gastrointestinal disease between groups undergoing hemodialysis or peritoneal dialysis or with non-end stage renal disease: a nationwide population-based cohort study. *Medicine.* 2015;94:e1482.
34. Lankisch PG, Schirren CA, Kunze E. Undetected fatal acute pancreatitis: why is the disease so frequently overlooked. *Am J Gastroenterol.* 1991;86:322–326.
35. Hou SW, Lee YK, Hsu CY, et al. Increased risk of acute pancreatitis in patients with chronic hemodialysis: a 4-year follow-up study. *PLoS ONE.* 2013;8:e71801.
36. Banks PA, Bollen TL, Dervenis C. Classification of acute pancreatitis 2012: revision of the Atlanta classification and definitions by international consensus. *Gut.* 2013;62:102–111.
37. Yadav D, Agarwal N, Pitchumoni CSA, et al. A critical evaluation of laboratory tests in acute pancreatitis. *Am J Gastroenterol.* 2002;97:1309–1318.
38. Banks PA, Freeman ML. Practice parameters committee of the American College of Gastroenterology. practice guidelines in acute pancreatitis. *Am J Gastroenterol.* 2006;101:2379–2400.
39. Royle VL, Jensen DM, Corwin HL. Pancreatic enzymes in chronic renal failure. *Arch Intern Med.* 1987;147:537–539.
40. Anderstam B, García-López E, Heimbürger O, Lindholm B. Determination of alpha-amylase activity in serum and dialysate from patients using icodextrin-based peritoneal dialysis fluid. *Perit Dial Int.* 2003;23:146–150.