

ABERRANT HYPERPNEUMATIZATION FROM MASTOID CELLS TO SKULL CERVICAL AREA

AGOSTINO SERRA - CALOGERO GRILLO - RITA CHIARAMONTE - CATERINA GRILLO - LUIGI MAIOLINO
Università degli Studi di Catania - Dipartimento di Specialità Medico Chirurgiche - Sezione di Otorinolaringoiatria
(Direttore: A. Serra)

[Iperpneumatizzazione aberrante delle celle mastoidee alla regione cranio-cervicale]

SUMMARY

Authors report the observation of a patient who has undergone an encephalon's C.A.T. examination for ingravescent headache and dizziness.

The C.A.T. examination of the skull highlighted a marked pneumatization of mastoid cell and temporal bone prevalently on the right side, and also pneumatization of the right pars squamosa ossis occipitalis that spreads also to the condilo and the lateral atlantis mass.

Authors sustain that the abnormal pneumatization originated from normal cellular bands, deriving from the primary pneumatic axis, then probably spreaded with a valve mechanism.

Key words: Mastoid hyperpneumatization, dizziness, TC

RIASSUNTO

Gli autori riportano l'osservazione di un paziente sottoposto ad esame TC encefalo per cefalea ingravescente e vertigini.

L'esame TC del cranio evidenziò una marcata pneumatizzazione delle celle mastoidee e dell'osso temporale prevalentemente a destra, ed altresì pneumatizzazione della parte squamosa destra dell'osso occipitale che si estendeva anche al condilo ed alla massa laterale dell'atlante.

Gli autori ritengono che l'abnorme pneumatizzazione originatasi dalle normali strie cellulari derivante dall'asse pneumatico primario si siano poi estese mediante un possibile meccanismo a valvola.

Parole chiave: Iperpneumatizzazione mastoidea, vertigine, TC

Introduction

The pneumatization process of the temporal bone normally affects the mastoid process but it is also possible its extension to other districts of the temporal bone, creating an aberrant cells sistem communicating with it. Our clinical case with pneumatization of the bones that form the cranio cervical hinge is a rare anatomical variation.

Clinical case

A patient of male sex, 42 years old, come to our observation because affected by a migraine that increased during sneezes or expirations with closed glottis, and dizziness. He did not have any traumatic anamnesis. So the patient underwent encephalon's C.A.T. examination.

The C.A.T. examination showed a marked pneumatization of petrosal bone, mastoid and right occipital bone, homolaterally extended also to condylus and to lateral mass of the atlas.

We have also highlighted a bleb of enphysema inside the spino-canalil lateral to the dens axis.

Discussion

The etiology of the pneumatization of the bones of the cranio cervicalis hinge is unknown.

We sustain that such a deformity occurred during the embryogenetic period and during the organogenesis.

In the period of the fetal life the primal pneumatic axis, starting from the first entodermal branchial cleft made: eustachian tube, box of tympano, antrum; subsequently the temporal bone gets around to the first entodermal branchial cleft future mucous membrane of the middle ear.

In this deformity it is possible to have an abnormal growth of this mucous membrane inside the bone structure, as occipital bone, and lateral masses of C1, in this case, taken by a failed growth of atlanto-occipital joint cavity.

That abnormal pneumatization would become evolutive during the adulthood after the instauration of a valve mechanism.

Another possible evolution of the deformity would be a hypertensive pneumoencephalon and consequent appearance of acute neurological symptomatology .

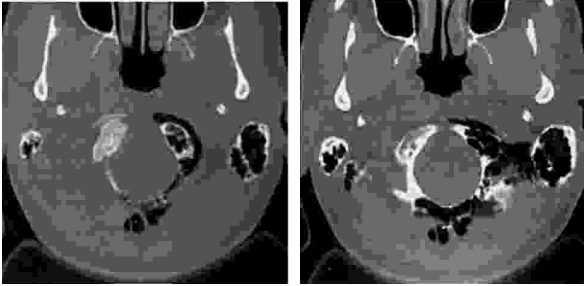


Figure 1: The C.A.T. examination in axial scan highlights a marked pneumatization of occipital bone, of mastoid cells of temporal bone, of occipital condilo, of the hinder outline of great foramen and lateral mass of right atlantis. It is also noticed an air-harvest that is anterolateral to the right occipitalis condilo.

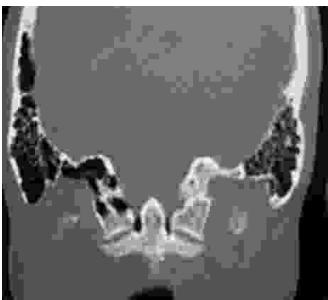

Figure 2: The C.A.T. on coronal scan highlights an air- harvest inside the spino-canal adjacent to the dens axis. Fusion of the right atlanto-occipitalis articular facet .

Bibliography

- 1) Sener RN: *Air sinus in the occipital bone*. Am J Radiol 159;905, 1992
- 2) Rauschnig W: *Normal anatomy of the craniocervical junction-6th Advanced Course of the ESNR*. Budapest 1995. Edizioni del Centauro. Udine.
- 3) Daffner RH: *CT of the craniocervical Junction*. Am J Radiol 167: 365-366, 1996.
- 4) Dietemann JL, Dojon D et Al: *Cervico-occipital junction: normal and pathologic aspects*. In: *Manelfe C(ed): Imaging of the spine and spinal cord*. Raven Press, New York 1992.
- 5) Roda JM, Pascual JM, Borrego P: *Occipital air sinus-causing intracerebral pneumocephalus*. J Neurosurg 84: 1072, 1996.
- 6) Sadier DJ, Doyle GJ et Al: *Craniocervical bone pneumatization*. Neuroradiology 38: 330-332, 1996
- 7) Shillinger R: *Pneumatization of the mastoid*. Radiology 33: 54-67, 1939.
- 8) Bonneville JF, Runge M et Al: *Traumatism of the craniocervical junction*. *Imaging of the craniocervical junction Advanced Course of the ESNR*. Budapest 1995. Edizioni del Centauro. Udine.

Request reprints from:

Dott. CALOGERO GRILLO

Via Corsaro, 8

95030 S. Agata Li Battiati (CT)

(Italy)