

Neoplastic sigmoid-uterine fistula. An exceptional complication of large intestine cancer

G. ZANGHÌ, V. LEANZA, R. VECCHIO, A. D'AGATI, S. CORDOVA,
N.M. RINZIVILLO, M. LODATO, G. LEANZA

SUMMARY: Neoplastic sigmoid-uterine fistula. An exceptional complication of large intestine cancer.

G. ZANGHÌ, V. LEANZA, R. VECCHIO, A. D'AGATI, S. CORDOVA,
N.M. RINZIVILLO, M. LODATO, G. LEANZA

Neoplastic sigmoid-uterine fistula is an extremely rare condition because the uterus is a thick and muscular organ. A 74-year-old woman was admitted to the First Aid Station suffering from abdominal pain and foul smelling vaginal discharge. Gynaecological examination showed fecal drainage from the cervical orifice, while the uterus was regular in size but very firm and painful. Ovaries and fallopian tubes

were not palpable owing to abdominal tenderness. Ultrasounds revealed inhomogeneous thickening of uterine cavity, without detecting fistula. Contrast Medium CT (CMCT) showed Douglas' recto-uterine pouch occluded. The sigmoid wall was very thin exception a site where a fistula was suspected. At the surgery severe adhesions of the sigma-rectum with the posterior uterine wall were observed. After adhesiolysis, 18 cm colon-sigma-rectum was removed. Total hysterectomy with salpingo-oophorectomy was performed. Lymphadenectomy ended the procedure. Anatomical specimen confirmed sigmoid-uterine fistula. At histology a mildly differentiated adenocarcinoma of sigma-rectum was shown. Postoperative course was uneventful. Such a case of neoplastic sigmoid-uterine fistula has not been reported so far.

KEY WORDS: Colon - Uterus - Colorectal - Fistula - Adenocarcinoma.

Introduction

Fistulisation of the large intestine is usually consequence of complicated diverticulitis (1). In fact, potential complication of chronic intestinal wall weakening could emerge in colo-uterine fistula (2). In this case multidisciplinary management including a major surgery with necessity of removal of uterus and a part of intestine has to be carried out. Large intestine cancer is one of the most common neoplastic disease (3), and infiltration of the cancer to the contiguous organs is typical. Among patients with sigmoid colon cancer approximately 20% develop fistulas as a result of necrosis (4). The main large intestine neoplastic complications are stricture, bleeding, perforation and fistula formation. Fistulisation is defined as a communication between two surfaces getting in contact (5). Fistulas often involve the urinary tract and

rectum and may be iatrogenic complications of reparative procedures on the pelvic floor (6-9). The most common types of fistula are colovesical, colocolic and colovaginal ones. While iatrogenic fistulas can be prevented with careful and correct surgical technique (10), neoplastic fistulae can be avoided with an early diagnosis of the tumor (11-14). Certainly huge abdominal mass as for endometriosis or neoplastic adhesions can also result in intra-operative lesions and fistula formation (15, 16). Because uterine walls are made of thick and muscular tissues, they provide a protective barrier against invasion of generally malignant disease, except previous uterine perforations secondary to curettage (17). Therefore, a neoplastic sigmoid-uterine fistula is an extremely rare condition. We report a case of a sigmoid-uterine fistula caused by the infiltration of a large intestine cancer.

Case report

A 74-year-old woman was admitted to the First Aid Station with abdominal pain, bowel constipation and intermittent diarrhea with mucus discharge. The pain was localized to the lower abdomen with irradiation to surrounding regions.

Policlinic University Hospital, Surgery Department, Catania, Italy

Corresponding author: Vito Leanza, e-mail: leanzavito53@gmail.com

© Copyright 2017, CIC Edizioni Internazionali, Roma

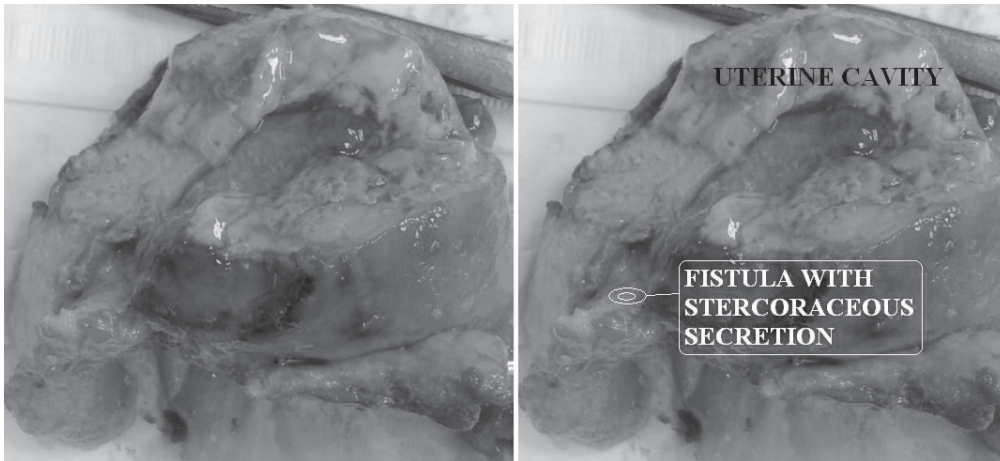


Figure 1 - Uterus with fistula.

Physical examination showed abdominal tenderness, mostly focused to the left iliac fossa. Abdomen was hyperdistended with signs of moderate peritoneal irritation. Digital rectal examination was painful and a pedicled polyp protruding across the anal orifice was seen. Ultrasounds revealed inhomogeneous thickening of uterine cavity, without detecting fistula. The abdomino-pelvic Computed Tomography (CT) without contrast medium showed an abscess involving the peri-sigmoid space. Patient was sick, dehydrated and feverish (38.4°). Blood pressure was 130/64 mmHg, heart rate 83 beats/min and respiratory rate 18 breaths/min. Routine blood chemistry showed leukocytosis (26.0 x 10⁹/l). The patient was assigned to the Surgery Department for treatment and additional investigation. Fasting and antibiotic therapy were applied suddenly in order to prevent septic complications. After three days Contrast Medium CT (CMCT) was performed to clarify clinic status. It showed a peritoneal abscess (15x17 cm) flowing with free air from the perisigmoid space to the Douglas' recto-uterine pouch and a site of "minor resistance" involving posterior uterine wall was detected. However even if the diagnosis of a sure fistula was not done with instrumental examinations, a clinical suspicion of sigmoid-uterine fistula was proposed. Light improvement following medical therapy was reached. A percutaneous drainage under CT control was carried out and 60 ml daily spillage was obtained. With pelvic examination an atrophy of both vagina and cervix was observed. In addition, yellowish foul vaginal discharge came out from the cervical orifice. Culture of the vaginal discharge was positive for *Escherichia Coli* and *Enterococcus Avium*. A multidisciplinary surgical approach of abdominal surgeons and gynaecologists was planned. Pubo-supra-umbilical incision was carried out. Neoplastic adhesion of the distal sigmoid colon to the posterior wall of the uterus was found (18). The uterus was isolated with difficulty due to adhesions with the large intestine. Af-

ter adhesiolysis 18 cm colon-sigma-rectum was removed. Closure of the rectal stump and end-colostomy according to Hartmann were performed (19). Total hysterectomy with bilateral salpingo-oophorectomy and lymphadenectomy were done. The fistula between the sigmoid colon and the endometrial cavity was confirmed in surgical specimen. Final histological result was mildly differentiated adenocarcinoma involving sigma-rectum. Postoperative course was uneventful and patient was discharged on the thirteenth postoperative day.

Discussion and conclusion

Fistulisation between two contiguous structures may result as main complication of diverticulosis, Inflammatory Bowel Disease (IBD) and neoplastic swellings. Regarding sigmoid rectal cancer, fistula formation is a rare event as it occurs when septic material spreads or penetrates an adjacent organ such as bladder, vagina, or small bowel. Colovesical fistula is the most common, followed by colovaginal fistula. Because the uterus is a thick and muscular organ, it can prevent the spread of inflammation and formation of fistula. It explains the rarity of this sort of complication involving the womb. A rare case of uretero-uterine fistula following caesarean section in a patient with anatomic alteration of ureters was reported by Caschetto et al. in 1997 (20). However, a non-iatrogenic sigmoid uterine fistula due to cancer is even more rare. Although the uterus provides a protective barrier against an inflammatory or malignant disease, a sigmoid uterine fistula might develop by obstetric traumas such as curettage, Intra-Uterine Device (IUD) and radiation therapy. Neoplastic adhesion of the colon and uterus may occur during colorectal cancer resulting in necrosis of tissues. Subsequent fistula formation by linkage between uterus and other contiguous organs is an uncommon result. In this case we observe

a fistula formation in the uterus due to the infiltration of a sigmoidrectal cancer inside the genital organ. The explanation why this sort of fistula occurs is because it is a defense mechanism of the body in order to prevent a life threatening stercorary peritonitis that could cause generalized and hard to treat sepsis (21).

Although clinical manifestations of sigmoid-uterine fistula vary according to causative pathology, typical symptoms include malodorous faecal or purulent vaginal discharge for days or months (14). Symptoms such as fever and abdominal pain may be less evident or absent. In our case, the patient presented with fever, abdominal pain and vaginal discharge. Often faecal vaginal discharge is indicative of colouterine or colovaginal fistula. No gold standard protocol has been decided to diagnose fistula between uterus and colon. Cultures of the vaginal or cervical discharge are necessary to determine the source of the foul smell and to select appropriate antibiotics: as observed in our case these cultures revealed the presence of gram-negative enteric bacteria. Many imaging tools have been used to diagnose the fistula involving intestine and uterus. MCCT scan is required to rule out other surgical pathologies. In our case CMCT showed a 15x7 cm loculated abscess with free air suggesting diverticulosis or fistular pathway. However, other causes could not be identified using CMCT. This imaging technique is increasingly being used for evaluation of acute abdomen and for diagnosis of retroperitoneal and intraperitoneal lesions, including those involving free air, abscess, or fluid collection. In a colouterine fistula, air bubbles in the uterine cavity and colon walls joined to the uterus may be identified in CMCT findings. However, detection of the fistula tract or differentiation between complicated diverticulitis and colon cancer may be limited in tomography findings. Even if colonic lesions such as diverticulosis might be identified by using colonoscopy or barium enema, these procedures are not always diriment for the diagnosis of a sigmoid uterine fistula (21). Magnetic resonance imaging (MRI) has been used as well to identify fistula and images have been reported to delineate the extension of the fistular pathway involving adjacent organs. Sonohystero-graphy using a CM may be used too. It could visualize not only the fistula tract but also the uterine and sigmoid walls (22). This last method prevents X-ray exposure

and possible allergic reaction to radio-opaque medium. In our case, CMCT findings suggested the diagnosis of a colonic stenosis, diverticulosis or colon sigmoid uterine fistula. Surgical management is mandatory for definitive resolution of the septic focus. In this exceptional fistula, an appropriate diagnosis together with a suitable treatment avoided a possible fatal outcome due to generalized infection, giving an adequate life expectancy to the patient. Hartmann's operation for managing large intestine is indicated. This procedure consists of resection of the recto-sigmoid colon with closure of the rectal sigmoid stump and end-colostomy. Hartmann's operation is currently limited to emergency surgery when immediate anastomosis is very risky. In addition, it is used palliatively in patients with a widespread colo-rectal malignant tumor. An one-stage procedure involving resection of the uterus and sigmoid colon without anastomosis is a typical example. Because the prognosis for a sigmoid uterine fistula secondary to neoplastic invasion can be good, the selection of an appropriate approach according to the patient's condition is important. Another factor to consider is the psychological impact of hysterectomy and surgical procedures to the patient. Whereas menopausal women accuse alterations of both mucosal trophism and pelvic static, being predisposed to urinary incontinence; the women of childbearing age have a severe psychological disorder linked to infertility and sexual problems (23, 24). The Hartmann's procedure with colostomy, hysterectomy and salpingo-oophorectomy were performed followed by lymphadenectomy (25). In conclusion, a sigmoid-uterine fistula is a rare complication of large intestine cancer. CT, or better CMCT, is routinely performed for diagnosis in patients with cancer and suspected uterine fistula. However, final confirmation of diagnosis by using Tomography alone may be difficult. Therefore, other non-invasive modalities such as MRI or sonohystero-graphy could be necessary. Surgical approach is laparoscopic (26-35) or open surgery. Such a case of neoplastic sigmoid-uterine fistula has not been reported so far.

Disclosure

No potential conflict of interest relevant to this article was reported.

References

1. Stollman NH, Raskin JB. Diagnosis and management of diverticular disease of the colon in adults. Ad Hoc Practice Parameters Committee of the American College of Gastroenterology. *Am J Gastroenterol.* 1999;94(11):3110-21.
2. Banky B, Marlborough F, MacLeod I, Gill TS. Single-incision laparoscopic (SIL) sigmoid colectomy and uterus-preserving re-
3. Zanghì A, Cavallaro A, Piccolo G, Fisichella R, Di Vita M, Sparta D, Zanghì G, Berretta S, Palermo F, Cappellani A. Dissemina-

pair for colo-uterine fistula secondary to severe diverticular disease: an unusual technical solution for an unusual presentation of a common disease. *BMJ Case Rep.* 2016;pii: bcr2016214895. doi: 10.1136/bcr-2016-214895.

- tion metastasis after laparoscopic colorectal surgery (LCRS) versus conventional open surgery for colorectal cancer (OCRS). *European Review for Medical and Pharmacological Sciences*. 2013;17(9):1174-84.
4. Leanza V, Intagliata V, Leanza G, Vecchio R. Pelvic posterior compartment defects. Comparative study of two vaginal surgical procedures. *UIJ*. 2013;27, 1. DOI: 10.4081/uij.2013.e5.
 5. Woods RJ, Lavery IC, Fazio VW, Jagelman DG, Weakley FL. Internal fistulas in diverticular disease. *Dis Colon Rectum*. 1988;31:591-596.
 6. Leanza V, Intagliata E, Leanza G, Cannizzaro MA, Zanghì G, Vecchio R. Surgical repair of rectocele. Comparison of transvaginal and transanal approach and personal technique. *G Chir*. 2013;34(11-12):332-336. doi: 10.11138/gchir/2013.34.11.332.
 7. Leanza V, Intagliata E, Ferla F, Leanza A, Cannizzaro MA, Vecchio R. Mini-invasive tension-free surgery for female urinary incontinence. *G Chir*. 2014;35(1-2):36-41. doi: 10.11138/gchir/2014.35.1.036.
 8. Leanza V, Intagliata E, Leanza A, Ferla F, Leanza G, Vecchio R. Comparison between three mini-sling surgical procedures and the traditional transobturator vaginal tape technique for female stress urinary incontinence. *G Chir*. 2014;35(3-4):80-4.
 9. Vito Leanza, Eva Intagliata, Gianluca Leanza, Rosario Vecchio, Pelvic posterior compartment defects. Comparative study of two vaginal surgical procedures. *UIJ*. 2013;27(1).
 10. Leanza V, Zanghì G, Vecchio R, Leanza G. How to prevent mesh erosion in transobturator Tension-Free Incontinence Cystocele Treatment (TICT): a comparative survey. *G Chir*. 2015;36(1):21-5.
 11. Leanza V, Coco L, Leanza G, Scilletta B, Zanghì G, Vecchio R, Zarbo G. Primary peritoneal serous papillary carcinoma (PSPC) involving ovary and colon: Management and Treatment. *J Cancer Res Ther*. 2013;1:119-122.
 12. Leanza V, Garraffo C, Leanza G, Leanza A. Retroperitoneal sarcoma involving unilateral double ureter: management, treatment and psychological implications. *Case Rep Oncol*. 2014;7(2):301-5.
 13. Stracquadaneo M, Marilli I, Leanza G, D'Agati A, Leanza V. Large subserosal uterine leiomyoma and hydronephrosis. *Giorn It Ost Gin*. 2014;36(6):580-582.
 14. Vecchio R, Marchese S, Famoso S, La Corte F, Marletta S, Leanza G, Zanghì G, Leanza V, Intagliata E. Colorectal cancer in aged patients. Toward the routine treatment through laparoscopic surgical approach. *G Chir*. 2015;36(1):9-14.
 15. Leanza V, Gulino FA, Leanza G, Zarbo G. Surgical removal of multiple mesenteric fibroids (Kg 4,500) by abdominal spread of previous laparoscopic uterine myomectomy. *G Chir*. 2015;36(1):32-5. doi: 10.11138/gchir/2015.36.1.032.
 16. Leanza V, Ciotta L, Bellanca S, Leanza G. Medical therapy for endometriosis: a literature review. *Giorn It Ost Gin*. 2015;37(2):71-76. doi: 10.11138/giog/2015.37.2.071.
 17. Vecchio R, Marchese S, Leanza V, Leanza A, Intagliata E. Totally laparoscopic repair of an ileal and uterine iatrogenic perforation secondary to endometrial curettage. *Int Surg*. 2015;100(2):244-8. doi: 10.9738/INTSURG-D-13-00267.1.
 18. Tomoyuki A, Masahiko I, Takeshi S, Hiroshi I, Hiroki E, Koji F, Masato Y, Hirokazu T, Yasunobu A, Noritoshi K, Kensuke K, Hiroshi Ki, Shoji Y, Yasushi R, Atsushi N. Penetration of the sigmoid colon to the posterior uterine wall secondary to diverticulitis: a case report. *J Med Case Reports*. 2009;3:8957.
 19. Balanzoni S, Perrucci A, Pasi L, Montanari M. The Hartmann intervention. The current indications and the authors' own experience. *Minerva Chir*. 1997;52 (4):383-6.
 20. Caschetto S, Leanza V, Serrao A. A very uncommon injury to the genito-urinary tract: uretero-uterine fistula: a case report. *Acta Obst Gyn Scand*. 1997;76:167-77.
 21. Di Stefano G, Zanghì G, Biondi A, Benfatto G, Basile F. Surgical treatment of acute complicated diverticulitis. *G Chir*. 2009;30(8/9):355-358.
 22. Takada T, Nakagawa S, Hashimoto K, Sone K, Kugu K, Kozuma S, Taketani Y. Preoperative diagnosis of colouterine fistula secondary to diverticulitis by sonohysterography with contrast medium. *Ultrasound Obstet Gynecol*. 2004;24(6):682-3.
 23. Leanza V, Castronovo G, Maiorana A, Leanza G, Leanza A. The impact of hysterectomy as uterine fibroid therapy on personality traits and psychological symptoms of patients. (original article) *Giorn It Ost Gin*. 2016;38(2):253-259.
 24. Leanza V, Zanghì G, Leanza G, Leanza A, Passanisi A, Giaimo F. A specific application of two psychological measures on pelvic organ prolapse patients. *Giorn It Ost Gin*. 2015;37(2):82-86.
 25. Zanghì G, Di Stefano G, Toscano C, Caponnetto A, Vecchio R, Di Mauro G, La Terra A, Leanza V, Basile F. Breast cancer and sentinel lymph node micrometastasis: indications for lymphadenectomy and literature review. (Original article). *G Chir*. 2014;35(11/12):260-265.
 26. Zanghì G, Leanza V, Vecchio R, Malaguarnera M, Romano G, Rinzivillo NM, Catania V, Basile F. Single-Incision Laparoscopic Cholecystectomy: our experience and review of literature. *G Chir*. 2015;36(6):243-246.
 27. Biondi A, Tropea A, Monaco G, Musmeci N, Zanghì G, Basile F. Complications in the laparoscopic treatment of primary and secondary hernias of the abdominal wall. *Ann Ital Chir*. 2010;81(3):193-8.
 28. Zanghì G, Distefano G, Benfatto G, Arena M, Basile F. Laparoscopic surgery in acute small bowel obstruction. Our experience. *G Chir*. 2012;33(1/2):38-40.
 29. Vecchio R, Amore F, Marchese S, Zanghì G, Alongi G, Ferla F, Intagliata E. Polyp of the cecum. Laparoscopic-assisted polypectomy. *G Chir*. 2012;33(8/9):274-76.
 30. Formoso C, Stracquadaneo M, Teodoro MC, Leanza V, D'alesandro, Ciotta L. adolescents and PCOS: Last update on diagnosis and therapy. *Giorn It Ost Gin*. 2014;36(1):131-136.
 31. Leanza V. tension-free mini-invasive anti-incontinence procedures: Comparison among three main pathways. *Open Women's Health Journal*. 2012;6(1):30-35.
 32. Leanza V, Intagliata E, Ferla F, Leanza A, Leanza G, Cannizzaro RA, Vecchio R. mini-invasive tension-free surgery for female urinary incontinence. *G Chir*. 2014;35(1-2):36-41.
 33. Leanza V, Lo Porto M, Passanisi A, Leanza G. Physical and psychological implications in a multiple and preterm caesarean section. A case report. *Ann ItalChir*. 2013;84 issue e-Pub. Pii: s2239253X13021919.
 34. Leanza V, Garozzo V, Accardi M, Molino A, Conca M, Basile A. A late complication of transobturator tape: abscess and myositis. *Minerva Ginecol*. 2008;60(1):91-94.
 35. Leanza V, Intagliata E, Leanza A, Ferla F, Leanza G, Vecchio R. Comparison between three mini-sling surgical procedures and the traditional transobturator vaginal tape technique for female urinary incontinence. *G Chir*. 2014;35(3-4):80-84.