

IMAGES IN INTERVENTION

Embolization of Fractured Bioresorbable Scaffold Struts

Insights From 2- and 3-Dimensional Optical Coherence Tomography



Piera Capranzano, MD, Bruno Francaviglia, MD, Davide Capodanno, MD, PhD, Maria Elena Di Salvo, MD, Claudia Ina Tamburino, MD, Fabio Maria Santagati, MD, Corrado Tamburino, MD, PhD

A 58-year-old diabetic man underwent implantation of 3 overlapping Absorb bioresorbable vascular scaffolds (BVS) (2.5/28, 2.5/28, and 3.0/28 mm) (Abbott Vascular, Santa Clara, California) in a heavily calcified left anterior descending artery stenosis. Optical coherence tomography (OCT) revealed multiple fractures of the 3.0/28 BVS, leading to in-scaffold implantation of a zotarolimus-eluting stent (ZES) (Figures 1A and 1B). The 4-month angiography showed a severe edge in ZES restenosis treated with another stent. The OCT revealed an unexpected disappearance of BVS struts (Figure 1C) in the ZES segment and a nonocclusive cluster of polymeric struts stuck in the vessel wall 8.5-mm far from the distal scaffold, with various coverage patterns (Figures 1D to 1H). Three-dimensional OCT suggested a single fragment of polymeric crown (Figures 1I and 1J). The patient has not experienced adverse events over 8-month follow-up and never stopped dual antiplatelet therapy (DAPT).

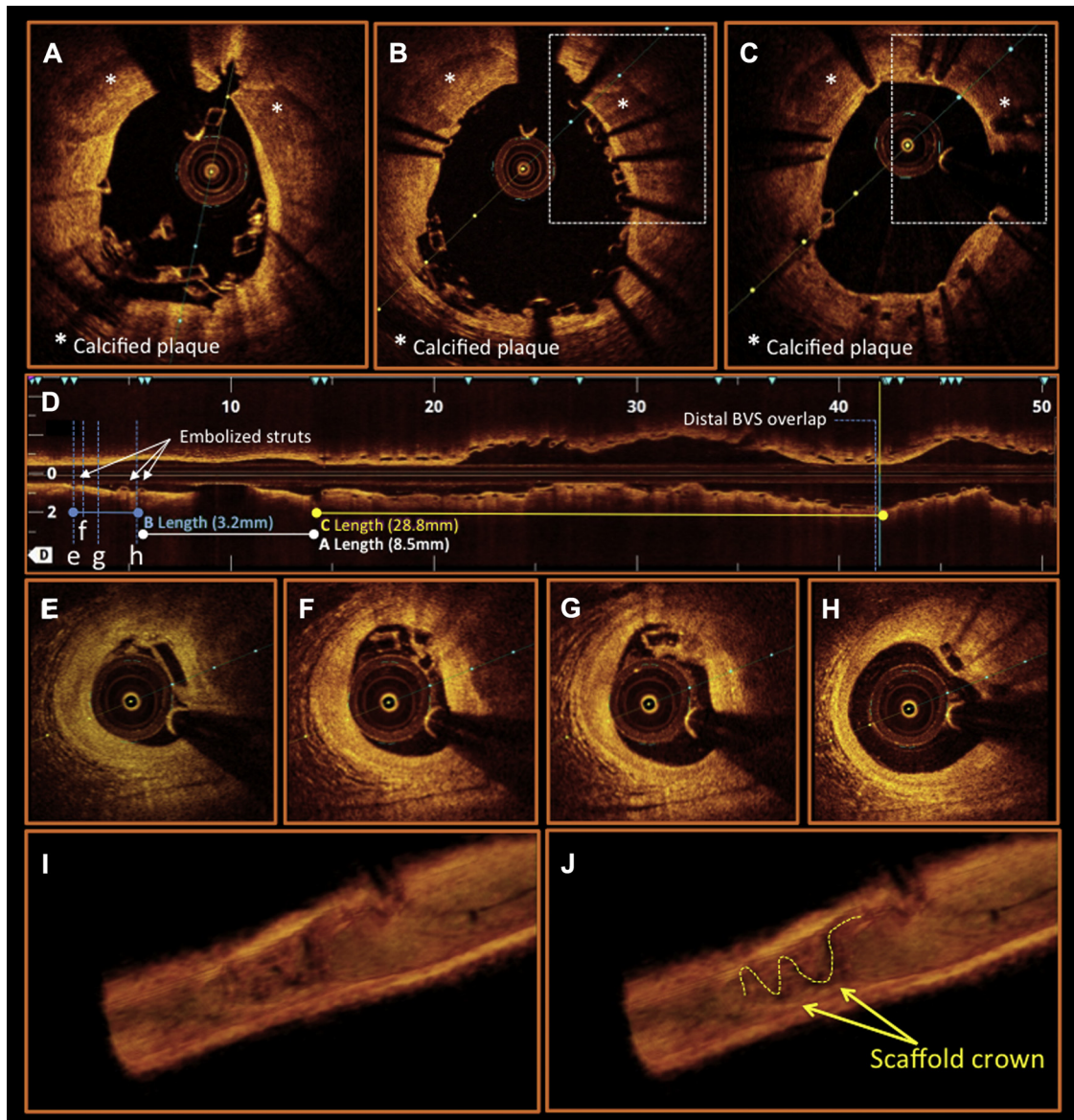
This case provided a demonstration of strut embolization, which was an incidental OCT finding, showing that incorporation into the vessel wall rather than abrupt obstruction is a possible fate of embolized struts. This phenomenon may underlie late ischemic events, especially after DAPT discontinuation. It is conceivable that the metal-in-polymer technique might cause an additive stress on the BVS, likely inducing a scaffold fragments separation. Where the metal-in-polymer technique is used, an OCT may be appropriate to exclude scaffold embolization and guide DAPT duration.

REPRINT REQUESTS AND CORRESPONDENCE: Dr. Piera Capranzano, University of Catania, Cardiovascular Department, Ferrarotto Hospital, Citelli 1, Catania 95124, Italy. E-mail: pcapranzano@gmail.com.

KEY WORDS bioresorbable scaffolds, complications, fracture, struts embolization

From the Cardiovascular Department, Ferrarotto Hospital, University of Catania, Catania, Italy. Dr. Tamburino has received honoraria/lecture fees from Medtronic, Abbott Vascular, and Edwards Lifesciences. All other authors have reported that they have no relationships relevant to the contents of this paper to disclose.

Manuscript received October 19, 2015; revised manuscript received October 26, 2015, accepted November 5, 2015.

FIGURE 1 Fractured and Embolized Struts on 2- and 3-Dimensional OCT

Baseline 2-dimensional optical coherence tomography (OCT) shows the fractured scaffold (A) before and (B) after metallic stent implantation; the comparison between baseline (B) and 4-month (C) corresponding cross sections shows a focal disappearance at follow-up of BVS struts (dashed boxes). The longitudinal view (D) demonstrates the embolized strut cluster (B = 3.2 mm) and its gap (A = 8.5 mm) with the distal scaffold (C = 28.8 mm). (E to H) Cross sections show embolized struts partially covered (E), uncovered and protruding (F and G), or fully embedded (H). 3-dimensional OCT (I) demonstrates a longitudinal arrangement of a single fragment of scaffold crown highlighted in J (dashed yellow line).