



Current Status and Clinical Development of Transcatheter Approaches for Severe Mitral Regurgitation

Carmelo Grasso, MD; Davide Capodanno, MD, PhD; Corrado Tamburino, MD, PhD; Yohei Ohno, MD

Transcatheter mitral valve intervention has emerged as an effective treatment option for symptomatic severe mitral regurgitation in patients considered to be inoperable or at high operative risk for surgical mitral valve surgery. Most transcatheter approaches are modifications of existing surgical approaches. Transcatheter edge-to-edge mitral valve repair with the MitraClip system has the largest clinical experience to date, as it offers a sustained clinical benefit in selected patients. This review aims to provide an up-to-date overview of transcatheter mitral valve interventions, including leaflet repair, annuloplasty, and mitral valve implantation. (*Circ J* 2015; **79**: 1164–1171)

Key Words: Annuloplasty; MitraClip; Mitral regurgitation; Transcatheter mitral valve implantation; Transcatheter mitral valve repair

Mitral regurgitation (MR) is one of the most common valvular heart diseases in Japan, as in other Western countries. A study in healthy Japanese subjects showed that 64.4% had any degree of MR,¹ whereas the prevalence of clinically significant moderate-to-severe MR is reported to be approximately 1.7% in the general population of the United States, increasing with age to approximately 9.3% in those >75 years of age.² The etiology of MR is diverse, and it may result from abnormalities in the structure and/or function of one or more components of the mitral apparatus (ie, leaflets, annulus, chordae tendineae, papillary muscles, and left ventricle [LV]). Degenerative MR (DMR) involves primary abnormalities of the leaflets, most commonly from myxomatous degeneration, whereas in secondary or functional MR (FMR), the leaflets are usually normal, and the regurgitation occurs as a consequence of adverse LV remodeling, with papillary muscle displacement, leaflet tethering, and annular dilatation.³

Regardless of its etiology, severe MR is associated with progressive LV dysfunction and congestive heart failure, ultimately leading to high rates of morbidity and mortality.⁴ Current guidelines recommend surgery for moderate-to-severe (3+) or severe (4+) MR in patients with symptoms or evidence of LV dysfunction.^{5,6} However, when the MR is secondary to underlying LV dysfunction (ie, FMR), the benefit of surgery is controversial.⁷ Therefore, patients with FMR and high surgical risk are frequently denied surgery and referred to isolated clinical management, carrying a poor long-term prognosis. Indeed, the Cleveland Clinic database showed that among 1,095 symptomatic severe MR patients, 53% were deemed inoperable and were medically managed, with most of them (90%) presenting

with FMR.⁸ Likewise, the Euro Heart Survey data revealed that almost half of symptomatic patients hospitalized with severe MR are not referred for surgery, mainly because of advanced age (>70 years), comorbidities, and LV dysfunction. On the other hand, a meta-analysis of mitral valve (MV) surgery in patients ≥80 years of age showed an association with high operative mortality (~15%), although this figure has decreased significantly in recent years.⁹ That study also demonstrated that MV repair suffers from lower operative mortality compared with MV replacement in octogenarians.

These data in aggregate suggest that there is a potentially large unmet need for transcatheter MV intervention in high surgical risk patients or those who are denied surgery because of comorbidities. Various technologies of intervention, at different stages of investigation, have been introduced to minimize surgical intervention and risks. These approaches can be mainly categorized into leaflet repair, annuloplasty, chordal implantation, and transcatheter MV implantation (TMVI) (**Table 1**).

Leaflet Repair

Among the transcatheter MV repair (TMVR) technologies, edge-to-edge MV repair with the MitraClip system (Abbott Vascular, Abbott Park, IL, USA) has undergone the most extensive human investigation thus far, with more than 20,000 procedures already performed.¹⁰ The MitraClip is a polyester-covered cobalt-chromium clip (**Figures 1A,B**) inserted via the femoral vein and advanced under transesophageal echocardiographic guidance into the left atrium following a transseptal puncture (**Figure 1C**). The clip is opened, positioned above the regurgitant jet, and advanced into the LV. It is then retracted

Received April 20, 2015; accepted April 20, 2015; released online May 1, 2015

Department of Cardiology, Ferrarotto Hospital, University of Catania, Catania (C.G., D.C., C.T., Y.O.); Excellence Through Newest Advances (ETNA) Foundation, Catania (D.C., C.T.), Italy; and Department of Cardiology, University of Tokai School of Medicine, Isehara (Y.O.), Japan

Mailing address: Carmelo Grasso, MD, Department of Cardiology, Ferrarotto Hospital, University of Catania, Via Citelli 29 Catania 95124, Italy. E-mail: melfat75@gmail.com

ISSN-1346-9843 doi:10.1253/circj.CJ-15-0447

All rights are reserved to the Japanese Circulation Society. For permissions, please e-mail: cj@j-circ.or.jp

Table 1. Transcatheter MV Intervention Devices Under Investigation				
Target of therapy	Device name & manufacturer	Access route (size)	Mechanism of action	Clinical status
Leaflet repair	MitraClip (Abbott Vascular, USA)	TV-TS (24Fr)	Clip-based edge-to-edge repair	CE mark approved FDA approved (DMR only)
	MitraFlex (TransCatheter Therapeutics, USA)	TA	Automatic capturing and connection of the approximate midpoint of the leaflets/implantation of an artificial chordae tendinae	Preclinical study underway
Indirect annuloplasty	Carillon (Cardiac Dimensions, USA)	TJ (9Fr)	Coronary sinus reshaping	CE mark approved
	Mitral Cerclage (NIH, USA)	TJ	Coronary sinus-right atrial encircling	Preclinical study underway
	Valcare (Valcare Medical, Israel)	TJ	Rigid D-shaped annuloplasty	Preclinical study underway
Direct annuloplasty	Mitralign (Mitralign, USA)	TF	2x2 plicating anchors through posterior annulus	CE mark trial completed USA feasibility trial planned
	Cardioband (Valtech, Israel)	TV-TS	Plicating anchors on atrial side of mitral annulus	CE mark trial underway
	Accucinch (Guided Delivery Systems, USA)	TF	Plicating anchors on ventricular side of mitral annulus	International feasibility trial underway
	Millipede (Millipede, USA)	TV-TS	Semirigid circumferential annular ring	Preclinical study underway
Chordal implantation	NeoChord (NeoChord, USA)	TA	Synthetic chordae tendinae	CE mark approved
MV implantation	CardiAQ (CardiAQ, USA)	TV-TS/TA (32Fr)	Self-positioning, self-anchoring, and self-conforming system for TMVI	First-in-man study completed
	Fortis (Edwards, USA)	TA/TV-TS	TMVI technology designed to minimize PVL	First-in-man study completed
	Tiara (Neovasc, USA)	TA/TV-TS (32Fr)	Self-expanding bovine pericardial, D-shaped trileaflet MV	First-in-man study completed
	Tendyne (Tendyne Holdings, USA)	TA (30Fr)	Fully retrievable, self-expanding trileaflet porcine pericardial valve sewn onto a nitinol frame/atrial and ventricular fixation system	First-in-man study completed
	Medtronic TMVR (Medtronic, USA)	TA/TV-TS	Self-expanding nitinol scaffold and a bovine pericardial valve with 3 cusps/recapturable and retrievable	Preclinical study underway
	Cardiovalve (Valtech, Israel)	TV-TS (26Fr)	TMVI system that can be delivered using a TF delivery system in a 2-step implantation procedure	Preclinical study underway

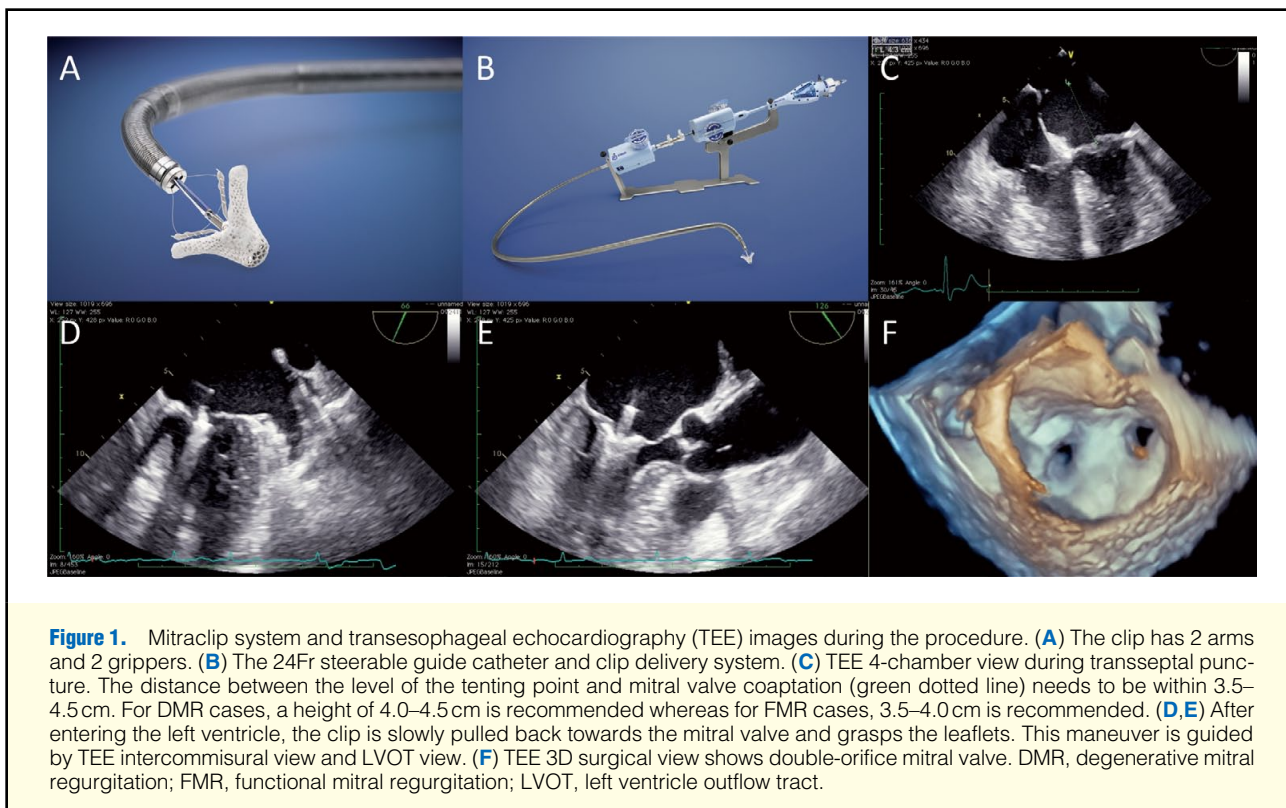
DMR, degenerative mitral regurgitation; Fr, French; MV, mitral valve; PVL, paravalvular leakage; TA, transapical; TAt, transatrially; TF, trans-femoral; TJ, transjugular; TMVI, transcatheter MV implantation; TS, transseptal; TV, transvenous.

to grasp the free edges of the mitral leaflets (Figures 1D,E), the grippers are dropped, and the clip is closed and released, imitating a surgical edge-to-edge repair that corrects the MR by suturing the leaflet edges at the site of regurgitation to create a double-orifice valve (Figure 1F).¹¹ Multiple clips may be safely placed, if necessary. The MitraClip has CE mark approval for general use, and Food and Drug Administration approval in the United States for treatment of symptomatic patients with severe primary DMR at prohibitive risk for MV surgery, but it is not currently approved for secondary FMR.

Evidence From the EVEREST II Trial

The Endovascular Valve Edge-to-Edge REpair Study (EVEREST II) was a randomized, controlled trial conducted to evaluate the safety and effectiveness of the MitraClip compared with MV surgery (repair or replacement).¹² The primary safety endpoint was the incidence of major adverse events

(MAEs) at 30 days, whereas the primary efficacy endpoint was freedom from death, surgery for MV dysfunction, or MR grade $\geq 3+$ at 12-month follow-up after clip implantation. The study cohort included DMR in 74% and FMR in 26% of patients. Acute device success, defined as residual MR $\leq 2+$ after the procedure, was achieved in 77% of the patients. The study met its primary efficacy non-inferiority endpoint vs. surgery. Although MAEs were significantly lower in the device group (15% vs. 48%), this difference was almost entirely attributable to the inclusion of transfusion of ≥ 2 units of blood as an adverse event. At 5-year follow-up, patients treated with the MitraClip system were reported to more frequently require MV surgery to treat residual MR compared with the surgical group (25.7% vs. 7.5%), although no differences were observed after 1-year follow-up (presented by Kar S, EuroPCR 2014, unpublished data, Paris). In addition, no mortality differences were observed at 5-year follow-up (18.8% vs. 21.0%). Subgroup analysis of



the randomized EVEREST II results suggested that older patients with FMR rather than DMR had outcomes most similar to conventional surgery.¹³ It is important to note that surgical repair after failed MitraClip deployment is feasible, although more extensive valve scarring after clip implantation may necessitate valve replacement.¹⁴ A total of 37 of 178 MitraClip patients in EVEREST II underwent open MV surgery within 12 months of implant. Valve repair was possible in 20 patients, and valve replacement was required in 17 patients. Although occasionally MV replacement is required after MitraClip implantation, because of MV injury or difficulty in removing the clip especially after 30 days because of fibrosis and scarring of the leaflets, the presence of the MitraClip itself was not found to be a major predictor of valve replacement. Conversely, replacement was strongly associated with anterior or bileaflet MV pathology, which is also a known predictor of valve replacement during surgical repair.¹⁵

Evidence From Registries

Numerous MitraClip registries have demonstrated high rates of procedural success and favorable short-term outcomes (Table 2).^{16–27} A recent pooled analysis of 351 patients in the EVEREST II High Risk Registry and the REALISM (Real World Expanded Multi-center Study of the MitraClip System) Continued Access Study demonstrated an implantation success of 96%.¹⁹ These patients were all considered high risk for surgery (estimated Society of Thoracic Surgeons score >12%). Most patients in this cohort had FMR (70%); 86% of surviving patients experienced MR reduction to $\leq 2+$ with significant reduction in LV volume at 12 months, and durable MR reduction at 24 months (84%). In addition, 83% of patients were classified as New York Heart Association (NYHA) functional class I/II at 12 months, with improvements in physical and

mental components according to the SF-36 quality of life questionnaire, and annual hospitalization rates for heart failure reduced from 0.79% before the procedure to 0.41% post-procedure.

ACCESS-EU (MitraClip Therapy Economic and Clinical Outcomes Study Europe) is another recent multicenter study with a total of 567 patients at 14 European sites, which demonstrated an implant success rate of 99.6%.¹⁸ The 30-day and 1-year mortality rates were 3.4% and 19%, respectively. By 1 year, open MV surgery was necessary in 6.3% of patients, 3.4% of patients required a second MitraClip procedure to treat residual MR, and the incidence of 3–4+ MR was 21%. Among the 1-year survivors, 71% were in NYHA functional class I/II with improvements in 6-min walk test and quality of life scores. Similar findings were demonstrated in the European Sentinel Registry, in which most patients treated were elderly, had multiple comorbidities, and were high-risk surgical candidates.¹⁷ Most patients in this cohort had FMR (72%). Acute procedural success was high (95.4%) and similar for FMR and DMR. In-hospital mortality was low (2.9%), without significant differences between groups. The estimated 1-year mortality was 15.3%, which was similar for FMR and DMR. Paired echocardiographic data of baseline and 1-year follow-up showed a persistent reduction in the degree of MR at 1 year.

MitraClip in Subsets of Interest

MitraClip therapy has been proven to maintain high rates of procedural success and to be clinically effective even in high-risk subsets. A retrospective multicenter analysis suggested a clear clinical benefit in 50 patients with LV ejection fraction $\leq 25\%$.²⁸ The 6-month survival was 81.2% and improved functional class as well as LV reverse remodeling were demon-

Table 2. MitraClip Registries: Baseline Characteristics, Acute Procedural Success, and 30-Day/1-Year Outcomes

Registry	n	Age (years)	Risk Score*	NYHA III/IV	LVEF	FMR	Post MR $\leq 2+$	30-day mortality	1-year mortality
TRAMI ¹⁶	1,064	75	10%	87%	NA	71%	96%	5.7%	NA
European Sentinel ¹⁷	628	74	20%	86%	43%	72%	98%	3%	15.3%
ACCESS-EU ¹⁸	567	78	23%	85%	NA	77%	91%	3.4%	17.3%
EVEREST II and REALISM ¹⁹	351	76	11%	85%	48%	70%	86%	4.8%	22.8%
Treede et al ²⁰	202	75	44%	98%	44%	65%	92%	3.5%	10.4%
GRASP ²¹	171	71	7%	81%	37%	78%	93%	0.9%	14%
Neuss et al ²²	157	74	22%	100%	41%	73%	100%	7%	20%
MARS ²³	142	71	17%	68%	47%	54%	77%	5.6%	NA
Bozdag-Turan et al ²⁴	121	77	11%	96%	42%	59%	99%	3.3%	23.1%
Taramasso et al ²⁵	109	69	22%	82%	28%	100%	87%	1.8%	NA
Rudolph et al ²⁶	104	74	36%	100%	43%	66%	92%	3.8%	22%
MitraSwiss ²⁷	100	77	17%	82%	48%	62%	85%	4% (in-hospital)	15.4% (in-hospital)

*Mean or median risk score calculated by Society of Thoracic Surgeons score for TRAMI, EVEREST II and REALISM, GRASP, and Bozdag-Turan et al; others by the logistic EUROSCORE. ACCESS-EU, MitraClip Therapy Economic and Clinical Outcomes Study Europe; EVEREST II, Endovascular Valve Edge-to-Edge REpair STudy; FMR, functional mitral regurgitation; GRASP, Getting Reduction of Mitral Insufficiency by Percutaneous Clip Implantation; LVEF, left ventricular ejection fraction; MARS, MitraClip Asia-Pacific Registry; MR, mitral regurgitation; NYHA, New York Heart Association; REALISM, Real World Expanded Multi-center Study of the MitraClip System; TRAMI, Transcatheter Mitral Valve Interventions.

strated. In the European PERMIT-CARE (Percutaneous Mitral Valve Repair in Cardiac Resynchronization Therapy) trial, 51 severely symptomatic cardiac resynchronization therapy non-responders with significant FMR underwent device MitraClip therapy.²⁹ Overall, 30-day mortality was 4.2%, and the procedure was shown to be feasible, safe, and effective in demonstrating significant MR reduction, LV reverse remodeling, and improved functional class. Data from the GRASP (Getting Reduction of Mitral Insufficiency by Percutaneous Clip Implantation) registry²¹ has shown clinical benefits in severe symptomatic FMR patients with concomitant moderate/severe tricuspid regurgitation (TR) after MitraClip treatment (ie, improvement in MR, TR, and NYHA functional class). However, baseline moderate/severe TR remained an independent predictor for death and rehospitalization for heart failure at 12 months.³⁰ Patients from the initial experiences, as well as the ones included in the randomized controlled trial, however, had to fulfill strict echocardiographic criteria to be considered suitable for MitraClip therapy, which largely limited its indications. A recently published GRASP substudy demonstrated that patients who fulfilled the criteria used in the EVEREST II trial and those who did not fulfill them showed similar safety at 30 days and efficacy through 12-month follow-up after MitraClip implantation.³¹ Furthermore, both groups revealed statistically significant LV reverse remodeling at 12 months, but the between-group baseline differences were sustained. Those results therefore suggest potential room for expanding the indications of MitraClip implantation beyond the initial criteria proposed by the EVEREST study.

MitraClip: Current Status and Ongoing Directions

In aggregate, the published MitraClip data from real-world clinical practice demonstrate consistent safety and high procedural success rates, high clinical efficacy, and improved functional status and quality of life in patients who are considered high risk for mitral surgery. Importantly, the 5-year follow-up of the EVEREST II trial has demonstrated that this device can favorably affect reverse remodeling in patients with DMR or

FMR and no mitral annular dilatation up to at least 5 years despite annulus under-sizing not being achievable with the MitraClip device. The 2012 European Society of Cardiology/European Association for Cardio-Thoracic Surgery valve and heart failure guidelines provide a Class IIb (LOE: C) recommendation to consider MitraClip use in symptomatic patients with severe secondary MR, despite optimal medical therapy and CRT, who are deemed inoperable or at high surgical risk.⁵ TMVR for secondary MR did not receive an official recommendation in the 2014 ACCF/AHA valvular heart disease guidelines, although it is currently recommended with Class IIb (LOE: B) guidance for severe primary MR in symptomatic patients at prohibitive risk for MV surgery.⁶

In an attempt to expand these indications, 2 ongoing clinical trials are investigating the effectiveness of MitraClip for FMR patients after optimal medical therapy and CRT (if indicated). The COAPT (Clinical Outcomes Assessment of the MitraClip Percutaneous Therapy) Trial for High Surgical Risk (www.clinicaltrials.gov, identifier NCT01626079) will be the first study to show whether reducing MR has any effect on mortality or other clinical outcomes in heart failure patients with FMR. The RESHAPE-HF (Randomized Study of the MitraClip Device in Heart Failure Patients With Clinically Significant Functional Mitral Regurgitation) trial (www.clinicaltrials.gov, identifier NCT01772108) is a similar trial being conducted in Europe, which has been recently halted because of slow recruitment, with protocol modification ending with the initiation of the RESHAPE 2 study. While COAPT and RESHAPE 2 investigate the effectiveness of MitraClip in FMR patients beyond optimal medical therapy, the MATTERHORN (Mitral Valve Reconstruction for Advanced Insufficiency of Functional or Ischemic Origin) trial (www.clinicaltrials.gov, identifier NCT02371512) will compare MitraClip therapy and reconstructive MV surgery in patients with FMR. The results of these trials will clarify the role of the MitraClip in FMR.

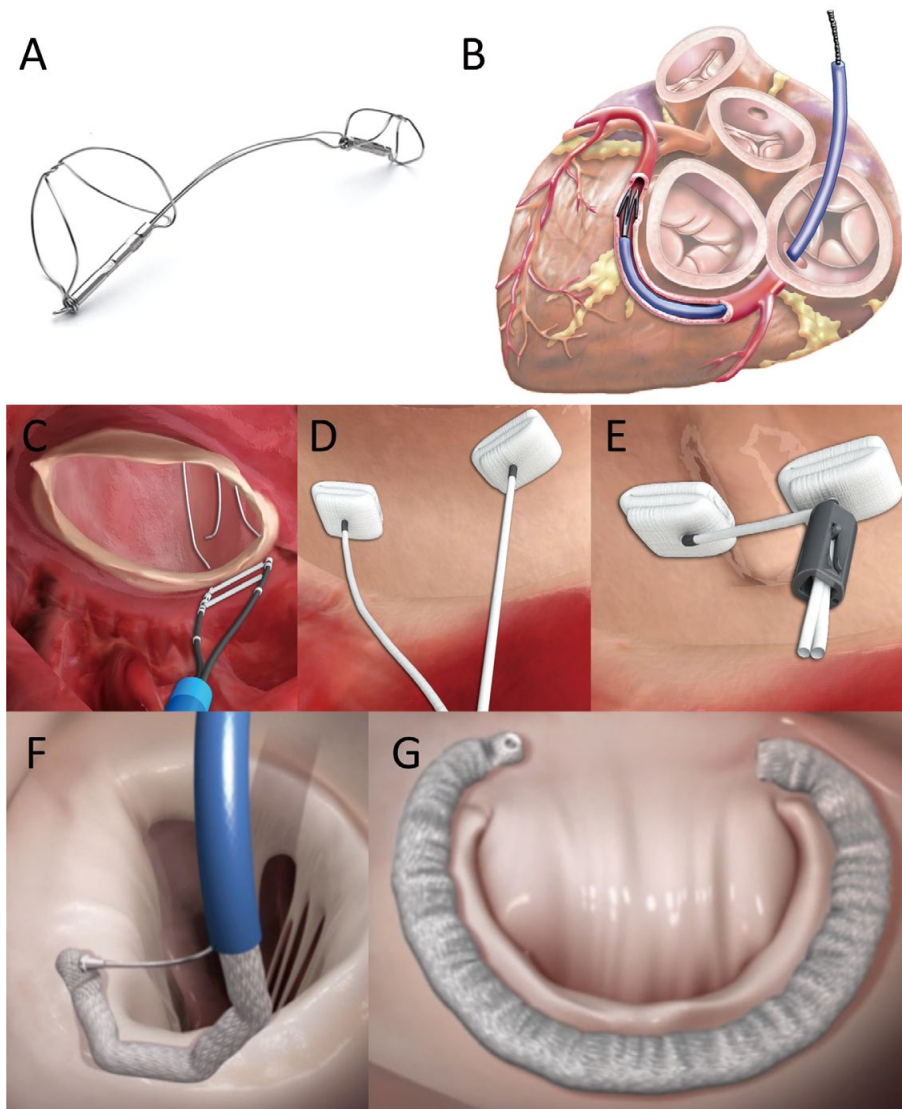


Figure 2. Indirect and direct annuloplasty devices. (A,B) Carillon coronary sinus annuloplasty device consists of self-expandable nitinol semihelical distal and proximal anchors connected by a nitinol bridge that are placed in the great cardiac vein and proximal coronary sinus. Tension generated by the system results in cinching of the posterior mitral annulus tissue anteriorly. (C–E) Mitralign annular plication device. In this procedure, a deflectable catheter is advanced retrogradely to the left ventricle and using radio-frequency energy the guidewires penetrate the mitral annulus into the left atrium (C), whereby pairs of pledgets are implanted in the posterior mitral annulus near the A1-P1 and A3-P3 target points (D). Each pledget pair can be pulled together, resulting in a segmental posterior annuloplasty (E). (F,G) Cardioband System uses a polyester prosthetic tube (band) sequentially fixed by helical anchors, from the anterolateral to the posteromedial trigone (F); after implantation, the annular circumference is reduced by controlling tension on the band under echo-guidance, thereby reducing the degree of mitral regurgitation (G).

Mitral Annuloplasty

Indirect Annuloplasty

Surgical plication of the mitral annulus with an undersized ring is the standard surgical treatment option for FMR and it is considered to be a key step in achieving effective and durable results after surgery.^{32,33} Lack of a reliable transcatheter annuloplasty device has so far affected eligibility for transcatheter interventions. In fact, up to one-third of patients screened for MitraClip are declined because of unfavorable anatomy, including annular dilatation.³⁴ Transcatheter annuloplasty may

therefore both improve outcomes and expand the therapeutic indications for MitraClip therapy.

The coronary sinus (CS) encircles the posterior mitral annulus, and it may allow devices to be delivered and indirectly affect the posterior mitral annulus geometry. Although the CS approach is theoretically a favorable procedure, it has some important limitations. Indeed, the CS is variably located at a certain distance from the mitral annulus (frequently increased in the case of severe MR with annular dilation), and circumflex coronary artery compression has been frequently observed.^{35,36} The Carillon Mitral Contour System (Cardiac Dimension, Inc,

Kirkland, WA, USA) (**Figures 2A,B**) consists of self-expandable nitinol semihelical distal and proximal anchors connected by a nitinol bridge that are placed in the great cardiac vein and proximal CS. Tension generated by the system results in cinching of the posterior mitral annulus tissue anteriorly. The device is implanted via the right internal jugular vein with a 9Fr delivery catheter and can be easily retrieved if MR reduction is not favorable or coronary artery compromise develops. A prospective, single-arm feasibility study named AMADEUS (CARILLON Mitral Annuloplasty Device European Union Study) was performed to examine the safety and efficacy of the Carillon device for the treatment of FMR.³⁶ Treated patients demonstrated significant reduction in mitral annular diameter and MR by at least 1 grade and improvement in functional class and quality of life through 24 months follow-up. A second-generation device was used in the TITAN (The Transcatheter Implantation of the Carillon Mitral Annuloplasty Device) trial,³⁷ a prospective, nonrandomized study in which 53 patients with symptomatic FMR were enrolled for Carillon device therapy; 36 patients (68%) underwent successful permanent device implantation, and 17 devices were not implanted because of insufficient MR reduction (n=9) or transient coronary compromise (n=8). Patients who received the device had significant reductions in MR grade, favorable LV remodeling, and improved quality of life. The Carillon device received CE mark approval in Europe in 2011. Successful MitraClip therapy after failure of transcatheter MV annuloplasty with the Carillon device has been reported.³⁸ Recently reported, TITAN II was a prospective, single-arm, European multicenter clinical trial aimed at further evaluating an enhanced version of the Carillon system (presented by Haude M, TCT 2014, unpublished data, Washington DC). In the study, 30 patients at 5 sites were implanted with Carillon devices and were followed for 1 year. Enrolled patients represented a severely ill, advanced heart failure population at baseline, with an average NYHA functional class of III and an average LVEF of 33%. At 1 year, 80% of patients experienced at least 1 class improvement in NYHA functional class from baseline. It showed significant reductions in FMR assessed by quantitative measures (ie, regurgitant volume) and a low 30-day MAE rate of 2.8%.

Direct Annuloplasty

Implantation of devices directly into the mitral annulus more closely reproduces surgical annuloplasty. Only the posterior annulus is usually targeted for this purpose, because the anterior annulus remains a more challenging structure with its anatomical proximity to the aortic valve. Annular calcification, the presence of the circumflex artery nearby, and the potential for leaflet damage remain of concern for direct annuloplasty approaches. Access to the annulus can be either through transseptal puncture or retrograde through the aortic valve and the LV. The Mitralign Percutaneous Annuloplasty System (Mitralign, Tewksbury, MA, USA) (**Figures 2C–E**) is based on surgical suture plication of the annulus. In this procedure, a deflectable catheter is advanced retrogradely to the LV and guidewires penetrate the mitral annulus into the left atrium, whereby pairs of pledgets are implanted in the posterior mitral annulus near the A1-P1 and A3-P3 scallops target points.³⁹ Each pledget pair can be pulled together, resulting in a segmental posterior annuloplasty to shorten the annulus up to 17 mm. A prospective, single-arm feasibility and safety study is ongoing to obtain CE mark approval. Available data reported that 36 patients have been enrolled, and 24 treated; 5 of them have reached the 1-year follow-up. Although final results are not yet available, in the first 15 patients no procedural deaths and 1 case of cardiac tampon-

ade occurred. After 1 year, an average reduction of 1 grade of MR was observed, together with minimal reduction in LV dimensions.

The Cardioband System (Valtech Cardio Ltd, Or Yehuda, Israel) (**Figures 2F,G**) is a percutaneous-implantable surgical-like ring. Different from the previous devices, and similar to the MitraClip, it is delivered anterogradely via transseptal atrial access. Therefore, the ring is implanted in the atrial side of the mitral annulus. The Cardioband is a polyester prosthetic tube (band) sequentially fixed by helical anchors, from the anterolateral to the posteromedial trigone; after implantation, the annular circumference is reduced by controlling tension on the band under echo-guidance, thereby reducing the degree of MR. Early animal studies demonstrated the safety and feasibility in the device, and several patients have already had successful percutaneous implants.^{40,41} The 6-month follow-up data on patients implanted with the system at 6 sites throughout Europe was recently reported (presented by Nickenig G, ACC 2015, unpublished data, San Diego). It demonstrated a 100% procedural success rate in 35 patients, with more than 80% of patients experiencing a sustained reduction in the severity of FMR, improvements to NYHA functional class, 6-min walking test results and quality of life among patients, with no incidences of procedural mortality, severe bleeding or cardiac tamponade.

Chordal Implantation

A different approach to achieving transcatheter leaflet repair is off-pump adjustable chordal implantation. Synthetic chords can be implanted via a transapical or transseptal approach and are anchored between the LV myocardium and the leaflet. By adjusting the length of the chord, the MR can be reduced. This approach would be mainly for DMR.

The NeoChord system (Neochord, Inc, Minnetonka, MN, USA) is the only CE mark approved device, which places an anchor in the inner LV myocardium and another on the leaflet via a transapical approach and connects the 2 with a synthetic chord. The Transapical Artificial Chordae Tendinae (TACT) phase I clinical study with NeoChord enrolled 30 patients at 7 centers in Europe.⁴² The procedure has been demonstrated to be a safe and effective minimally invasive alternative to open surgical repair in selected patients with mitral leaflet prolapse (flail/chordae rupture). More than 150 patients have been treated to date.

Transcatheter Mitral Valve Implantation

Since the introduction of transcatheter aortic valve implantation (TAVI), there has been an emerging growth of interest in percutaneous approaches to other valvular diseases. TMVI may have the potential to become an alternative to treating severe MR in high surgical risk patients because of its theoretical possibility to reduce MR to a similar extent as surgery while reducing procedural risks. Transcatheter heart valves for antegrade transseptal and apical delivery are currently being tested in bench and preclinical models.⁴³ Clinical experience with these devices remains scarce. Although the use of TAVI valves in the mitral position in patients with dysfunctional mitral bioprosthetic valves and annuloplasty rings has shown feasibility and proof of concept,^{44,45} there remain many challenges in treating the diseased native MV. The MV anatomy carries unique and complex features that make TMVI much more challenging than TAVI. The mitral annulus is asymmetrical, nontubular, and frequently not calcified; therefore, anchoring of the bioprosthesis

to the mitral annulus would be a problem because radial force would not be effective and could cause serious complications. LV outflow tract obstruction and aortic valve deformation (that could derive from a large and rigid mitral stent) are also major concerns. Moreover, leaks in the mitral position would be poorly tolerated, both hemodynamically and in terms of hemolysis because of the elevated pressure gradients. MV implantation is not yet routinely available in the clinical setting, but several devices are currently under development. Although multiple technical challenges are still present, technological evolution will likely overcome these challenges and would enable this procedure to be a valuable alternative to MV surgery for high surgical risk patients.

Conclusions

Transcatheter approaches for severe MR have emerged during the past decade as a viable, less invasive therapeutic option in patients with high surgical risk. TMVR with the MitraClip system has proven excellent safety and good efficacy in high-risk patients and is already considered as a mature procedure when performed in experienced centers. Other TMVR devices are still in their early experiences. TMVI aims to become a technically simple and reproducible procedure. However, durability, safety and possible disruption of adjacent cardiac structures remain important concerns. It is important to emphasize that novel transcatheter techniques for the treatment of MR are not meant to replace surgical techniques in lower risk patients who are good candidates for surgery. Because various transcatheter MV intervention devices will be available in the future, it is of particular importance to understand how to tailor the right device or strategy to the right patient and clinical setting. Careful patient selection with the heart-team approach will undoubtedly play a critical role in defining the clinical niche for successful transcatheter interventions.

Funding Sources

Y.O. is supported by a grant from the Japan Heart Foundation and Bayer Yakuhin Research Grant Abroad.

Disclosures

C.G. is a proctor for Abbott Vascular. D.C. has received consulting honoraria from Abbott Vascular. All the other authors have no relationships relevant to the contents of this paper to disclose.

References

- Okura H, Takada Y, Yamabe A, Ozaki T, Yamagishi H, Toda I, et al. Prevalence and correlates of physiological valvular regurgitation in healthy subjects. *Circ J* 2011; **75**: 2699–2704.
- Nkomo VT, Gardin JM, Skelton TN, Gottdiener JS, Scott CG, Enriquez-Sarano M. Burden of valvular heart diseases: A population-based study. *Lancet* 2006; **368**: 1005–1011.
- Otsuji Y, Handschumacher MD, Schwammenthal E, Jiang L, Song JK, Guerrero JL, et al. Insights from three-dimensional echocardiography into the mechanism of functional mitral regurgitation: Direct in vivo demonstration of altered leaflet tethering geometry. *Circulation* 1997; **96**: 1999–2008.
- Agricola E, Ielasi A, Oppizzi M, Faggiano P, Ferri L, Calabrese A, et al. Long-term prognosis of medically treated patients with functional mitral regurgitation and left ventricular dysfunction. *Eur J Heart Fail* 2009; **11**: 581–587.
- Joint Task Force on the Management of Valvular Heart Disease of the European Society of Cardiology (ESC); European Association for Cardio-Thoracic Surgery (EACTS), Vahanian A, Alfieri O, Andreotti F, Antunes MJ, Barón-Esquivias G, Baumgartner H, et al. Guidelines on the management of valvular heart disease (version 2012). *Eur Heart J* 2012; **33**: 2451–2496.
- Nishimura RA, Otto CM, Bonow RO, Carabello BA, Erwin JP 3rd, Guyton RA, et al. 2014 AHA/ACC Guideline for the management

of patients with valvular heart disease: Executive summary: A report of the American College of Cardiology/American Heart Association Task Force on Practice Guidelines. *J Am Coll Cardiol* 2014; **63**: 2438–2488.

- Mihaljevic T, Lam BK, Rajeswaran J, Takagaki M, Lauer MS, Gillinov AM, et al. Impact of mitral valve annuloplasty combined with revascularization in patients with functional ischemic mitral regurgitation. *J Am Coll Cardiol* 2007; **49**: 2191–2201.
- Goel SS, Bajaj N, Aggarwal B, Gupta S, Poddar KL, Ige M, et al. Prevalence and outcomes of unoperated patients with severe symptomatic mitral regurgitation and heart failure: Comprehensive analysis to determine the potential role of MitraClip for this unmet need. *J Am Coll Cardiol* 2014; **63**: 185–186.
- Biancari F, Schifano P, Pighi M, Vasques F, Juvonen T, Vinco G. Pooled estimates of immediate and late outcome of mitral valve surgery in octogenarians: A meta-analysis and meta-regression. *J Cardiothorac Vasc Anesth* 2013; **27**: 213–219.
- Munkholm-Larsen S, Wan B, Tian DH, Kearney K, Rahnavardi M, Dixen U, et al. A systematic review on the safety and efficacy of percutaneous edge-to-edge mitral valve repair with the MitraClip system for high surgical risk candidates. *Heart* 2014; **100**: 473–478.
- Alfieri O, Maisano F, De Bonis M, Stefano PL, Torracca L, Oppizzi M, et al. The double-orifice technique in mitral valve repair: A simple solution for complex problems. *J Thorac Cardiovasc Surg* 2001; **122**: 674–681.
- Feldman T, Foster E, Glower DD, Kar S, Rinaldi MJ, Fail PS, et al. Percutaneous repair or surgery for mitral regurgitation. *N Engl J Med* 2011; **364**: 1395–1406.
- Mauri L, Foster E, Glower DD, Apruzzese P, Massaro JM, Herrmann HC, et al. 4-year results of a randomized controlled trial of percutaneous repair versus surgery for mitral regurgitation. *J Am Coll Cardiol* 2013; **62**: 317–328.
- Geidel S, Schmoeckel M. Impact of failed mitral clipping on subsequent mitral valve operations. *Ann Thorac Surg* 2014; **97**: 56–63.
- Glower D, Ailawadi G, Argenziano M, Mack M, Trento A, Wang A, et al. EVEREST II randomized clinical trial: Predictors of mitral valve replacement in de novo surgery or after the MitraClip procedure. *J Thorac Cardiovasc Surg* 2012; **143**: S60–S63.
- Schillinger W, Hunlich M, Baldus S, Ouarrak T, Boekstegers P, Hink U, et al. Acute outcomes after MitraClip therapy in highly aged patients: Results from the German TRANscatheter Mitral valve Interventions (TRAMI) Registry. *EuroIntervention* 2013; **9**: 84–90.
- Nickenig G, Estevez-Loureiro R, Franzen O, Tamburino C, Vanderheyden M, Luscher TF, et al. Percutaneous mitral valve edge-to-edge repair: In-hospital results and 1-year follow-up of 628 patients of the 2011–2012 Pilot European Sentinel Registry. *J Am Coll Cardiol* 2014; **64**: 875–884.
- Maisano F, Franzen O, Baldus S, Schafer U, Hausleiter J, Butter C, et al. Percutaneous mitral valve interventions in the real world: Early and 1-year results from the ACCESS-EU, a prospective, multicenter, nonrandomized post-approval study of the MitraClip therapy in Europe. *J Am Coll Cardiol* 2013; **62**: 1052–1061.
- Glower DD, Kar S, Trento A, Lim DS, Bajwa T, Quesada R, et al. Percutaneous mitral valve repair for mitral regurgitation in high-risk patients: Results of the EVEREST II study. *J Am Coll Cardiol* 2014; **64**: 172–181.
- Treede H, Schirmer J, Rudolph V, Franzen O, Knap M, Schluter M, et al. A heart team's perspective on interventional mitral valve repair: Percutaneous clip implantation as an important adjunct to a surgical mitral valve program for treatment of high-risk patients. *J Thorac Cardiovasc Surg* 2012; **143**: 78–84.
- Grasso C, Capodanno D, Scandura S, Cannata S, Imme S, Mangiafico S, et al. One- and twelve-month safety and efficacy outcomes of patients undergoing edge-to-edge percutaneous mitral valve repair (from the GRASP Registry). *Am J Cardiol* 2013; **111**: 1482–1487.
- Neuss M, Schau T, Schoepp M, Seifert M, Holschermann F, Meyhofer J, et al. Patient selection criteria and midterm clinical outcome for MitraClip therapy in patients with severe mitral regurgitation and severe congestive heart failure. *Eur J Heart Fail* 2013; **15**: 786–795.
- Yeo KK, Yap J, Yamen E, Muda N, Tay E, Walters DL, et al. Percutaneous mitral valve repair with the MitraClip: Early results from the MitraClip Asia-Pacific Registry (MARS). *EuroIntervention* 2014; **10**: 620–625.
- Bozdag-Turan I, Paranskaya L, Birkemeyer R, Turan RG, Kische S, Akin I, et al. Percutaneous mitral repair with the MitraClip system in patients with mild-to-moderate and severe heart failure: A single-centre experience. *Cardiovasc Ther* 2014; **32**: 66–73.
- Taramasso M, Maisano F, Latib A, Denti P, Buzzatti N, Cioni M, et al. Clinical outcomes of MitraClip for the treatment of functional mitral regurgitation. *EuroIntervention* 2014; **10**: 746–752.

26. Rudolph V, Knap M, Franzen O, Schluter M, de Vries T, Conradi L, et al. Echocardiographic and clinical outcomes of MitraClip therapy in patients not amenable to surgery. *J Am Coll Cardiol* 2011; **58**: 2190–2195.
27. Surder D, Pedrazzini G, Gaemperli O, Biaggi P, Felix C, Rufibach K, et al. Predictors for efficacy of percutaneous mitral valve repair using the MitraClip system: The results of the MitraSwiss registry. *Heart* 2013; **99**: 1034–1040.
28. Franzen O, van der Heyden J, Baldus S, Schluter M, Schillinger W, Butter C, et al. MitraClip(R) therapy in patients with end-stage systolic heart failure. *Eur J Heart Fail* 2011; **13**: 569–576.
29. Auricchio A, Schillinger W, Meyer S, Maisano F, Hoffmann R, Ussia GP, et al. Correction of mitral regurgitation in nonresponders to cardiac resynchronization therapy by MitraClip improves symptoms and promotes reverse remodeling. *J Am Coll Cardiol* 2011; **58**: 2183–2189.
30. Ohno Y, Attizzani GF, Capodanno D, Cannata S, Dipasqua F, Imme S, et al. Association of tricuspid regurgitation with clinical and echocardiographic outcomes after percutaneous mitral valve repair with the MitraClip System: 30-day and 12-month follow-up from the GRASP Registry. *Eur Heart J Cardiovasc Imaging* 2014; **15**: 1246–1255.
31. Attizzani GF, Ohno Y, Capodanno D, Cannata S, Dipasqua F, Imme S, et al. Extended use of percutaneous edge-to-edge mitral valve repair beyond EVEREST (Endovascular Valve Edge-to-Edge Repair) criteria: 30-day and 12-month clinical and echocardiographic outcomes from the GRASP (Getting Reduction of Mitral Insufficiency by Percutaneous Clip Implantation) registry. *JACC Cardiovasc Interv* 2015; **8**: 74–82.
32. Gillinov AM, Cosgrove DM, Blackstone EH, Diaz R, Arnold JH, Lytle BW, et al. Durability of mitral valve repair for degenerative disease. *J Thorac Cardiovasc Surg* 1998; **116**: 734–743.
33. Nardi P, Pellegrino A, Scafuri A, Olevano C, Bassano C, Zeitani J, et al. Survival and durability of mitral valve repair surgery for degenerative mitral valve disease. *J Card Surg* 2011; **26**: 360–366.
34. Grayburn PA, Roberts BJ, Aston S, Anwar A, Hebel RF Jr, Brown DL, et al. Mechanism and severity of mitral regurgitation by transesophageal echocardiography in patients referred for percutaneous valve repair. *Am J Cardiol* 2011; **108**: 882–887.
35. Maselli D, Guarracino F, Chiaromonte F, Mangia F, Borelli G, Minzioni G. Percutaneous mitral annuloplasty: An anatomic study of human coronary sinus and its relation with mitral valve annulus and coronary arteries. *Circulation* 2006; **114**: 377–380.
36. Schofer J, Siminiak T, Haude M, Herrman JP, Vainer J, Wu JC, et al. Percutaneous mitral annuloplasty for functional mitral regurgitation: Results of the CARILLON Mitral Annuloplasty Device European Union Study. *Circulation* 2009; **120**: 326–333.
37. Siminiak T, Wu JC, Haude M, Hoppe UC, Sadowski J, Lipiecki J, et al. Treatment of functional mitral regurgitation by percutaneous annuloplasty: Results of the TITAN Trial. *Eur J Heart Fail* 2012; **14**: 931–938.
38. Grasso C, Attizzani GF, Ohno Y, Dipasqua F, Mangiafico S, Ministeri M, et al. Catheter-based edge-to-edge mitral valve repair after percutaneous mitral valve annuloplasty failure. *JACC Cardiovasc Interv* 2014; **7**: e85–e86, doi:10.1016/j.jcin.2013.11.027.
39. Siminiak T, Dankowski R, Baszko A, Lee C, Firek L, Kalmucki P, et al. Percutaneous direct mitral annuloplasty using the Mitralign Bident system: Description of the method and a case report. *Kardiol Pol* 2013; **71**: 1287–1292.
40. Maisano F, Vanermen H, Seeburger J, Mack M, Falk V, Denti P, et al. Direct access transcatheter mitral annuloplasty with a sutureless and adjustable device: Preclinical experience. *Eur J Cardiothorac Surg* 2012; **42**: 524–529.
41. Maisano F, La Canna G, Latib A, Denti P, Taramasso M, Kuck KH, et al. First-in-man transseptal implantation of a “surgical-like” mitral valve annuloplasty device for functional mitral regurgitation. *JACC Cardiovasc Interv* 2014; **7**: 1326–1328.
42. Seeburger J, Rinaldi M, Nielsen SL, Salizzoni S, Lange R, Schoenburger M, et al. Off-pump transapical implantation of artificial neo-chordae to correct mitral regurgitation: The TACT Trial (Transapical Artificial Chordae Tendinae) proof of concept. *J Am Coll Cardiol* 2014; **63**: 914–919.
43. De Backer O, Piazza N, Banai S, Lutter G, Maisano F, Herrmann HC, et al. Percutaneous transcatheter mitral valve replacement: An overview of devices in preclinical and early clinical evaluation. *Circ Cardiovasc Interv* 2014; **7**: 400–409.
44. Cheung A, Webb JG, Barbanti M, Freeman M, Binder RK, Thompson C, et al. 5-year experience with transcatheter transapical mitral valve-in-valve implantation for bioprosthetic valve dysfunction. *J Am Coll Cardiol* 2013; **61**: 1759–1766.
45. Boulet C, Fassa AA, Himbert D, Brochet E, Ducrocq G, Nejari M, et al. Transfemoral implantation of transcatheter heart valves after deterioration of mitral bioprosthesis or previous ring annuloplasty. *JACC Cardiovasc Interv* 2015; **8**: 83–91.