

## Immunohistochemical expression of TLR-4 in temporomandibular joint dysfunction

Luis Eduardo Almeida, Kyle Hresko, Adam Sorenson, Seth Butcher, Lobat Tayebi, Rosalia Leonardi, Carla Loreto, Jose Bosio, Flavio Camejo & Andrea Doetzer

To cite this article: Luis Eduardo Almeida, Kyle Hresko, Adam Sorenson, Seth Butcher, Lobat Tayebi, Rosalia Leonardi, Carla Loreto, Jose Bosio, Flavio Camejo & Andrea Doetzer (2019) Immunohistochemical expression of TLR-4 in temporomandibular joint dysfunction, CRANIO®, 37:5, 323-328, DOI: [10.1080/08869634.2018.1446770](https://doi.org/10.1080/08869634.2018.1446770)

To link to this article: <https://doi.org/10.1080/08869634.2018.1446770>



Published online: 02 Apr 2018.



Submit your article to this journal [↗](#)



Article views: 105

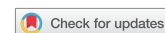

View related articles [↗](#)







View Crossmark data [↗](#)

TMJ



## Immunohistochemical expression of TLR-4 in temporomandibular joint dysfunction

Luis Eduardo Almeida DDS, MS, PhD<sup>a</sup> , Kyle Hresko BS<sup>a</sup>, Adam Sorenson BS<sup>a</sup>, Seth Butcher BS<sup>a</sup>, Lobat Tayebi PhD<sup>a</sup>, Rosalia Leonardi DDS, PhD<sup>b</sup>, Carla Loreto MD, PhD<sup>b</sup>, Jose Bosio MS, DDS<sup>c</sup> , Flavio Camejo DDS, PhD<sup>d</sup>  and Andrea Doetzer DDS, MS, PhD<sup>e</sup> 

<sup>a</sup>Oral Surgery, Surgical Sciences Department, School of Dentistry, Marquette University, Milwaukee, WI, USA; <sup>b</sup>Department of Bio-Medical Sciences, Anatomy Section, University of Catania, Catania, Italy; <sup>c</sup>Orthodontic Department, School of Dentistry, University of Maryland, Baltimore, MD, USA; <sup>d</sup>Dentistry, Unisociesc, Joinville, Brazil; <sup>e</sup>School of Health and Bioscience, Pontifical Catholic University of Parana State, Curitiba, Brazil

### ABSTRACT

**Objective:** Toll-like receptor 4 (TLR-4) is a transmembrane protein involved in the innate immune system and has been implicated in the pathogenesis of temporomandibular joint dysfunction (TMD). The purpose of this study was to histologically examine the level of expression of TLR-4 relative to severity of TMD.

**Methods:** Thirty-one human TMJ disc samples were immunostained for TLR-4 and evaluated for intensity of stain. Among the samples, 8 were control samples, 16 were from patients with anterior disc displacement with reduction (ADDwR), and 7 were from patients with anterior disc displacement without reduction (ADDwoR).

**Results:** There was no statistically significant difference in intensity of stain between groupings ( $p = 0.673$ ).

**Conclusions:** The results indicate a negative correlation between TMD and the expression of TLR-4.

### KEYWORDS

Temporomandibular joint; inflammation; TLR4; disc

## Introduction

The temporomandibular joint (TMJ) is subjected to constant destructive forces through function, which is paired with the body's ability to adapt [1]. The TMJ dysfunction (TMD) disease process, which commonly initiates during puberty, has several associated risk factors, such as female sex, hypermobility, and trauma [2]. In the healthy joint, the disc rests between the condylar head of the mandible and the articular surface of the temporal bone [3]. Following the onset of joint dysfunction, the temporomandibular disc undergoes structural changes, which may result in an anterior disc displacement, which may reduce to a normal functional position or not [4]. This first stage of TMD is called anterior disc displacement with reduction (ADDwR), and in more advanced cases, the disc remains anteriorly displaced throughout function, never reducing into proper physiological position, known as anterior disc displacement without reduction (ADDwoR) [4].

Functional stresses on the TMJ activate a continuous process of extracellular matrix degradation and synthesis [1]; nevertheless, if functional demands exceed the

ability to adapt, an inflammatory process is initiated, and a cartilaginous breakdown occurs [5]. Although the exact biochemical mechanism by which this breakdown occurs is yet to be understood, several theories exist [6–9]. There is an established linkage between the degree of TMJ dysfunction and the level of inflammation, which presents as an upregulation of proinflammatory cytokines IL-1(beta) and TNF-(alpha) [10–14]. This linkage has also been shown in patients with TMD resulting from rheumatoid arthritis. However, in these cases, TNF- $\alpha$  was found to correlate to the level of condylar erosion [15].

Similarly, toll-like receptor 4 (TLR-4) is understood to participate in inflammatory processes. TLR-4 is a transmembrane protein responsible for activation of the MyD88-dependent inflammatory pathway, ultimately resulting in upregulation of proinflammatory mediators such as TNF-alpha and IL-1beta. Recent publications have re-evaluated TLR-4 for its potential role in the pathogenesis of TMJ pathologies [16,17]. Only recently has TLR-4 been implicated in identification of danger-associated molecular patterns (DAMPs). DAMPs are endogenous signals suggesting cellular distress, even in the absence of

certain exogenous materials. Several of these ligands have been shown to exert their effects on TLR-4 even in the absence of lipopolysaccharide (LPS), its most well-known ligand [17]. This would indicate a true agonist role, and not just as an assistant to LPS. TLR-4 has been extensively studied and associated with rheumatoid arthritis patients' joints; however, there is no study of how this protein acts on joints with dysfunction but with no rheumatoid arthritis.

Thus, the purpose of this study was to investigate the role of TLR-4 in the pathogenesis of TMD.

## Materials and methods

A total of 31 disc samples were collected from Caucasian female patients treated between 2002 and 2009 at the Hospital Universitario Evangelico de Curitiba (Table 1).

Eight virtually unaffected human discs were included in the control group for the study. Exclusion criteria for the subjects included: use of orthodontic appliances; chronic usage of anti-inflammatory drugs; history of diabetes, hepatitis, or HIV infection; immunosuppressive chemotherapy; history of any disease known to severely compromise immune function; current pregnancy or

lactation; dentofacial deformity; comorbidities of the TMJ; pain related to muscular spasms alone; major jaw trauma previously; previous TMJ surgery; or previous steroid injection in the TMJ. The subjects completed personal medical history questionnaires and, within a protocol approved by an Institutional Review Board, signed a consent form after being advised of the nature of the study. All patients were asked to complete a pain questionnaire, and an experienced oral and maxillofacial surgeon performed a clinical examination. The clinical examination included palpation of the TMJ region, noting the occurrence of painful opening/closing of the mouth, and listening for crepitation. The patients considered to be affected were treated surgically when they presented painful clinical signs of disc displacement after unsuccessful non-surgical treatment for at least six months. For the complementary exams, all patients received a panoramic radiograph and MRI imaging studies. The subjects were included in clinical categories according to the presence or absence of disc displacement. The test group included a total of 23 samples of discs that were diagnosed with TMJ dysfunctions. This group was separated into ADDwR ( $n = 16$ ) and ADDwoR ( $n = 7$ ). The control group included a total of eight samples. The discs of these patients were removed for reasons other than TMJ dysfunction. Four of the patients presented with condyle fractures that were confirmed by radiographs and CT scans. These subjects were included, provided that no trauma had occurred prior to the event causing the condylar fracture and that the surgery was conducted up to 24 h after the trauma. Four other control samples were obtained from patients who displayed active condylar hyperplasia. Wedges of the control discs were removed from the posterior regions so that the disc could physiologically adapt to the head of the condyle during function.

**Table 1.** Clinical data of patients reported.

Patient	Age (yrs)	Diagnosis	Affected side	
			Right	Left
1	33	ADDwR	×	
2	26	ADDwR	×	
3	26	ADDwR		×
4	30	ADDwR		×
5	25	ADDwR		×
6	25	ADDwR	×	
7	37	ADDwR	×	
8	37	ADDwR		×
9	20	ADDwR		×
10	36	ADDwR	×	
11	36	ADDwR		×
12	38	ADDwR	×	
13	38	ADDwR		×
14	22	ADDwR	×	
15	22	ADDwR		×
16	34	ADDwR		×
17	23	ADDwoR		×
18	23	ADDwoR	×	
19	26	ADDwoR		×
20	32	ADDwoR		×
21	32	ADDwoR	×	
22	35	ADDwoR	×	
23	24	ADDwoR		×
24	27	CF×		×
25	33	CF×	×	
26	42	CF×	×	
27	18	CF×		×
28	43	CH		×
29	17	CH		×
30	18	CH	×	
31	40	CH		×

Notes: YRS: years; ADDWOR: Anterior disc displacement without reduction; ADDWR: anterior disc displacement with reduction; CH: condylar hyperplasia; CF×: condylar fracture.

## Staining protocol

Sample slides were deparaffinized with a series of nine solvent baths in Coplin jars, each lasting for 5 min. The baths consisted of 100% xylene three times, 100% ethanol twice, 95% ethanol and 5% deionized water twice, and 100% deionized water twice.

In order to unmask all potential antigens, a 10 mM sodium citrate buffer was prepared and kept at a sub-boiling temperature until use. Samples were bathed in this buffer for a total of 40 min and were removed from the heat source to cool after 20 min.


To increase specificity, samples were sequentially exposed to a peroxidase suppressor, followed by a 5% bovine serum albumin (BSA) blocking buffer in phosphate buffered saline (PBS) for 30 min each.

Samples were incubated with TLR-4 primary antibody (Thermo Fisher Scientific, Rockford, IL, USA) for 30 min at 23°C. A 1:200 dilution of primary antibodies was synthesized from stock antibody and PBS. Biotinylated secondary antibodies were then incubated on samples under the same conditions for 30 min, with a dilution of 1:400 with PBS. Avidin-Biotin Complex (ABC) was generated according to manufacturer specifications and applied to samples following secondary antibody application, in order to amplify available signal. ABC incubation lasted for 30 min. Finally, a 1:9 dilution of 10 × 3.3'-diaminobenzidine (DAB) chromogen concentrate was prepared immediately before use and exposed to samples for exactly five min. Between each step in the staining protocol, samples were washed twice with PBS for five min each.

Slides were dehydrated by following the deparaffinization solvent bath process in reverse, with each bath lasting for 15 s.

### Evaluation protocol

TLR-4 staining was identified as either positive or negative for each disc. Positive staining was defined as the presence of brown chromogen detection, distributed within the cytoplasm or in the immediate lacunar/pericellular space. Three blinded observers evaluated the percentage of immunopositive cells. The observers scored the percentages based on a predetermined scale (0 ≤ 5%; 1 = 6–30%; 2 = 31–50%, 3 = 51–75%; 4 = 76–100%). Counting was performed at 200 × and 400 × magnification. The intensity of the staining was also categorized on a four-point predetermined scale (0 = no detectable staining, 1 = light staining, 2 = moderate staining, 3 = strong staining, and 4 = very strong staining). If the observers' grading disagreed by more than one point, the field of view that was being graded was thrown out and a new field of view was



**Figure 1.** Control group.

chosen. For each disc, five areas were analyzed for both percentage and intensity of staining.

### Statistical analysis

Stata/SE v.14.1. StataCorpLP, USA was used for the statistical analyses. Area and density were analyzed through media, median, standard deviation, minimum and maximum, and to evaluate the intensity normality, Shapiro-Wilk was used. The comparison of the three groups employed the non-parametric Kruskal-Wallis test. A value of  $p < 0.05$  indicated a statistical difference.

### Results

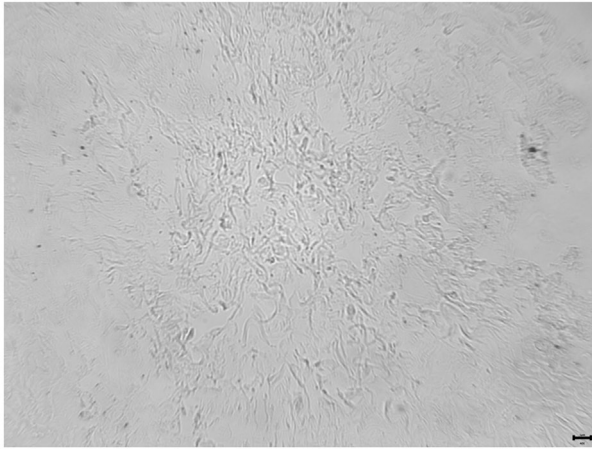
The presence of TLR-4 was confirmed through a specific immunohistochemical protocol. Background staining or noise was reduced to a minimum, with positive staining existing exclusively on fibroblasts with TLR-4 expression. Prevalence of staining for each sample was subjectively assessed, and values were used in a one-way ANOVA statistical analysis. A positive but non-significant trend in mean TLR-4 expression was seen between the control (Figure 1), ADDwR (Figure 2), and ADDwoR (Figure 3). The authors did not reach a statistically significant level for any pairings ( $p = 0.673$ ). Intensity of staining for each sample is displayed in Table 2 and Figure 4.

### Discussion

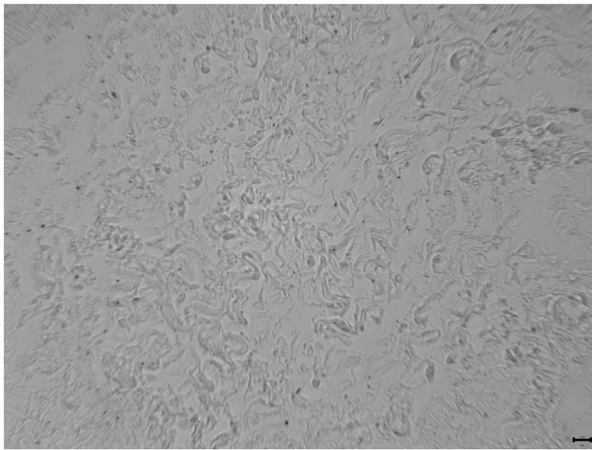
In a healthy TMJ, the adaptive and regenerative potential of the discal tissues is sufficient to match the destructive forces encountered during normal function. In diseased states, however, failure to maintain homeostasis leads to initiation of an inflammatory response, which has been shown to exacerbate dysfunctional conditions, as evidenced in TMJ-specific and more generalized osteoarthritic conditions [2,18]. While temporomandibular joint dysfunction may present an innocuous and transient occurrence, it may also develop into more serious presentations, characterized by failure to properly position the disc in its functioning position [2]. Symptoms may include clicking or popping on mandibular opening, muscle tenderness, limited mandibular opening, intermittent locking, and headaches.

The results of this study did not reach a level of significance, as an earlier animal model study stated, showing an increase in TLR-4 expression in TMJ dysfunction [19]. Studies have suggested that a number of endogenous molecules may be potent activators of the innate immune system, capable of inducing proinflammatory cytokine production and the activation of dendritic cells [19]. The results of this study showed a non-significant trend





**Figure 2.** Anterior disc displacement with reduction.



**Figure 3.** Anterior disc displacement without reduction.

between TLR-4 expression and level of internal derangement, from healthy to ADDwR, and finally to ADDwoR, which would follow the proposed mechanism in severity for TMJ dysfunctional states [6,20]. TLR-4 expression may be upregulated in patients with TMJ dysfunction, and TLR-4 may, therefore, play a role in the pathogenic inflammatory reaction, but further research is required. With a growing number of DAMPs or “alarmins” being identified as endogenous ligands for TLR-4, it seems possible that such pathways may be implicated in the generation of this disease. The disc is avascular, and TLR-4 may be contributing to TMD on synovial fluids and bilaminar tissues,

but by the results of this study, it would not be affecting disc degeneration directly. Perhaps it would be altering the inflammatory process of the TMJ environment and contributing to the complex inflammatory cascade, but not to the disc deterioration itself.

To date, no other study has evaluated expression of TLR-4 in patients with temporomandibular joint dysfunction while using otherwise healthy patients as controls. The unique control group of this study allows for otherwise unobtainable comparisons between the healthy and diseased states. The results of this study, therefore, have immediate clinical relevance in understanding the pathogenesis of dysfunction states.

Several weaknesses of this study exist and should be addressed when evaluating the strength of findings. Total sample size was small ( $n = 31$ ) and may have contributed to lack of significance. Control samples were not uniform, as half of the control samples were obtained following traumatic injuries, while the other half were from patients with condylar hyperplasia. The interval between sample collection and processing spanned between 8 and 15 years and may have introduced degradation of samples. Finally, evaluation of staining required identification of fibroblasts and assessment of staining within only that portion of the sample. Samples were assessed visually and, while blinding was present and evaluators were mostly in agreement, the evaluation was ultimately subjective. As TLR-4 is activated in inflammatory states, the authors believe that an upregulation characterized by increased intensity of staining within the cytoplasmic membrane is an appropriate modality for assessment of expression. Future photographic analysis of samples may reveal TLR-4 expression levels that differ from the assessment of the blinded evaluators used in this study.

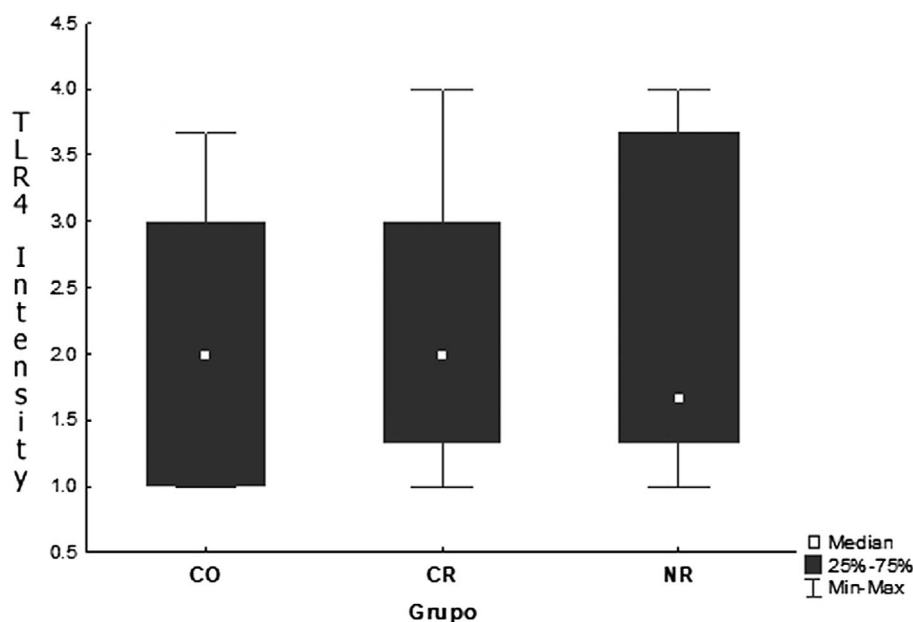
TLR-4 has been shown to be a marker of inflammation and as a potential target for therapy [15]. Several mediators, such as TAK-242 and MyD88 inhibitory peptide (MIP) have been shown to reduce inflammation by acting as an antagonist to TLR-4 and MyD88 in animals, respectively [15,21]. These treatment modalities might be incorporated into human treatments if an analogous inflammatory pathway is discovered in the pathogenesis of TMJ dysfunction. Furthermore, animal models have shown an upregulation of TLR-4 in the TMJ complex

**Table 2.** Intensity of fibroblast staining.

Group	<i>n</i>	Intensity of fibroblast staining					Standard deviation	<i>p</i> value*
		Mean	Median	Minimum	Maximum			
Control	8	2.08	2.00	1.000	2.00	2.00	0.673	
ADDwR	16	2.29	2.00	1.000	2.00	2.00		
ADDwoR	7	2.38	1.67	1.000	1.67	1.67		

Notes: *n*: number; ADDwR: anterior disc displacement with reduction; ADDwoR: anterior disc displacement without reduction.

\*One-way ANOVA and least significant difference test for multiple comparisons;  $p < 0.05$ .



**Figure 4.** Graphic plot showing intensity of staining.

Notes: CO = control; CR = with reduction; NR = without reduction.

when occlusal interferences are experimentally introduced [19]. Current literature suggests that arthroscopic lysis and lavage is effective in 77% of patients with early stages of TMJ dysfunction, with more severe manifestations often requiring invasive surgical procedures [22].

A better understanding of the inflammatory pathways leading to TMJ dysfunction may allow development of early pharmacological intervention techniques and allow for fewer patients to require open joint surgery.

## Conclusion

In this study, there was no statistically significant difference between the groups with and without TMJ dysfunction. Greater research and understanding of the inflammatory mechanisms that lead to TMJ dysfunction is a promising route towards developing additional treatment modalities for these conditions.

## Contributors

LEA, KH, AS, and AD were responsible for acquisition of research data, statistical analysis, and manuscript writing. SB, LT, and FC contributed to the data acquisition, to the writing of the manuscript, and text translation. RL and CL contributed to the data interpretation and to the writing of the manuscript. JB contributed to the statistical analysis, interpretation, and to the writing of the manuscript.

## Disclosure statement

No potential conflict of interest was reported by the authors.

## Funding

This work was supported by Marquette University School of Dentistry (2016 Student grant).

## ORCID

Luis Eduardo Almeida  <http://orcid.org/0000-0002-9802-3782>

Jose Bosio  <http://orcid.org/0000-0002-2713-4135>

Flavio Camejo  <http://orcid.org/0000-0003-1193-2375>

Andrea Doetzer  <http://orcid.org/0000-0003-3361-241X>

## References

- [1] Tanaka E, Detamore MS, Mercuri LG. Degenerative disorders of the temporomandibular joint: etiology, diagnosis, and treatment. *J Dent Res.* 2008 Apr;87(4):296–307.
- [2] Wang XD, Kou XX, Mao JJ, et al. Sustained inflammation induces degeneration of the temporomandibular joint. *J Dent Res.* 2012 May;91(5):499–505.
- [3] Okeson J. Management of temporomandibular disorders and occlusion. Mosby. [cited 2012 May 21]. p. 488.
- [4] Schiffman E, Ohrbach R, Truelove E, et al. Diagnostic criteria for temporomandibular disorders (DC/TMD) for clinical and research applications: recommendations of the international RDC/TMD consortium network and orofacial pain special interest group. *J Oral Facial Pain Headache.* 2014 Winter;28(1):6–27.
- [5] Puzas JE, Landeau JM, Tallents R, et al. Degradative pathways in tissues of the temporomandibular joint. Use of in vitro and in vivo models to characterize matrix metalloproteinase and cytokine activity. *Cells Tissues Organs.* 2001;169(3):248–256.
- [6] Kalladka M, Quek S, Heir G, et al. Temporomandibular joint osteoarthritis: diagnosis and long-term conservative

- management: a topic review. *J Indian Prosthodont Soc.* **2014** Mar;14(1):6–15.
- [7] Leonardi R, Loreto C, Barbato E, et al. A histochemical survey of the human temporomandibular joint disc of patients with internal derangement without reduction. *J Craniofac Surg.* **2007** Nov;18(6):1429–1433.
- [8] Nitzan DW. The process of lubrication impairment and its involvement in temporomandibular joint disc displacement: a theoretical concept. *J Oral Maxillofac Surg.* **2001** Jan;59(1):36–45.
- [9] Leonardi R, Musumeci G, Sicurezza E, et al. Lubricin in human temporomandibular joint disc: an immunohistochemical study. *Arch Oral Biol.* **2012** Jun;57(6):614–619.
- [10] Lee JK, Cho YS, Song SI. Relationship of synovial tumor necrosis factor alpha and interleukin 6 to temporomandibular disorder. *J Oral Maxillofac Surg.* **2010** May;68(5):1064–1068.
- [11] Güven O, Tekin U, Salmanoğlu B, et al. Tumor necrosis factor-alpha levels in the synovial fluid of patients with temporomandibular joint internal derangement. *J Craniomaxillofac Surg.* **2015** Jan;43(1):102–105.
- [12] Kaneyama K, Segami N, Yoshimura H, et al. Increased levels of soluble cytokine receptors in the synovial fluid of temporomandibular joint disorders in relation to joint effusion on magnetic resonance images. *J Oral Maxillofac Surg.* **2010** May;68(5):1088–1093.
- [13] Kim YK, Kim SG, Kim BS, et al. Analysis of the cytokine profiles of the synovial fluid in a normal temporomandibular joint: preliminary study. *J Craniomaxillofac Surg.* **2012** Dec;40(8):e337–e341.
- [14] Ahmed N, Petersson A, Catrina AI, et al. Tumor necrosis factor mediates temporomandibular joint bone tissue resorption in rheumatoid arthritis. *Acta Odontol Scand.* **2015** Apr;73(3):232–240.
- [15] Kong J, Yang Y, Sun S, et al. Effect of toll-like receptor 4 on synovial injury of temporomandibular joint in rats caused by occlusal interference. *Mediators Inflamm.* **2016**;2016:7694921.
- [16] Leonardi R, Almeida LE, Trevilatto PC, et al. Occurrence and regional distribution of TRAIL and DR5 on temporomandibular joint discs: comparison of disc derangement with and without reduction. *Oral Surg Oral Med Oral Pathol Oral Radiol Endod.* **2010** Feb;109(2):244–251.
- [17] Erridge C. Endogenous ligands of TLR2 and TLR4: agonists or assistants? *J Leukoc Biol.* **2010** June;87(6):989–999.
- [18] Sellam J, Berenbaum F. The role of synovitis in pathophysiology and clinical symptoms of osteoarthritis. *Nat Rev Rheumatol.* **2010** Nov;6(11):625–635.
- [19] Tsan MF, Gao B. Endogenous ligands of toll-like receptors. *J Leukoc Biol.* **2004** Sep;76(3):514–519.
- [20] Westesson PL, Bronstein SL, Liedberg J. Internal derangement of the temporomandibular joint: morphologic description with correlation to joint function. *Oral Surg Oral Med Oral Pathol.* **1985** Apr;59(4):323–331.
- [21] Lin X, Kong J, Wu Q, et al. Effect of TLR4/MyD88 signaling pathway on expression of IL-1 $\beta$  and TNF- $\alpha$  in synovial fibroblasts from temporomandibular joint exposed to lipopolysaccharide. *Mediators Inflamm.* **2015**;2015:329405.
- [22] Breik O, Devrukhkar V, Dimitroulis G. Temporomandibular joint (TMJ) arthroscopic lysis and lavage: outcomes and rate of progression to open surgery. *J Craniomaxillofac Surg.* **2016** Dec;44(12):1988–1995.