

IMAGES IN INTERVENTION



New-Onset Coronary Aneurism and Late-Acquired Incomplete Scaffold Apposition After Full Polymer Jacket of a Chronic Total Occlusion With Bioresorbable Scaffolds

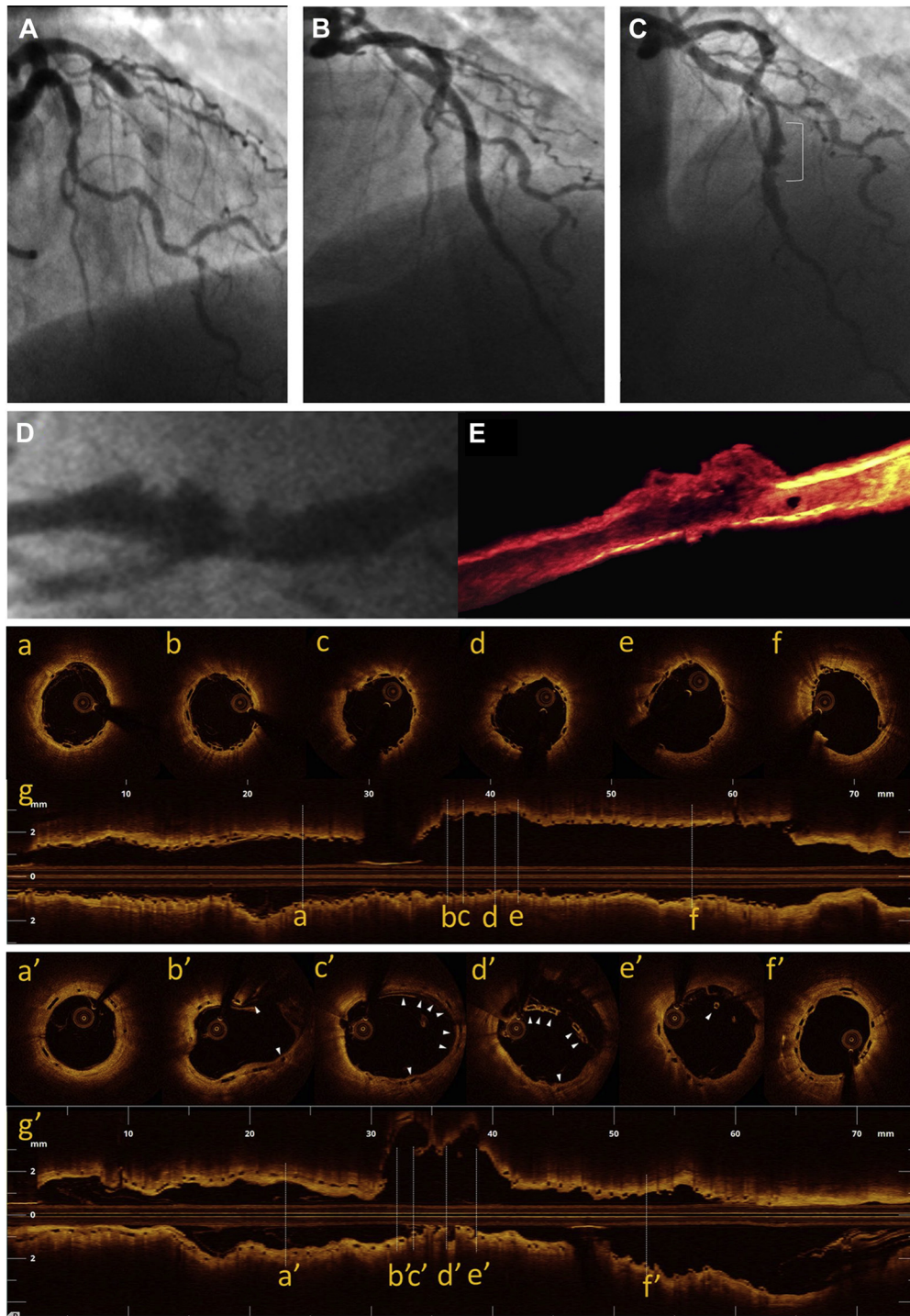
Giuseppe Gargiulo, MD,* Andrea Mangiameli, MD,* Francesco Granata, MD,* Yohei Ohno, MD,* Alberto Chisari, MD,* Davide Capodanno, MD, PhD,*† Corrado Tamburino, MD, PhD,*† Alessio La Manna, MD*

A 60-year-old man with a chronic total occlusion of the left anterior descending coronary artery (LAD) (Figure 1A) and evidence of myocardium viability was successfully treated with percutaneous coronary intervention. Four overlapping bioresorbable vascular scaffolds (BVS; Abbott Vascular, Santa Clara, California) were implanted: 2.5 × 28 mm, 3.0 × 28 mm, 3.5 × 28 mm, and 3.5 × 28 mm from distal to proximal, respectively (“full polymer jacket”) (Figure 1B) (1). Optical coherence tomography (OCT; Ilumien, St. Jude Medical, St. Paul, Minnesota) showed good expansion of the scaffolds and good apposition of the struts (Figures 1a to 1g). At 8 months, elective angiographic follow-up documented a focal coronary artery aneurysm (CAA) at the mid-segment of the LAD (Figure 1C) (2). OCT revealed a CAA maximal lumen area of 16.4 mm² with a longitudinal length of 8.4 mm in the absence of thrombus. At the CAA site, most of the BVS struts were embedded in the aneurysmal wall and covered by neointima, whereas late-acquired incomplete

scaffold apposition (ISA) was noted in some cross sections (Figures 1a' to 1g'). To our knowledge, this is the first described case of new-onset CAA and late-acquired ISA after BVS implantation. Potential mechanisms of late-acquired ISA after chronic total occlusion percutaneous coronary intervention include guidewire injury to the adventitial layer, creation of a false lumen, or subintimal stenting (3). With BVS, the management is uncertain, not automatically resembling that of CAA developed after metallic stenting (2). The potential consequences of balloon angioplasty or stent implantation inside a BVS that has lost its integrity as a result of the bioresorption process are unknown. A “watchful waiting” strategy with long-term dual antiplatelet therapy and early follow-up was adopted.

REPRINT REQUESTS AND CORRESPONDENCE: Dr. Davide Capodanno, University of Catania, Cardiovascular Department, Ferrarotto Hospital, via Citelli 1, 95124 Catania, Italy. E-mail: dcapodanno@gmail.com.

From the *Division of Cardiology, Ferrarotto Hospital, University of Catania, Italy; and the †Excellence Through Newest Advances (ETNA) Foundation, Catania, Italy. The authors have reported that they have no relationships relevant to the contents of this paper to disclose.

FIGURE 1 Coronary Angiography and Optical Coherence Tomography Findings

(A) Angiogram with chronic total occlusion of proximal left anterior descending coronary artery (LAD). **(B)** LAD angiogram after “full polymer jacket” with bioresorbable vascular scaffolds (BVS). **(C)** LAD angiogram at 8-month revealing a coronary artery aneurysm (CAA) at the mid-segment (**white bracket**). **(D)** Magnification of CAA at angiography. **(E)** Magnification of CAA at optical coherence tomography (OCT) 3-dimensional reconstruction. **(a-g)** OCT cross sections and longitudinal view after the index procedure show good expansion and apposition of the scaffold struts. **(a'-f')** Corresponding cross sections at 8-month angiographic follow-up showing normal vessel with good scaffold apposition (**a' and f'**), CAA with scaffold struts (**white arrowheads**) embedded in the aneurysmal vessel wall (**b' and c'**), and late ISA with BVS struts (**white arrowheads**) floating in the lumen vessel (**d' and e'**). The luminal surface of CAA is homogenous with no evidence of thrombus. **(g')** Longitudinal view of the CAA.

REFERENCES

1. La Manna A, Ohno Y, Attizzani GF, Tamburino C. Successful retrograde recanalization of chronic total coronary occlusion with multiple bioresorbable vascular scaffolds ('full polymer jacket'): initial experience and rationale. *Eur Heart J* 2013;34:2925.
2. Aoki J, Kirtane A, Leon MB, Dangas G. Coronary artery aneurysms after drug-eluting stent implantation. *J Am Coll Cardiol Intv* 2008;1:14-21.
3. Attizzani GF, Capodanno D, Ohno Y, Tamburino C. Mechanisms, pathophysiology, and clinical aspects of incomplete stent apposition. *J Am Coll Cardiol* 2014;63:1355-67.

KEY WORDS bioresorbable vascular scaffolds, chronic total occlusion, late-acquired incomplete scaffold apposition