

Acquired Immune Resistance Follows Complete Tumor Regression without Loss of Target Antigens or IFN γ Signaling



Marco Donia^{1,2}, Katja Harbst³, Marit van Buuren⁴, Pia Kvistborg⁴, Mattias F. Lindberg⁵, Rikke Andersen^{1,2}, Manja Idorn¹, Shamaila Munir Ahmad¹, Eva Ellebæk^{1,2}, Anja Mueller⁶, Paolo Fagone⁷, Ferdinando Nicoletti⁷, Massimo Libra⁷, Martin Lauss³, Sine Reker Hadrup¹, Henrik Schmidt⁸, Mads Hald Andersen¹, Per thor Straten¹, Jonas A. Nilsson⁴, Ton N. Schumacher⁵, Barbara Seliger⁶, Göran Jönsson³, and Inge Marie Svane^{1,2}

Abstract

Cancer immunotherapy can result in durable tumor regressions in some patients. However, patients who initially respond often experience tumor progression. Here, we report mechanistic evidence of tumoral immune escape in an exemplary clinical case: a patient with metastatic melanoma who developed disease recurrence following an initial, unequivocal radiologic complete regression after T-cell–based immunotherapy. Functional cytotoxic T-cell responses, including responses to one mutant neoantigen, were amplified effectively with therapy and generated durable immunologic memory. However, these immune responses, including apparently effective surveillance of the tumor mutanome, did not prevent recur-

rence. Alterations of the MHC class I antigen-processing and presentation machinery (APM) in resistant cancer cells, but not antigen loss or impaired IFN γ signaling, led to impaired recognition by tumor-specific CD8⁺ T cells. Our results suggest that future immunotherapy combinations should take into account targeting cancer cells with intact and impaired MHC class I–related APM. Loss of target antigens or impaired IFN γ signaling does not appear to be mandatory for tumor relapse after a complete radiologic regression. Personalized studies to uncover mechanisms leading to disease recurrence within each individual patient are warranted. *Cancer Res*; 77(17); 4562–6. ©2017 AACR.

Introduction

Immunotherapy of cancer frequently results in durable clinical responses. However, a significant fraction of patients who initially respond will experience renewed tumor progression. So far, it is reported that about 30% of patients respond-

ing to checkpoint inhibitors (1, 2) and about 60% of patients responding to cellular immunotherapy with tumor-infiltrating lymphocytes (TIL; ref. 3) will experience disease progression, respectively, within 2 years and within 5 years. With increasing availability of immunotherapies, disease progression after initial clinical response or treatment-induced immune resistance is rapidly emerging as a major hurdle in oncology practice (4).

It is generally believed that processes leading to acquired immune resistance would practically overlap to mechanisms involved in naturally acquired resistance during primary immunoeediting (5). Current knowledge on disease progression after initial response to immunotherapy is derived from comprehensive animal models, or clinical anecdotes that associate certain disease features to renewed disease progression (4). In a recent publication, Verdegaaal and colleagues (6) elegantly show how immunogenic neoantigens can be lost or down-regulated during tumor progression. In this study, the authors used multiple samples from two patients with melanoma, including one patient treated with adoptive cellular therapy before collection of a progressing lesion. However, none of the samples analyzed was obtained after a true immune-mediated tumor regression, but rather during the natural progression of human melanoma or very short disease stabilization following T-cell–based immunotherapy. Therefore, the relevance of these findings may be limited to the situation of prolonged immunologic interactions of tumors with the adaptive immune system, in the absence of elimination of large tumor masses. In another study, Zhao and colleagues (7) described the case of

¹Department of Hematology, Center for Cancer Immune Therapy, Copenhagen University Hospital, Herlev, Denmark. ²Department of Oncology, Copenhagen University Hospital, Herlev, Denmark. ³Division of Oncology and Pathology, Department of Clinical Sciences Lund, Faculty of Medicine, Lund University, Sweden. ⁴Division of Immunology, The Netherlands Cancer Institute, Amsterdam, the Netherlands. ⁵Sahlgrenska Cancer Center, University of Gothenburg, Gothenburg, Sweden. ⁶Institute for Medical Immunology, Martin Luther University, Halle-Wittenberg, Germany. ⁷Department of Bio-medical Sciences, University of Catania, Catania, Italy. ⁸Department of Oncology, Aarhus University Hospital, Aarhus, Denmark.

Note: Supplementary data for this article are available at Cancer Research Online (<http://cancerres.aacrjournals.org/>).

Current address for M. van Buuren: Neon Therapeutics, Cambridge, MA; and current address for S.R. Hadrup, Section for Immunology and Vaccinology, National Veterinary Institute, Technical University of Denmark, Copenhagen, Denmark.

Corresponding Authors: Marco Donia, Herlev Hospital, University of Copenhagen, Herlev Ringvej 75, 2730 Herlev, Denmark. Phone: 45-38681456; E-mail: marco.donia@regionh.dk; and Inge Marie Svane, inge.marie.svane@regionh.dk

doi: 10.1158/0008-5472.CAN-16-3172

©2017 American Association for Cancer Research.

a patient with metastatic melanoma and multiple recurrent lesions, where poorly immunogenic melanoma phenotypes evolve toward T-cell resistance by independent genetic events, leading to MHC class I loss/deficiency. Again, this patient was treated with various forms of immunotherapy but did not appear to experience a clear immune-mediated tumor regression. In contrast, novel cancer immunotherapies frequently induce tumor regressions developing in few weeks to few months but, however, in a significant fraction of patients this initial clinical response does not last. Zaretsky and colleagues (8) described four patient cases who progressed while receiving anti-PD-1 immunotherapy, after an initial partial tumor regression. They identified defective IFN γ signaling and inactivation of β 2 microglobulin as mechanisms of acquired resistance to immunotherapy.

Here, we present mechanistic evidence of clinical tumor immune escape in an exemplary clinical case of a patient with metastatic melanoma, who developed disease recurrence following an unequivocal initial radiologic complete tumor regression to cellular immunotherapy with autologous TILs. Given the nature of this treatment, the infusion product, which induced tumor regression, could be studied in detail with antigen-specific assays and tests of direct tumor recognition and killing. Disease recurrence was not associated with cancer cells that lost target antigens or had impaired IFN γ signaling, but with cancer cells with defective MHC class I antigen-processing and presentation machinery (APM).

Materials and Methods

Patient treatment and clinical specimens

All the procedures were approved by the Scientific Ethics Committee for the Capital Region of Denmark. Written informed consent was obtained from the patient according to the Declaration of Helsinki. HLA class I genotyping of a normal cell sample was performed by the Rigshospitalet (Copenhagen, Denmark) HLA typing service, and confirmed with whole-exome sequencing as A*01:01, A*03:01, B*15:01, B*40:01, C*03:04 (homozygous). The patient MM909.11 was treated in the context of the clinical trial NCT00937625, and TILs were prepared accordingly as described in ref. 9. Melanoma cell lines were established as described in ref. 10 at the Center for Cancer Immune Therapy, Herlev Hospital, Denmark.

TILs were established according to standard methods, as described by Ellebæk and colleagues (9). Briefly, TILs were initially isolated and minimally expanded (mTILs, as in; ref. 10) from tumor fragments in standard complete medium supplemented with IL2 (6,000 IU/mL IL2, Proleukin, Novartis) and subsequently were massively expanded according to the Rapid Expansion Protocol (REP). PBMCs were isolated from a blood sample with gradient centrifugation, and stored according to local standard operating procedures. All melanoma cell lines, were generated by serial passage of adherent cells released from tumor fragments and cultured in RPMI1640 (Life Technologies) supplemented with 10% FCS (Life Technologies), as described previously (11).

The time points for collection of tumor samples (used for generation of TILs and melanoma cell lines) and PBMCs are indicated in Fig. 1A. Briefly, tumor #1 was resected in February 2011, and both TIL#1 and Mel#1 were established from this sample; TIL#1 were infused in July 2011, and this treatment

resulted in a complete response according to RECIST 1.0; PBMCs were collected at serial time points; tumor #2, first identified with a PET/CT scan in August 2012 was resected in September 2012, and both TIL#2 and Mel#2 were established from this sample.

Analysis of T-cell responses

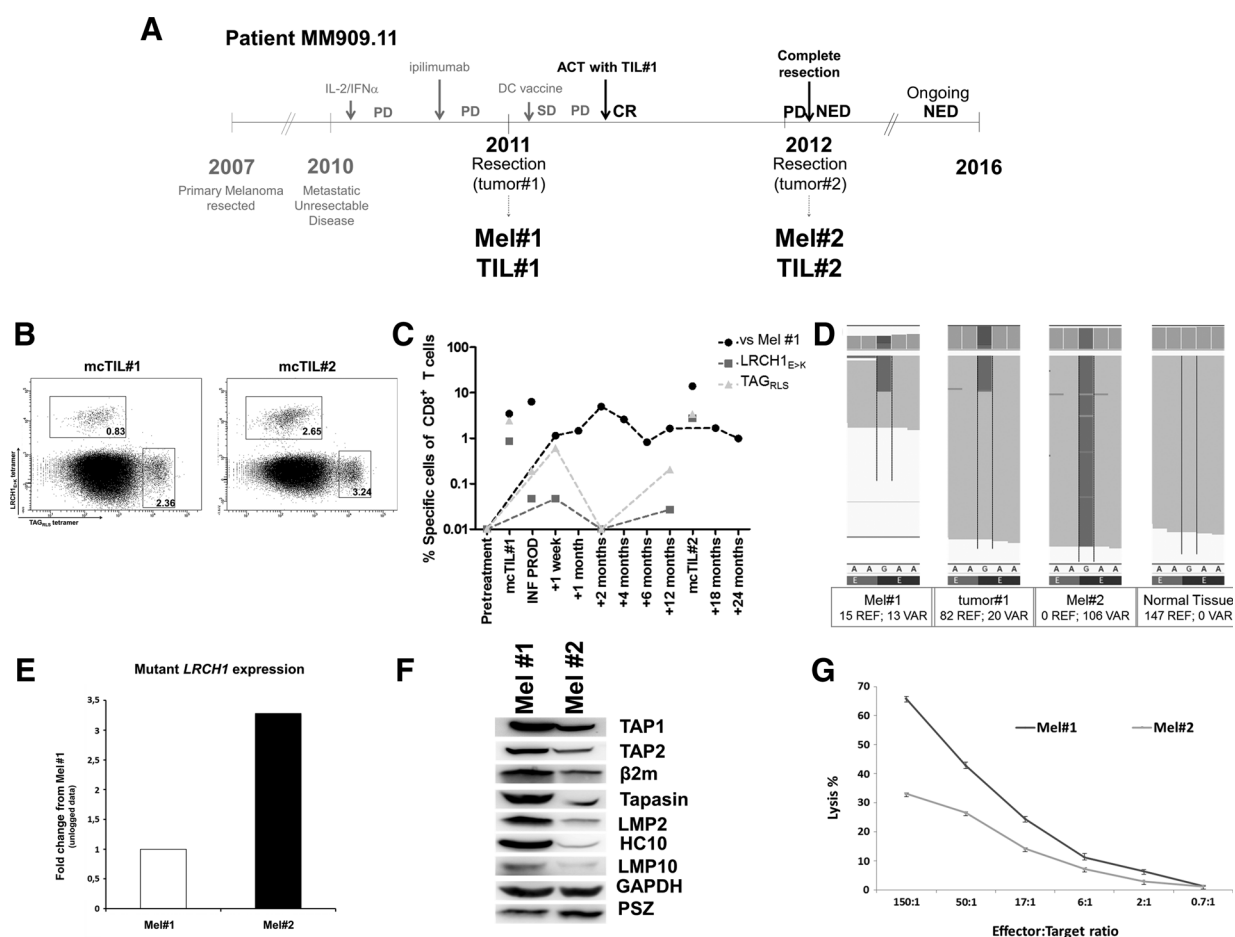
All peptides were obtained from the NKI peptide synthesis facility (Amsterdam, the Netherlands) or Pepsan (Lelystad, the Netherlands). Combinatorial encoding with peptide(p)-MHC multimers was carried out with TIL#1 and TIL#2 to identify T-cell-specific for shared antigens, as described in ref. 12. One initial screening to detect CD8⁺ T cells in TIL#1 recognizing mutant antigens for the patient specific HLA alleles of Mel#1 was carried out as described in Supplementary Methods and previously used in ref. 13. Additional focused screenings to identify whether mutant antigens privately expressed in Mel#1 were recognized was conducted by stimulating TIL#1 and TIL#2 with short peptides (8–11 mers) in overnight IFN γ ELISPOT assays. ELISPOT were carried out as previously described (10), using 23 additional potential private neoepitopes of Mel#1, identified as described below (9 other private neo-epitopes were already tested in the primary screening, and thus were not analyzed). Prediction of neoepitopes is described in the Supplementary File. Positive responses were confirmed with intracellular staining of TNF and IFN γ after stimulation of TIL#1 or TIL#2 (criteria for evaluation of positive responses were as in; ref. 11). Responses were observed to the peptides RLSNRLLLR (TAG_{RLS}, HLA-A3, >2% of CD8⁺ T cells in TIL#2) and three of four tested peptides derived from the LRCH1 p.E672K mutation (CLPHHILEKK, HLA-A*03:01, >2% of CD8⁺ T cells in TIL#2; KLCLPHHILEK, HLA-A*03:01, >2% of CD8⁺ T cells in TIL#2; LEKKGLVKVGI, HLA-B*40:01, >0.05% of CD8⁺ T cells in TIL#2). Because the highest responses were detected after stimulation with the mutant CLPHHILEKK peptide (data not shown), all additional experiments with recognition of the LRCH1_{E>K} mutation were carried out with this reagent. Responses to peptides RLSNRLLLR (TAG-derived) and CLPHHILEKK (LRCH1_{E>K}-derived; wild type peptide CLPHHILEEK) were confirmed with >90% pure peptides in intracellular staining experiments, assessing T cells coexpressing TNF and IFN γ . T-cell cultures with high specificity for defined antigens (>95% specific, confirmed with p-MHC multimer staining, data not shown) were obtained by sorting relevant CD8⁺ T cells within minimally expanded TILs with tetramers conjugated with two different colors, and then performing two sequential REP (14) of 8–10 + 7–9 days. Standard REP media were supplemented with 2 ng/mL of IL15 (PeproTech).

In all other cases, evaluation of T-cell responses was performed as described previously (11) with tumor reactivity evaluated by assessing the amount of CD8⁺ T cells coexpressing TNF and IFN γ . FACS antibodies were obtained from BD Biosciences, unless indicated otherwise. Where indicated, tumor cells were pretreated with 100 IU/mL of recombinant human IFN γ (PeproTech) for 72 hours. The chromium-51 cytotoxicity assay was performed as previously described (15).

Gene and protein expression of tumor cells

Analysis of mRNA and proteins (Western blot analysis) on selected APM components and putative target antigens were

Donia et al.

**Figure 1.**

T-cell immune recognition and immune resistance of melanoma in patient MM909.11. **A**, Clinical course, tissue collection with TILs, and tumor cell line generation. CR, complete response; PD, progressive disease; SD, stable disease; NED, no evidence of disease. **B**, Staining with LRCH1_{E>K} and TAG_{RLS} p-MHC multimers of minimally cultured TIL#1 and TIL#2 detects specific T cells in both TILs (plots are gated on live CD8⁺ T cells). One representative experiment is shown. **C**, The frequency of CD8⁺ T cells recognizing Mel#1 (simultaneous production of TNF and IFN γ after coculture), or that binds LRCH1_{E>K} or TAG_{RLS} fluorochrome-conjugated is shown in the graph. The percentage of tumor-antigen-specific CD8⁺ T cells increases from undetectable before infusion of TILs to detectable variable levels. Tumor antigen-specific CD8⁺ T cells are still detectable in the blood at the time of recurrence (around 12 months after primary immunotherapy) and in mcTIL#2, indicating ability to infiltrate the recurrent tumor. **D**, Identification of LRCH1 p.E672K mutation by whole-exome sequencing. In light gray, nucleotide positions correspond to the reference sequence. Mutations are displayed in dark gray. Collapsed sequencing reads are displayed. The mutation is present in a fraction of reads in Mel#1 and respective tumor sample (tumor#1), whereas in Mel#2 it occupies 100% of reads. The mutation is truly somatic as it is absent from the matched normal tissue. **E**, Fold change in mutant RNA expression of LRCH1 in Mel#2 relative to Mel#1 showing increased expression of LRCH1 in Mel#2. **F**, Multiple deficiencies in protein expression of selected components of the class I APM of Mel#2, compared with Mel#1. **G**, Chromium-51 release assay of Mel#1 or Mel#2 after coincubation with TIL#1 at different effector:target ratios. The graph shows reduced sensitivity of Mel#2.

performed as recently described (16). Briefly, for mRNA analysis the cDNA was synthesized using the Revert Aid H Minus First Strand cDNA Synthesis Kit (Fermentas) before qPCR was performed with APM-specific primers using the Platinum SYBR Green qPCR SuperMix-UDG (Invitrogen) for 40 cycles, 95°C, 15 s, 60°C, 30s. Relative mRNA levels for specific APM components were normalized to β -actin. For protein analysis by Western blot analysis, 30 μ g of protein/lane was separated on SDS-PAGE, transferred onto nitrocellulose filters and subsequently stained with APM component-specific mAbs. The staining was detected with horseradish peroxidase (HRP)-conjugated secondary antibodies (Dako). The membranes were washed and protein bands were visualized with a Lumilite

(Roche Diagnostics) and exposed to a CCD camera (Eastman Kodak).

Results and Discussion

The initial complete response following infusion of autologous TILs generated from an initially resected tumor metastases (TIL#1 and tumor#1) is reported in Ellebaek and colleagues (9). Recurrent metastatic disease (tumor#2) was diagnosed about 1 year after primary treatment (summary of the clinical history is shown in Fig. 1A).

CD8⁺ T cells recognizing one neoantigen derived from the mutation LRCH1 p.E672K (LRCH1_{E>K}) and the cancer-testis

antigen (epitope TAG_{RLS}; Fig. 1B, left) were identified in minimally cultured (mc) TIL#1. About 6% of CD8⁺ T cells in the infusion product, derived from TIL#1, recognized the unedited melanoma (Mel#1) *in vitro*, including T cells recognizing LRCH1_{E>K} and TAG_{RLS}, which alone corresponded to up to about 60% of the total tumor reactivity of peripheral CD8⁺ T cells one week after infusion (Fig. 1C). Therapy-induced tumor-reactive/specific CD8⁺ T cells detected peripherally persisted beyond tumor regrowth (Fig. 1C). mcTIL#2, isolated from the recurrent tumors (tumor#2, from which the cell line Mel#2 was generated), contained at least comparable frequencies of tumor-reactive/specific T cells, including 3-fold higher percentages of CD8⁺ T cells recognizing LRCH1_{E>K} (Fig. 1B and C). In mcTIL#2, CD8⁺ T cells recognizing TAG_{RLS} or LRCH1_{E>K} did not express higher levels of coinhibitory molecules such as PD-1, LAG-3, or TIM-3 (Supplementary Fig. S1A and S1B). Thus, tumor regrowth occurred despite effective induction of a primary complete response, continuous T-cell persistence and effective infiltration of the recurrent edited tumor.

Over 80% of nonsynonymous and synonymous mutations detected were identical in tumor#1, Mel#1, and Mel#2 (Supplementary Table S1), including the LRCH1_{E>K} mutation (Fig. 1D). However, while tumor#1 and Mel#1 expressed both the mutant and wild-type alleles, Mel#2 only harbored (DNA, Fig. 1D) and expressed (RNA, data not shown) the mutant allele, and at a slightly higher level as compared with Mel#1 (Fig. 1E). No dramatic reduced expression of the other known target antigen TAG (Supplementary Fig. S2A) as well as additional putative target antigens, such as common melanocyte differentiation antigens and cancer-testis antigens with the exception of MAGE-4 (Supplementary Fig. S2B), were found. However, it is important to highlight that no responses to other putative antigens were detected with the screening methods used (see Materials and Methods/analysis of T-cell responses). Although Mel#1 harbored multiple putative neoantigens that were absent in Mel#2, further focused screening efforts did neither identify CD8⁺ T cells in TIL#1 and TIL#2 recognizing these candidate neoantigens (data not shown). No increased expression of the immunosuppressive PD-L1 was observed in Mel#2 (Supplementary Fig. S2C).

Importantly, Mel#2 displayed multiple newly emerged defects in the MHC class I APM (Fig. 1F for protein and Supplementary Fig. S2D for mRNA in qPCR), resulting in reduced surface expression of MHC class I antigens (HLA-ABC, Supplementary Fig. S2E). IFN γ could induce overexpression of the major APM components and other IFN γ -inducible molecules, demonstrating that Mel#2 maintained sensitivity to IFN γ (Supplementary Fig. S2D–S2F). Loss of heterozygosity (LOH) in chromosome 6 (HLA genes) and/or chromosome 15 (β 2Microglobulin-B2M) were previously associated with immune resistance of relapsed melanoma lesions and impaired MHC class I APM (17). Here, both Mel#1 and Mel#2 had a LOH at HLA-A and HLA-B locus, that is, LOH of MHC I alleles was already present before treatment (Supplementary Fig. S3A and S3B). Thus, LOH in chromosome 6 happening at early stages of tumor development affected antigen presentation equally in Mel#1 and Mel#2.

Gene expression of HLA-B and HLA-C were strongly down-regulated in Mel#2 (Supplementary Fig. S3C), whereas only minor changes of HLA-A (Supplementary Fig. S3C) and B2M (Supplementary Figs. S2D and S3C) were found. Because B2M

protein is an essential part of the MHC complex, the decrease in the B2M protein level observed in Mel#2 (Fig. 1F) may be related to the strongly impaired expression of HLA-B and C. Chromosome 15, where B2M is located, shows no evidence of LOH in both Mel#1 and Mel#2 (Supplementary Fig. S3D). Overall, a specific genetic or epigenetic event to explain the observed immunoresistant phenotype could not be identified either at DNA (Supplementary Table S1) or RNA (Supplementary Fig. S4) level.

In parallel, recognition of Mel#2 by unselected TILs (Supplementary Fig. S5A and S5B for cytokine production; TIL#1 in Fig. 1G for killing), CD8⁺ PBMCs obtained at time of recurrence (Supplementary Fig. S5C) or at other later time points (+15 months or +18 months, data not shown), and TAG_{RLS}-specific CD8⁺ T cells (Supplementary Fig. S5D) were significantly reduced, which could be partially rescued by preexposure of tumor cells to IFN γ (Supplementary Fig. S5B and S5D). In contrast, recognition of Mel#2 by CD8⁺ T cells reactive to LRCH1_{E>K} was increased in Mel#2 and further upregulated with IFN γ (Supplementary Fig. S5E), in parallel to increased expression of the LRCH1_{E>K} mutation in Mel#2 (Fig. 1E).

On a different note, Mel#2 displayed different morphology with only spindle cells, in contrast to a biphasic population comprising of spindle and epithelioid cells in Mel#1, and accelerated growth compared with Mel#1 both *in vitro* (estimated doubling time ~35 vs. 68 hours; 35% vs. 10% Ki-67⁺) and *in vivo* (tumor size of 50 mm² reached in less than 30 vs. over 70 days, Supplementary Fig. S2F). These immune-independent changes in the biology of tumor cells may have contributed to tip of the balance from tumor elimination/dormancy to radiologically evident tumor growth.

Despite obvious limitations of a single case in which a mechanistic explanation for the observed impaired MHC class I APM could not be identified, we report one instructive clinical example offering insight into the mechanisms driving disease recurrence after radiologic complete regression following cellular immunotherapy of cancer. Radiologic complete regression may leave behind microscopic cancer cell aggregates. Thus, immunologic pressure may promote the outgrowth of immunoresistant tumor cells with MHC class I APM deficiencies that can drive tumor recurrence even with apparently effective surveillance of the tumor mutanome and in the absence of antigen loss or defective IFN γ signaling. Loss of target antigens may be not essential in acquired resistance to cancer immunotherapies inducing rapid complete regression of large tumor masses with multitarget T-cell responses, as tumor cells should lose several target antigens at once for an efficient immune escape.

MHC class I APM-deficient tumors can be hardly targeted effectively by immunotherapies stimulating CD8⁺ T-cell responses (18). Impaired MHC class I APM may represent a universal mechanism of resistance to CD8⁺ T-cell responses targeting any tumor antigen (19), and a dichotomy with higher MHC class I APM expression in regressing compared with progressing metastases was observed in other studies as well (20). To prevent or treat tumor recurrences with acquired MHC class I APM deficiency, we suggest that alternative strategies such as restoring APM via targeted-delivery of APM-inducers, or non-T-cell-based immune strategies should be tested. In sum, these data together with recent works by Zaretsky and colleagues (8) highlight the need of comprehensive studies of the immunologic interactions within the

Donia et al.

individual patient to uncover molecular mechanisms leading to acquired resistance to cancer immunotherapy on a personalized basis.

Disclosure of Potential Conflicts of Interest

P. Kvistborg is a consultant/advisory board member for Personalis and Neon Therapeutics. H. Schmidt is a consultant/advisory board for BMS, Novartis, and Merck. No potential conflicts of interest were disclosed by the other authors.

Authors' Contributions

Conception and design: M. Donia, P.T. Straten, I.M. Svane

Development of methodology: M. Donia, P. Kvistborg, S.R. Hadrup, J.A. Nilsson

Acquisition of data (provided animals, acquired and managed patients, provided facilities, etc.): M. Donia, K. Harbst, M.V. Buuren, M.F. Lindberg, R. Andersen, M. Idorn, S. Munir, E. Ellebæk, A. Mueller, S.R. Hadrup, H. Schmidt, T.N. Schumacher, B. Seliger, G. Jönsson

Analysis and interpretation of data (e.g., statistical analysis, biostatistics, computational analysis): M. Donia, K. Harbst, M.V. Buuren, M.F. Lindberg,

R. Andersen, M. Idorn, A. Mueller, M. Lauss, S.R. Hadrup, B. Seliger, G. Jönsson

Writing, review, and/or revision of the manuscript: M. Donia, K. Harbst, M.V. Buuren, P. Kvistborg, M.F. Lindberg, R. Andersen, M. Idorn, E. Ellebæk, P. Fagone, F. Nicoletti, M. Libra, M. Lauss, H. Schmidt, B. Seliger, G. Jönsson, I.M. Svane

Administrative, technical, or material support (i.e., reporting or organizing data, constructing databases): M. Donia, R. Andersen, P. Fagone, M.H. Andersen, I.M. Svane

Study supervision: M. Donia, J.A. Nilsson, I.M. Svane

Grant Support

This study was supported by grants from The Danish Cancer Society, Herlev Hospital Research Council, Aase and Einar Danielsen Foundation, Beckett Foundation (grant 36173/36228), Deutsche Krebshilfe (grant 110703 and 111091), and Fondazione Italiana per la Ricerca sul Cancro (grant 13732)

Received November 25, 2016; revised April 8, 2017; accepted June 22, 2017; published OnlineFirst June 27, 2017.

References

- Ribas A, Hamid O, Daud A, Hodi FS, Wolchok JD, Kefford R, et al. Association of pembrolizumab with tumor response and survival among patients with advanced melanoma. *JAMA* 2016;315:1600.
- Schachter J, Ribas A, Long G V, Arance A, Grob J-J, Mortier L, et al. Pembrolizumab versus ipilimumab for advanced melanoma: final overall survival analysis of KEYNOTE-006. *J Clin Oncol* 34:15s, 2016 (suppl; abstr 9504).
- Rosenberg S, Yang JC, Sherry RM, Kammula US, Hughes MS, Phan GQ, et al. Durable complete responses in heavily pretreated patients with metastatic melanoma using T-cell transfer immunotherapy. *Clin Cancer Res* 2011;17:4550-7.
- Restifo NP, Smyth MJ, Snyder A. Acquired resistance to immunotherapy and future challenges. *Nat Rev Cancer* 2016;16:121-6.
- Kelderman S, Schumacher TNM, Haanen JB a G. Acquired and intrinsic resistance in cancer immunotherapy. *Mol Oncol* 2014;8:1132-9.
- Verdegaal EME, de Miranda NFCC, Visser M, Harryvan T, van Buuren MM, Andersen RS, et al. Neoantigen landscape dynamics during human melanoma-T-cell interactions. *Nature* 2016;536:91-5.
- Zhao F, Sucker A, Horn S, Heeke C, Bielefeld N, Schrörs B, et al. Melanoma lesions independently acquire t-cell resistance during metastatic latency. *Cancer Res* 2016;76:4347-58.
- Zaretsky JM, Garcia-Diaz A, Shin DS, Escuin-Ordinas H, Hugo W, Hu-Lieskovan S, et al. Mutations associated with acquired resistance to PD-1 blockade in melanoma. *N Engl J Med* 2016;375:819-29.
- Ellebaek E, Iversen TZ, Junker N, Donia M, Engell-Noerregaard L, Met O, et al. Adoptive cell therapy with autologous tumor infiltrating lymphocytes and low-dose Interleukin-2 in metastatic melanoma patients. *J Transl Med* 2012;10:169.
- Donia M, Andersen R, Kjeldsen JW, Fagone P, Munir S, Nicoletti F, et al. Aberrant expression of MHC Class II in melanoma attracts inflammatory tumor specific CD4⁺ T cells which dampen CD8⁺ T cell antitumor reactivity. *Cancer Res* 2015;75:3747-59.
- Donia M, Hansen M, Sendrup SL, Iversen TZ, Ellebæk E, Andersen MH, et al. Methods to improve adoptive T-cell therapy for melanoma: IFN-γ enhances anticancer responses of cell products for infusion. *J Invest Dermatol* 2013;133:545-52.
- Andersen RS, Thruue CA, Junker N, Lyngaa R, Donia M, Ellebæk E, et al. Dissection of T-cell antigen specificity in human melanoma. *Cancer Res* 2012;72:1642-50.
- van Rooij N, van Buuren MM, Philips D, Velds A, Toebes M, Heemskerck B, et al. Tumor exome analysis reveals neoantigen-specific T-cell reactivity in an ipilimumab-responsive melanoma. *J Clin Oncol* 2013;31:e439-42.
- Donia M, Junker N, Ellebaek E, Andersen MH, Straten PT, Svane IM. Characterization and comparison of "Standard" and "Young" tumor infiltrating lymphocytes for adoptive cell therapy at a danish translational research institution. *Scand J Immunol* 2011;75:157-67.
- Junker N, Thor Straten P, Andersen MH, Svane IM. Characterization of ex vivo expanded tumor infiltrating lymphocytes from patients with malignant melanoma for clinical application. *J Skin Cancer* 2011;2011:574695.
- Respa A, Bukur J, Ferrone S, Pawelec G, Zhao Y, Wang E, et al. Association of IFN-gamma signal transduction defects with impaired HLA class I antigen processing in melanoma cell lines. *Clin Cancer Res* 2011;17:2668-78.
- Del Campo AB, Kyte JA, Carretero J, Zinchenko S, Méndez R, González-Aseguinolaza G, et al. Immune escape of cancer cells with beta2-microglobulin loss over the course of metastatic melanoma. *Int J Cancer* 2014;134:102-13.
- Thor Straten P, Garrido F. Targetless T cells in cancer immunotherapy. *J Immunother Cancer* 2016;4:23.
- Garrido F, Algarra I, García-lora AM. The escape of cancer from T lymphocytes: immunoselection of MHC class I loss variants harboring structural-irreversible "hard" lesions *Cancer Immunol Immunother* 2010;59:1601-6.
- Carretero R, Wang E, Rodriguez AI, Reinboth J, Ascierto ML, Engle AM, et al. Regression of melanoma metastases after immunotherapy is associated with activation of antigen presentation and interferon-mediated rejection genes. *Int J Cancer* 2012;131:387-95.

Cancer Research

The Journal of Cancer Research (1916–1930) | The American Journal of Cancer (1931–1940)

Acquired Immune Resistance Follows Complete Tumor Regression without Loss of Target Antigens or IFN γ Signaling

Marco Donia, Katja Harbst, Marit van Buuren, et al.

Cancer Res 2017;77:4562-4566. Published OnlineFirst June 27, 2017.

Updated version Access the most recent version of this article at:
doi:[10.1158/0008-5472.CAN-16-3172](https://doi.org/10.1158/0008-5472.CAN-16-3172)

Supplementary Material Access the most recent supplemental material at:
<http://cancerres.aacrjournals.org/content/suppl/2017/06/27/0008-5472.CAN-16-3172.DC1>

Cited articles This article cites 19 articles, 6 of which you can access for free at:
<http://cancerres.aacrjournals.org/content/77/17/4562.full#ref-list-1>

Citing articles This article has been cited by 3 HighWire-hosted articles. Access the articles at:
<http://cancerres.aacrjournals.org/content/77/17/4562.full#related-urls>

E-mail alerts [Sign up to receive free email-alerts](#) related to this article or journal.

Reprints and Subscriptions To order reprints of this article or to subscribe to the journal, contact the AACR Publications Department at pubs@aacr.org.

Permissions To request permission to re-use all or part of this article, use this link
<http://cancerres.aacrjournals.org/content/77/17/4562>.
Click on "Request Permissions" which will take you to the Copyright Clearance Center's (CCC) Rightslink site.