

Cite this article as: Migliore M, Borrata F, Monaco E, Criscione A. Massive relaxation of the diaphragm. Eur J Cardiothorac Surg 2017;52:827.

Massive relaxation of the diaphragm

Marcello Migliore*, Francesco Borrata, Enrica Monaco and Alessandra Criscione

Section of Thoracic Surgery, Department of Surgery and Medical Specialties, Policlinico University Hospital, University of Catania, Catania, Italy

* Corresponding author. Section of Thoracic Surgery, Department of Surgery and Medical Specialties, Policlinico University Hospital, University of Catania, Via S. Sofia 78, 95124 Catania, Italy. Tel: +39-095-3781467; fax: +39-095-3781467; e-mail: mmiglior@unicat.it (M. Migliore).

Received 10 March 2017; accepted 12 May 2017

Keywords: Relaxation • Diaphragm • Event ratio • Hiatal hernia

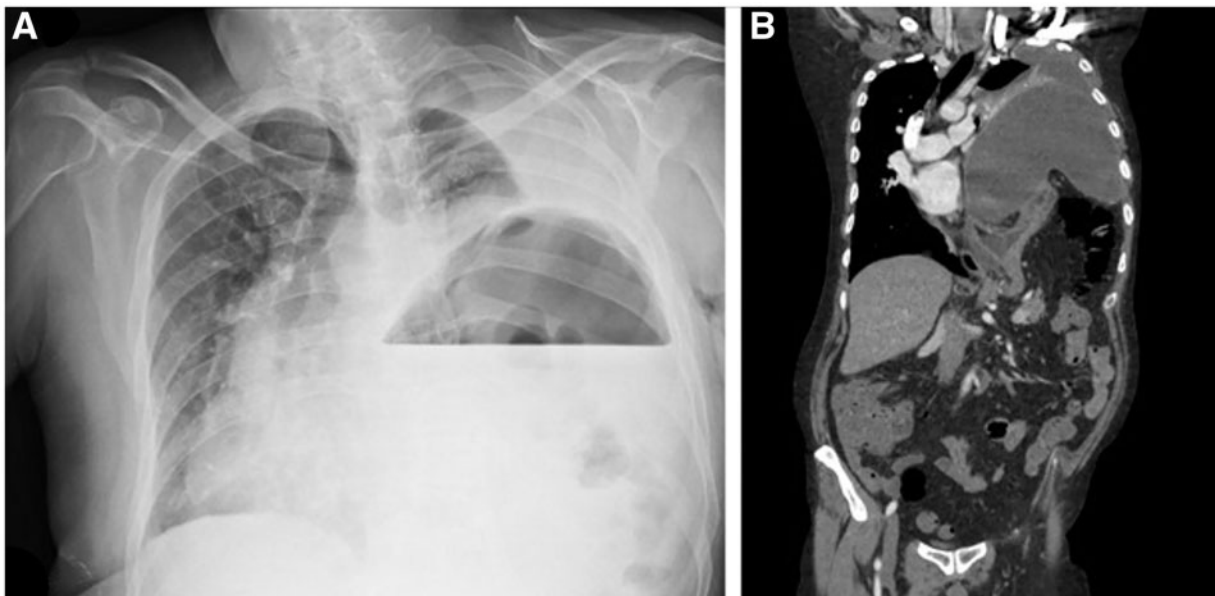


Figure 1: Preoperative images. X-rays showed a possible diagnosis of intrathoracic stomach in a 53-year-old man with dystonia, dysphagia and dyspnoea (Fig. 1A). Computed tomography scan demonstrated a large relaxation of the left diaphragm with the lung reduced to a small fist (Fig. 1B). A left thoracotomy was performed. A patch was used to reinforce the diaphragm. The patient is well at 2-year follow-up.