

Screening, diagnosis and management of human cysticercosis and *Taenia solium* taeniasis: technical recommendations by the COHEMI project study group

Lorenzo Zammarchi^{1,2}, Maurizio Bonati³, Marianne Strohmeyer¹, Marco Albonico⁴, Ana Requena-Méndez⁵, Zeno Bisoffi⁴, Alessandra Nicoletti⁶, Hector H. García⁷, and Alessandro Bartoloni^{1,2} The COHEMI Project Study Group^a

1 *Unità di Malattie Infettive, Università Degli Studi di Firenze, Florence, Italy*

2 *SOD Malattie Infettive e Tropicali, Azienda Ospedaliero-Universitaria Careggi, Florence, Italy*

3 *Department of Public Health, IRCCS, Istituto di Ricerche Farmacologiche Mario Negri, Milan, Italy*

4 *Centro per le Malattie Tropicali, Ospedale Classificato Equiparato “Sacro Cuore Don Calabria”, Verona, Italy*

5 *Barcelona Institute for Global Health, Universitat de Barcelona, Barcelona, Spain*

6 *Section of Neurosciences, University of Catania, Catania, Italy*

7 *Cysticercosis Unit, Universidad Peruana Cayetano Heredia, Lima, Peru*

Abstract

Neurocysticercosis, the central nervous system's localised form of cysticercosis, is considered to be the leading cause of epilepsy in the developing world. In Europe, the disease is mainly imported and affects both immigrants and travellers. However, autochthonous cases of cysticercosis in low-endemic countries could also originate from *Taenia solium* carriers (migrants or travellers) who acquired taeniasis overseas. Management of cysticercosis is a challenge for European healthcare providers as they are often hardly aware of this infection and have little familiarity in managing this disease. This study provides a summary of recommendations concerning screening, diagnosis and management of cysticercosis and *T. solium* taeniasis in Europe drawn up by nine experts in migrant health and imported diseases with experience in cysticercosis and *T. solium* taeniasis.

keywords cysticercosis, neurocysticercosis, taeniasis, *Taenia solium*, recommendations, epilepsy

Introduction

Cysticercosis occurs due to invasion of human or pig tissues at the metacystode larval stage of *Taenia solium* [1]. *Taenia solium* has a complex two-host life cycle [1]. Humans are the only definitive hosts, harbouring the adult tapeworm in the intestine without having significant symptoms (taeniasis) [2]. The adult tapeworm is acquired by eating raw or undercooked pork containing cysticerci [1]. Adult tapeworms have a life span of some years during which they produce millions of eggs which are intermittently released in the environment with the faeces [1]. Humans and pigs acquire cysticercosis by ingesting *T. solium* eggs through the faecal-oral route [1]. After ingestion, embryos contained in the eggs are released and cross the intestinal mucosa. They are then transported by the circulatory system and dispersed throughout the body, producing cysts mainly in the central nervous system (CNS) and in the striated muscles [1]. Human

infection frequently results from ingesting *T. solium* eggs released by themselves (autoinfestation) or by another tapeworm carrier living in close contact or involved in the preparation of food [3]. In humans, the CNS is a frequent localisation of cysts which thus cause neurocysticercosis (NCC) [1]. NCC is considered the most frequent and preventable cause of epilepsy in the developing world, resulting in around 30% of epilepsy cases [4, 5]. In high-resource regions such as Europe, cysticercosis is mainly imported currently and affects immigrants and travellers [6]. However, autochthonous cases of cysticercosis in low-endemic countries could also originate from *T. solium* carriers (migrant or traveller) who acquired taeniasis overseas [3]; thus, identifying and treating cases of taeniasis may prevent cases of cysticercosis. Management of cysticercosis is a challenge for European healthcare providers, as they are often poorly aware of this infection and have little familiarity in managing the disease [6].

The objective of this document is to provide a summary of recommendations concerning screening,

^aSee Acknowledgements for The COHEMI Project Study Group.

diagnosis and management of cysticercosis and *T. solium* taeniasis in Europe in order to improve the quality of cysticercosis management in non-endemic or low-endemic areas.

Methods

Within the COHEMI (COordinating resources to assess and improve HEalth status of MIgrants from Latin America) project, under the auspices of the European Commission, an international and interdisciplinary expert group was created [7]. One of COHEMI's general objectives was the evaluation of care strategy for cysticercosis/epilepsy and the production of a series of systematic reviews on its epidemiology, management, treatment and diagnostic tools [4, 6, 8–18].

A panel of nine researchers with expertise in migrant health and imported diseases, with specific experience in cysticercosis and *T. solium* taeniasis reviewed the literature, evaluated and discussed the evidence and prepared a consensus-based final report with recommendations.

Definitions

Case definition of cysticercosis:

- See Table 1.

Case definition of *T. solium* taeniasis:

- Confirmed case of taeniasis: laboratory-based diagnosis of taeniasis without species identification
- Probable case of taeniasis: reliable history of self-diagnosis by finding or reporting expelled tapeworm proglottids
- Confirmed case of *T. solium* taeniasis: confirmed case of taeniasis with species identification

Grading of evidence

In creating guidelines, the panel followed the Grading of Recommendations Assessment, Development and Evaluation (GRADE) system [19].

- Ia: systematic review or meta analysis of randomised controlled trials (RCTs)
- Ib: at least one RCT
- IIa: at least one well-designed controlled study without randomisation
- IIb: at least one well-designed quasi-experimental study, such as cohort study
- III: well-designed non-experimental descriptive studies, such as comparative studies, correlation studies, case-control studies and case series

- IV: expert committee reports, opinions and/or clinical experience of respected authorities.

Grading of recommendations

- A: based on hierarchy I evidence
- B: based on hierarchy II evidence or extrapolated from hierarchy I evidence
- C: based on hierarchy II evidence or extrapolated from hierarchy I or II evidence
- D: directly based on hierarchy IV evidence or extrapolated from hierarchy I, II or III evidence.

Results and recommendations

Who should be screened for cysticercosis?

In theory, screening for cysticercosis in completely asymptomatic subjects could be useful in people at risk for NCC to intercept infected subjects and improve their management and clinical outcome early. However, there is no evidence in favour of a screening for asymptomatic people [20]. From the scarce information on natural evolution of cysticercosis, most infected subjects will never develop symptoms [21]. Moreover, considering parenchymal NCC, its most common form, there is no evidence that treating an asymptomatic subject harbouring a live parasite will reduce the probability for neurological symptoms in future.

Therefore, according to classical criteria, to evaluate the utility of a screening programme, if the answer to the question: 'Does treatment at the presymptomatic stage of a disease affect its course and prognosis?' is not clearly 'yes', then there is no case for screening [22].

However, some presumed asymptomatic individuals may not be truly asymptomatic. The duration of the disease at the time of seeking medical care may be long-standing in patients with NCC and the median diagnostic delay ranges between 1 year in South Africa and 3.5 months in the United States [23]. Moreover, treatment of other conditions using antiparasitic drugs such as praziquantel (PZQ) or albendazole (ABZ) may result in adverse reactions during treatment in case of unrecognised cysticercosis (seizures or intracranial hypertension in case of cerebral cysts and ocular inflammation in case of ocular localisation). Therefore, investigating the presence of unrecognised signs or symptoms compatible with cysticercosis may be warranted in people at high risk of cysticercosis and in subjects with possible exposure in an endemic country who are undergoing treatment with antiparasitic drugs such as PZQ and ABZ (which may

Table 1 Diagnostic criteria and degree of certainty for the diagnosis of neurocysticercosis according to Del Brutto *et al.* [26]

Diagnostic criteria for neurocysticercosis		
Absolute criteria		<ul style="list-style-type: none"> • Histological demonstration of the parasite from biopsy of a brain or spinal cord lesion • Visualisation of subretinal cysticercus • Conclusive demonstration of a scolex within a cystic lesion on neuroimaging studies
Neuroimaging criteria	Major neuroimaging criteria	<ul style="list-style-type: none"> • Cystic lesions without a discernible scolex† • Enhancing lesions‡ • Multilobulated cystic lesions in the subarachnoid space • Typical parenchymal brain calcifications§
	Confirmative neuroimaging criteria	<ul style="list-style-type: none"> • Resolution of cystic lesions after cysticidal drug therapy • Spontaneous resolution of single small enhancing lesions¶ • Migration of ventricular cysts documented on sequential neuroimaging studies††
	Minor neuroimaging criteria	<ul style="list-style-type: none"> • Obstructive hydrocephalus (symmetric or asymmetric) • Abnormal enhancement of basal leptomeninges
Clinical/exposure criteria	Major clinical/exposure	<ul style="list-style-type: none"> • Detection of specific anticysticercal antibodies or cysticercal antigens by well-standardised immunodiagnostic tests‡‡ • Cysticercosis outside the central nervous system§§ • Evidence of a household contact with <i>Taenia solium</i> infection
	Minor clinical/exposure	<ul style="list-style-type: none"> • Clinical manifestations suggestive of neurocysticercosis¶¶ • Individuals coming from or living in an area where cysticercosis is endemic†††
Degree of certainty for the diagnosis of neurocysticercosis		
	Definitive diagnosis	<ul style="list-style-type: none"> • One absolute criterion • Two major neuroimaging criteria plus any clinical/exposure criteria • One major and one confirmative neuroimaging criteria plus any clinical/exposure criteria • One major neuroimaging criteria plus two clinical/exposure criteria (including at least one major clinical/exposure criterion), together with the exclusion of other pathologies producing similar neuroimaging findings
	Probable diagnosis	<ul style="list-style-type: none"> • One major neuroimaging criteria plus any two clinical/exposure criteria • One minor neuroimaging criteria plus at least one major clinical/exposure criteria

†Cystic lesions: rounded, well defined lesions with liquid contents of signal similar to that of cerebrospinal fluid on computed tomography (CT) or magnetic resonance imaging (MRI).

‡Enhancing lesions: single or multiple, ring- or nodular-enhancing lesions of 10–20 mm in diameter, with or without surrounding oedema, but not displacing midline structures.

§Typical parenchymal brain calcifications: single or multiple, solid and most usually <10 mm in diameter.

¶The use of corticosteroids makes this criterion invalid.

††Migration of ventricular cyst: demonstration of a different location of ventricular cystic lesions on sequential CTs or MRIs.

‡‡Well-standardised immunodiagnostic tests: so far, antibody detection by enzyme linked immunoelectrotransfer blot assay using lentil lectin-purified *T. solium* antigens, and detection of cysticercal antigens by monoclonal antibody-based enzyme-linked immunosorbent assay.

§§Cysticercosis outside the central nervous system: demonstration of cysticerci from biopsy of subcutaneous nodules, X-ray films or CT showing cigar-shape calcifications in soft tissues or visualisation of the parasite in the anterior chamber of the eye.

¶¶Suggestive clinical manifestations: mainly seizures (often starting in individuals aged 20–49 years; the diagnosis of seizures in this context is not excluded if patients are outside of the typical age range), but other manifestations include chronic headaches, focal neurologic deficits, intracranial hypertension and cognitive decline.

†††Cysticercosis-endemic area: a place where active transmission is documented.

result in adverse reactions during treatment in case of unrecognised cysticercosis).

Grading of evidence: IV.

Recommendations: A clinical assessment to investigate unrecognised compatible symptoms of cysticercosis (history of convulsions and/or other compatible neurological signs or symptoms) and physical examination to detect subcutaneous nodules compatible with cysticercosis are recommended in subjects at high risk for cysticercosis such as

- Confirmed *T. solium* taeniasis cases;
- Household and daily contacts of confirmed *T. solium* taeniasis cases;
- Family members of cysticercosis cases who are likely to have been exposed to the same environment as the index case.

The same approach could be recommended for subjects with possible exposure in an endemic country before undergoing treatment with antiparasitic drugs such as PZQ and ABZ which may cause adverse reactions in case of unrecognised cysticercosis.

Subjects with compatible signs or symptoms should be fully assessed including appropriate brain imaging (CT scan and/or MRI; Appendix 1).

Grading of recommendations: D.

How to diagnose cysticercosis

In 1996, a group of experts developed a set of diagnostic criteria for cysticercosis that was updated for NCC in 2001, reviewed in 2012 and revised in 2016 [24–26]. The updated set of criteria includes absolute, neuroimaging and clinical/exposure criteria [26]. Absolute criteria include histological confirmation of parasites, evidence of subretinal cysts and demonstration of the scolex within a cyst. Neuroimaging criteria are categorised as major (cystic lesions without scolex, enhancing lesions, multilobulated cysts in the subarachnoid space and calcifications), confirmative (resolution of cysts after cysticidal drug therapy, spontaneous resolution of single enhancing lesions, and migrating ventricular cysts on sequential neuroimaging studies) and minor (hydrocephalus and leptomeningeal enhancement). Clinical/exposure criteria include detection of anticysticercal antibodies or cysticercal antigens by well-standardised tests, systemic cysticercosis, evidence of a household *Taenia* carrier, suggestive clinical manifestations and residency in endemic areas.

The interpretation and combination of the criteria result in two degrees of diagnostic certainty: definitive and probable. Recently, a modified version of the 2001 criteria [24] was published by another group [27]. New

criteria proposed in this study were tested using 93 previously diagnosed cases of NCC (all types) and 93 controls in whom diagnosis was ruled out and found to be similar to the existing set of diagnostic criteria by Del Brutto *et al.* [24, 28]. However, the validity of their modified set has not yet been assessed by a prospective study. Moreover, inclusion of antibody detection by ELISA as a major contributor to diagnosis may affect the specificity of these criteria as most commercially available ELISAs cross-react with other frequent cestode infections such as hymenolepiasis and hydatid disease [29].

Even if formal diagnostic criteria exist, the diagnosis of cysticercosis still represents a challenge, especially in non-endemic areas such as Europe, where healthcare providers are hardly aware of the disease [6] and the level of expertise required for interpretation of neuroimaging is sometimes lacking.

Grading of evidence: IIb.

Recommendations: The use of the widely accepted and recently revised, diagnostic criteria (Table 1) [26] is advised for the diagnosis of NCC.

Grading of recommendations: B.

Who should be screened for *Taenia solium* taeniasis?

Intestinal taeniasis causes mostly non-specific and rarely noticeable symptoms [30]. Identification and treatment of subjects with *T. solium* taeniasis are important because these subjects may transmit cysticercosis to their contacts. In endemic areas, about 15–25% of NCC patients have a tapeworm or a previous history of taeniasis [30–32]. In Europe, intestinal taeniasis was found in 0–3.8% of patients with autochthonous and imported cysticercosis, respectively [6]. In the United States, 21% patients with NCC had a tapeworm carrier among asymptomatic household contacts [33] and this percentage increased to 45% in a study that considered only households of NCC patients aged 3 years or younger [34]. Finally, the presence of taeniasis in patients with NCC has been associated with increased severity of cerebral infestation [35]. The chance of finding a tapeworm in a patient with clinical manifestations, or in his household contacts, depends on how long the subject has been exposed in an endemic region and how much time has passed after immigrating from an endemic region. Most tapeworms probably die before the 3 to 5-year NCC pre-patent period [36]. Hence, the yield of screening for *T. solium* is expected to be quite low in most NCC cases in non-endemic areas. Screening for taeniasis should focus on individuals with live parenchymal cysts or enhancing lesions and their household members. Detecting tapeworm carriers is

important because they can transmit cysticercosis by disseminating viable *T. solium* eggs [36].

The diagnostic test (see recommendations in paragraph 4.4), even if it has a low sensitivity, is not expensive.

Grading of evidence: III.

Recommendations: Testing for *T. solium* taeniasis is recommended in the following subjects:

- Patients with cysticercosis and live parenchymal cyst or enhancing lesions
- Household and daily contacts of patients with cysticercosis, especially if a recent and/or local transmission is suspected (children, patients not exposed in endemic countries, patients with viable cysticerci)
- Subjects presenting a reliable history of proglottids expulsion within the last year (voiding from the anus, spontaneous or with faeces, of a noodle like piece of worm)

Grading of recommendations: D.

How to diagnose *Taenia solium* taeniasis

Some problems hamper the diagnosis of *T. solium* infection: the lack/unspecificity of symptoms, the poor sensitivity of parasitological investigations and the morphological and antigenic similarity between *T. solium* and other *Taenia* spp. (*T. saginata* and *T. asiatica*).

As expulsion of tapeworm proglottids/eggs does not occur daily, diagnosis by coprology is difficult [1]. Coprology for taeniasis includes both macroscopic (for detection of proglottids) and microscopic examination (for detection of eggs) [32]. The reported sensitivity of microscopy ranges from 0% to 59% [37, 38]. An inexpensive and useful tool to support the diagnosis of ‘self-detected’

taeniasis is documenting the history of proglottid expulsion over the past few months or a year [39].

Morphological identification through examination of scolex or stained mature proglottids (Table 2) is the most common laboratory procedure to identify the *Taenia* species. Morphological identification has several limits. The scolex is rarely available, the staining of proglottids is a laborious procedure and tapeworms may present some abnormalities or may be damaged, making identification difficult [32]. A purge with electrolyte-polyethylene glycol salt (EPS), 2 h before and 2 h after niclosamide treatment, has improved recovery of the scolex and the quality of the expelled proglottids [40].

Three other ways to differentiate *Taenia* species are enzyme electrophoresis (glucose phosphate isomerase zymogrammes), molecular methods (different types of polymerase chain reaction, PCR) [32] and Coproantigen Enzyme Linked Immune Assay (CoAg-ELISA).

A *T. solium* species-specific [41] CoAg-ELISA shows high sensitivity (84.5–98%) and specificity (99%) [42, 43]. Unfortunately, it is experimental, not commercially available and rarely available except to those working in this field. Similarly, neither enzyme electrophoresis nor PCR is available in most laboratories.

Grading of evidence: III.

Recommendations: The following tools are recommended for the diagnosis of *T. solium* taeniasis:

- Investigating the history of proglottids expulsion within the past year, with the support of visual materials to help the subject identify the proglottids
- Microscopic and macroscopic examination of stool samples collected on three different days
- *Taenia* species identification should always be performed, especially in subjects exposed to *T. solium* in

Table 2 Morphological differences between *Taenia solium*, *Taenia saginata* and *Taenia asiatica* [32]

	<i>T. solium</i>	<i>T. saginata</i>	<i>T. asiatica</i>
Scolex			
Rostrellum	Present	Absent	Present
Hooks	22–32	Absent	Absent
Mature proglottids			
Number of testes	375–575	800–1200	324–1216
Ovary	3 lobes	2 lobes	2 lobes
Vaginal sphincter	Absent	Present	Present
Gravid proglottids			
Number of unilateral uterine branches	7–16	14–32	11–32
Branching pattern	Dendritic	Dichotomous	Dichotomous
Expulsion from host	Passively (usually with faeces), in groups	Actively (outside defecation), single	Actively (outside defecation), single

The eggs of *T. solium*, *T. saginata* and *T. asiatica* cannot be distinguished morphologically.

highly endemic countries (Latin America, Asia and Africa). In such cases, if only morphological identification is available, a purge with EPS 2 h before and 2 h after the treatment may improve the recovery of the scolex and quality of the expelled proglottids. Patients should be provided with a container and asked to collect their faeces in the first 24 h after purge.

Grading of recommendations: D.

How to treat cysticercosis

General principles and precautions.

- Treatment for NCC must be individualised based on the number and location of lesions, as well as viability of the parasites within the nervous system
- Patients with NCC should ideally be managed by a multidisciplinary team of healthcare professionals (such as specialists in neurology, infectious diseases, neurosurgery, neuroradiology and paediatrics)
- Therapeutic measures include symptomatic medication, antiparasitic drugs and surgery
- Antiparasitic drug treatment is never an urgent need, precaution is indicated, especially in patients with intracranial hypertension secondary to NCC
- Patients should first be stabilised if intracranial hypertension is present (by placing a ventricle-peritoneal shunt) and/or if other symptoms such as epilepsy and headache are present (using antiepileptic and analgesic drugs)
- Before initiating antiparasitic treatment for NCC, the patient should be examined for particular locations and forms of the disease (presence of ocular cysticercosis, massive/encephalitic NCC, intraventricular NCC, cysts in other risk areas such as the brainstem) that may increase the risk of adverse events in case of antiparasitic treatment
- Treatment of NCC with antiparasitic drugs should be performed under medical supervision for at least 1 week and administered with concomitant steroid therapy, preceded by appropriate symptomatic treatment.

Causative treatment. Parenchymal NCC: viable, colloidal and granulo-colloidal (degenerating) and calcified cysts. Evidence demonstrates that ABZ (usual doses 15 mg/kg/day p.o. in two doses divided for 8–15 days) or PZQ (usual dose 50 mg/kg/day p.o. for 15 days) is approximately 60% effective in destroying viable cysts, and in clearing all parasites from fewer than 40% of patients [44, 45]. According to a recent meta-analysis, ABZ is probably safe and effective in reducing both the number of cysts and long-term seizure risk (by

6.1%; 95% CI 0.3–11.9%) in patients with parenchymal NCC [46]. A meta-analysis showed clinical (increased rate of seizure-free period) and radiological benefit in treating solitary cysticercus granuloma with antiparasitic drugs (ABZ in majority of the cases) [47]. Another meta-analysis found that the association of ABZ and corticosteroids is the most efficacious regimen and that it could prevent seizure recurrence and promote lesion resolution in a follow-up period of around 1 year [48].

The combination of ABZ and PZQ increased the parasiticidal effect in patients with multiple intraparenchymal cysticercosis cysts without increased side effects during a double-blind placebo-controlled phase-3 trial. The complete resolution of brain cysts at 6 months with MRI was achieved in 64% of the patients who received combined ABZ (15 mg/kg/day) plus PZQ (50 mg/kg/day) for 10 days, in 37% of those who received ABZ at the standard dosage (15 mg/kg/day) for 10 days and in 53% of patients who got ABZ at increased dosage (22.5 mg/kg/day) for 10 days [49]. Complete cyst resolution was significantly associated with fewer seizures in the follow-up [49].

Similar results were reported in a randomised, double-blinded, placebo-controlled phase II evaluation of the pharmacokinetics of ABZ (15 mg/kg/day, for 10 days) and PZQ (50 mg/kg/day, for 10 days) in intraparenchymal brain cysticercosis. Cysticidal efficacy was strikingly higher in the combined ABZ-plus-PZQ group than in the ABZ-alone group (proportion of cysts resolved, 95% *vs.* 30%) [50].

Current practice favours antiparasitic treatment in most patients with viable infections, after individual assessment and exclusion of high-risk situations (massive infections, intraventricular cysts and concomitant ocular cysticercosis) [51]. Another meta-analysis suggests that corticosteroids can speed resolution of lesions at 6–12 months and reduce the rate of seizures [52]. Between the second and the fifth day of antiparasitic treatment [53], death of the parasites triggers a local inflammatory reaction which may precipitate further neurological symptoms (and even become fatal in rare cases). Therefore, some experts recommend that corticosteroids should be started a day before the onset of antiparasitic treatment and tapered in a period of 6–8 weeks or longer [53, 54]. An open-labelled randomised trial comparing 6 mg/day dexamethasone for 10 days with 8 mg/day for 28 days followed by a 2-week taper (enhanced steroids) suggested that increased dexamethasone dosage results in fewer seizures during the treatment period [55]. Dexamethasone reduces plasma concentration of PZQ [56]

although the clinical impact of this interaction has never been properly assessed.

Both PZQ and ABZ should be taken with food. Possible side effects of PZQ include malaise, headache, dizziness, nausea (the tablets have a bitter taste), fever, urticaria or other allergic reactions, palpitations or arrhythmias, bloody diarrhoea and convulsions. Possible side effects of ABZ include hepatotoxicity, agranulocytosis, alopecia, headache, nausea/vomiting, urticaria and abdominal pain. Full blood cell count and hepatic function of patients receiving ABZ should be monitored [57].

Concerning calcified intracranial cysticerci, increasing evidence demonstrates that perilesional oedema around a calcified lesion is associated with ongoing seizures [58]. Perilesional oedema may be responsible for seizure recurrence, recovering spontaneously within 4–6 weeks but sometimes experiencing repeated episodes. So far, there is no proven specific treatment for perilesional oedema episodes other than symptomatic therapy with antiseizures medication. However, anti-inflammatory measures (i.e. methotrexate) have been used in particular cases with apparent success [59].

Grading of evidence: Ia.

Recommendations:

- Treatment of NCC with antiparasitic drugs should be performed under medical supervision with concomitant steroid therapy, once an appropriate symptomatic treatment is well established (grading of recommendation D)
- Parenchymal NCC (in all stages, excluding calcified lesions) should be treated with ABZ 15 mg/kg/day in two doses (up to 400 mg twice a day) plus PZQ (50 mg/kg/day) both for 10 days (grading of recommendation A)
- In case of solitary cyst or granuloma, monotherapy with ABZ at the same dosage and duration may be sufficient
- Longer or repeated courses of antiparasitic treatment may be necessary since a single course may not be able to clear all cysts (grading of recommendation B)
- Corticosteroids should be used in conjunction with antiparasitic drugs (grade of recommendation A).
- Dexamethasone 8 mg/day for 28 days from the day before starting antiparasitic treatment followed by a 2-week taper is the preferred corticosteroid regimen (grading of recommendation A)

Subarachnoid NCC. Extraparenchymal NCC, in particular basal subarachnoid NCC, should be recognised as a progressive condition associated with a severe prognosis. Control of mass effect and intracranial hypertension is the priority. Once the patient is stable, antiparasitic

therapy should be initiated with appropriate care and continued for long periods with clinical, serological (antigen detection) and MRI follow-up. Monitoring of circulating parasite antigen in serum could be of great help in this type of NCC [60].

Grading of evidence: III.

Recommendations:

- Management of intracranial hypertension and hydrocephalus can be life-saving and is the priority in patients with extraparenchymal NCC. Many patients may benefit from placement of a ventriculoperitoneal shunt (grading of recommendation D)
- Antiparasitic drugs are recommended for an individualised duration of treatment based on imaging response. Long-term courses and repeated cycles are often needed (grading of recommendation D)
- Corticosteroids should always be associated with antiparasitic drugs to reduce subarachnoid inflammation. Generally, 1 mg/kg/day of prednisone or 0.2–0.4 mg/kg/day (with a maximum dose of 24 mg/day divided in 4 doses) of dexamethasone is administered 3 or 4 days before and during antiparasitic treatment and then tapered. Long-term corticosteroids therapy at lower doses is often required in patients with a ventricular shunt [61] (grading of recommendation D)
- Given its severity and rarity and the few available evidences, clinicians managing subarachnoid NCC should seek advice from an expert.

Grading of recommendation: D.

Intraventricular NCC. In the past decade, availability of neuroendoscopic exploration and cyst removal using minimally invasive procedures has provided a safer and more efficacious approach for the treatment of ventricular NCC. However, there are no randomised treatment trials comparing the usefulness and safety of surgery with medical approaches. According to a review on this topic, neuroendoscopy or open microsurgery is indicated to remove cysts in case they are causing mass effect, CSF obstruction, in case of fourth ventricular cysts or if the diagnosis is uncertain [62]. Adhered cysts (usually degenerating cysts) should not be removed surgically as they may cause bleeding during the procedure.

Grading of evidence: III.

Recommendations:

- Emergency ventriculostomy or ventriculoperitoneal shunt (VPS) is indicated in case of acute hydrocephalus (grading of recommendation D)
- VPS placement is indicated in case of obstructive/communicating hydrocephalus (grading of recommendation D)

- Neuroendoscopy or open microsurgery is indicated to remove cysts in case they are causing mass effect, CSF obstruction, in case of fourth ventricular cysts or if the diagnosis is uncertain (grading of recommendation D)
- Medical treatment of intraventricular cysts with antiparasitic drugs and corticosteroid is an option primarily for adhered cysts, but there is no evidences to recommend it as a preferred regimen
- Given its severity and rarity and the few available evidences, clinicians managing intraventricular NCC should seek advice from an expert.

Grading of recommendation: D.

Spinal NCC. Spinal NCC mostly has an extramedullary, subarachnoid localisation. Although some patients show focal symptoms, asymptomatic spinal invasion is also frequently found in patients with basal subarachnoid NCC. It is unclear what the best treatment approach is for symptomatic spinal NCC [63]. Surgery may be needed in patients with symptoms due to mass effect on the spinal cord and those who require immediate relief of pressure. In patients with asymptomatic spinal invasion, a non-surgical approach seems to be preferable [64].

Grading of evidence: III.

Recommendations:

- Management of spinal extramedullary NCC is performed primarily with corticosteroids and antiparasitic treatment. This is similar to the subarachnoid disease in the brain (grading of recommendation D)
- Surgery may be needed in case patients show symptoms due to mass effect on the spinal cord and need immediate relief of pressure (grading of recommendation: D)
- Management of spinal intramedullary NCC is performed preferably with antiparasitic drugs and corticosteroids (grading of recommendation: D)
- If resources permit, a spine MRI should be performed on subjects with basal subarachnoid NCC (grading of recommendation: D)

Ocular cysticercosis. Cysticerci may appear in the anterior and posterior chamber of the eye. Vitreous and retinal cysticercosis will most likely result in significant reduction of visual capacity in the patient. Ocular cysticercosis is usually managed by surgery [65]. Unrecognised ocular cysticercosis could lead to ocular damage if antiparasitic treatment for NCC is started [66].

Grading of evidence: III.

Recommendations: The management of ocular cysticercosis is usually by surgery (grading of recommendation D).

Cysticercosis in other localisations. Subcutaneous or muscular cysticercosis can be found occasionally, mostly by questioning the patient. These cysts provide a possibility for histological confirmation of diagnosis. Clinically, subcutaneous or muscular NCC is not a significant problem. Cardiac cysticercosis has been reported but so far without producing clinical manifestations.

Follow-up

Neuroimages show degeneration and/or resolution of active parenchymal lesions after 3–6 months of antiparasitic treatment [46]. Antibody persistence is of little use in follow-up as enzyme-linked immunoelectrotransfer blot (EITB) positivity persists in most (77%) of the cured patients 1 year after treatment [67]. Detection of circulating antigen ELISA in serum could be helpful to follow up patients after treatment as it is able to demonstrate the presence of viable cysts and a relatively fast decrease in antigen levels is expected after successful antiparasitic treatment [68]. However, there are few data on its use, especially concerning how well a non-detectable level predicts successful cure and its performance in CSF compared to serum.

Grading of evidence: III.

Recommendations:

- Follow-up of parenchymal NCC should initially include neuroimages performed every 3–6 months, and detection of cysticercus antigen in serum if the test is available (grading of recommendation D)
- A stricter follow-up (every 3 months or closer in case of clinical deterioration) based on both neuroimages (MRI) and cysticercus antigen in serum is needed for patients with subarachnoid NCC to guide treatment. In these cases, the ideal end-point is resolution of cystic lesions; an acceptable end-point is stabilisation of lesions in those that do not resolve. Subarachnoid NCC can lead to distortion of the subarachnoid space and ongoing contrast-enhancement despite successful therapy (grading of recommendation: D).

Treatment of epilepsy in patients with NCC

Seizures usually respond very well to first-line antiepileptic drug (AED) monotherapy [69, 70]. The risk of seizure recurrence following an initial seizure in NCC is 50–80% in patients who discontinued AEDs [71]. Risk of recurrence of seizure during treatment with AED is highly variable (13–48% in patients with solitary cysticercus granuloma over a period of 6–12 months) and it is higher in patients with degenerating lesions compared to those with resolved

lesions [71]. Only 15% of subjects with resolved single cysticercus granuloma had seizure recurrence after the discontinuation of AED [71]. In patients with resolved lesions, the presence of calcified residues represents the main risk factor for seizure recurrence. The mechanism by which the calcified lesions cause seizures or epilepsy is unknown but perilesional gliosis, perilesional oedema and the presence of hippocampal atrophy may play a role. [70, 71]. There are a few trials comparing various AEDs in people with NCC. The main drug interactions between AED and other drugs commonly used for treatment of NCC involve phenytoine (which decreases serum level of PZQ, prednisone and dexamethasone), phenobarbital (which decreases the level of prednisone and dexamethasone) and dexamethasone (which decreases the level of phenytoine) [72]. No evidence is available regarding the use of AEDs as prophylaxis for preventing seizures among people with symptoms other than seizures [73].

Grading of evidence: III.

Recommendations:

- Patients with NCC and seizures should be treated with first-line AED
- The choice of AED is largely individualised taking into consideration different side effects of AEDs and drug interactions
- After disappearance of the lesions, most patients – if free of seizures for 2 years – can eventually discontinue AEDs [74], while a longer period is advisable in case of persistent calcifications and other risk factors associated with seizure recurrences
- Even if there is no evidence to recommend AED treatment in patients without seizures before starting antiparasitic treatment, a conservative approach would be to start AED before treating a viable cyst with antiparasitic drugs.

Grading of recommendations: D.

Table 3 Principal characteristics and dosages of niclosamide and praziquantel [32]

	Niclosamide	Praziquantel
Class	Halogenated salicylanilide	Acylatedisoquinoline-pyrazine
Absorption	Very little	Yes
Mechanism of action	Blocks glucose uptake	Increases calcium permeability and causes blisters on the integument
Contraindication	Concomitant alcohol use Age less than 2 years	Ocular cysticercosis Age less than 4 years
Precaution	None	May sporadically cause symptoms onset (i.e. seizures) in patients with asymptomatic neurocysticercosis due to inflammatory reaction around the damaged cysticerci†
Mode of assumption	At empty stomach, chewed thoroughly before swallowing and washed down with some water. A saline purgative is not necessary except in chronically constipated patients, who should be appropriately treated the evening before the therapy‡	The absorption is increased by a fatty meal
Available formulation	Tablets 500 mg	Tablets 600 mg
Standard dosage	Body weight ≥35 kg: 2 g single dose Body weight 10–34 kg: 1 g single dose Body weight <10 kg: 0.5 g single dose	5–10 mg/kg in single dose
Side effects	Negligible	Abdominal discomfort, pyrexia, urticaria, dizziness
Use in pregnancy	FDA category B	FDA category B
Lactating women [76]	Compatible with breastfeeding	Compatible with breastfeeding
Efficacy	About 85%§	About 95%§

†Symptoms possibly related to activation of cysticercosis were observed in one person among 10 173 people treated with praziquantel in Ecuador [77].

‡In order to improve the recovery of the scolex and the quality of the expelled proglottids, a purge with electrolyte-polyethylene glycol salt (EPS), 2 h before and 2 h after niclosamide treatment, can be applied [40].

§The efficacy has been assessed mainly in *T. saginata* taeniasis, using microscopic examination and/or clinical follow-up as test of cure that could have overestimated the efficacy. A recent study on treatment of *Taenia solium* taeniasis with niclosamide using Coproantigen-ELISA as test of cure found a cure rate of 77.9% (53/68). A second treatment course with niclosamide cured 11/13 of patients that initially failed. Overall, niclosamide cured 64/66 (97%) patients [78].

How to treat *Taenia solium* taeniasis

The main goals of the treatment of *T. solium* taeniasis are to prevent new cases of human and porcine cysticercosis, impede the spread of cysticercosis in people and interrupt the life cycle of the parasite. Single patient treatment is recommended given the possibility of autoinfestation and the association with more severe form of NCC in subjects with taeniasis [35].

Two drugs are available and widely used for the treatment of taeniasis: niclosamide and PZQ. The principal characteristics of the two drugs are reported in Table 3.

Grading of evidence: IIa.

Recommendations:

- Confirmed and probable case of taeniasis should be treated with niclosamide or PZQ at standard dosages (see Table 3).
- Clinicians should be aware that PZQ may sporadically cause symptoms (i.e. seizures) in patients with unrecognised asymptomatic NCC due to inflammatory reaction around the damaged cysticerci. If PZQ is used, recommendations reported in Appendix 1 have to be followed.
- *Taenia* species identification should always be performed, especially in subjects exposed to *T. solium* in highly endemic countries (Latin America, Asia and Africa).

After therapy, the patient should be followed up to confirm the efficacy of treatment by:

- Questioning the history of proglottids expulsion after 1 week of treatment
- Microscopic and macroscopic examination of stool samples repeated on different days at months 1 and 3
- CoAg-ELISA at months 1 and 3, if available
- If any of the above reported tests is positive, the treatment should be repeated.

Grading of recommendations: C.

Acknowledgements

This work has been supported by the EC within the 7th Framework Program under grant agreement no. FP7-GA-261495. We thank Miss Elizabeth Cavanaugh Vincent for proofreading and English corrections and the COHEMI (COordinating resources to assess and improve HEalth status of MIgrants from Latin America)-project study group that includes:

Maurizio Bonati^a, Chiara Pandolfini^a, Francesca Severino^a, Valeria Confalonieri^a, Gianni Tognoni^a, Zeno Bisoffi^b, Dora Buonfrate^b, Andrea Angheben^b, Marco

Albonico^b, Alessandro Bartoloni^c, Marianne Strohmeier^c, Lorenzo Zammarchi^c, Filippo Bartalesi^d, Jose Muñoz^e, Ana Requena-Mendez^e, Maria Roura^e, Laia Ventura^e, Robert Pool^f, Christopher Pell^f, Anita Hardon^f, Peter Chiodini^g, Juan Moreira^h, Mariella Anselmi^h, Roberto Sempértegui^h, Eduardo Gotuzzoⁱ, Maria Alejandra Menaⁱ, Carola Liendoⁱ, Héctor H. Garciaⁱ, Javier Bustos^j, Saul Santivañez^j, Faustino Torrico^k, Daniel Lozano^k, Teresa Hinojosa Cabrera^l, Javier Ochoa Morón^l, Ignacio Abapori Cuellar^l, Jaime Amorós Suarez^l, Guido Chumiray Rojas^l, Alessandra Nicoletti^m, Elisa Bruno^m.

^aDepartment of Public Health, Laboratory for Mother and Child Health, IRCCS-Istituto di Ricerche Farmacologiche Mario Negri, Milan, Italy.

^bCentre for Tropical Diseases, Sacro Cuore-Don Calabria Hospital, Negrar, Verona, Italy.

^cInfectious Disease Unit, Department of Experimental & Clinical Medicine, University of Florence School of Medicine, Florence, Italy.

^dSOD Malattie Infettive e Tropicali, Azienda Ospedaliero-Universitaria Careggi, Florence, Italy.

^eServicio de Medicina Tropical y Salud Internacional, Centre de Recerca en Salut Internacional de Barcelona, Hospital Clínic-Universitat de Barcelona, Barcelona, Spain.

^fCentre for Social Science and Global Health, University of Amsterdam, The Netherlands.

^gHospital for Tropical Diseases and London School of Hygiene & Tropical Medicine, London, United Kingdom.

^hCentre for Community Epidemiology and Tropical Medicine, Esmeraldas, Ecuador.

ⁱInstituto de Medicina Tropical Alexander von Humboldt, Universidad Cayetano Heredia, Lima, Peru.

^jCysticercosis Unit, Instituto de Ciencias Neurológicas, Department of Microbiology, Universidad Peruana Cayetano Heredia, Lima, Peru.

^kColectivo de Estudios Aplicados y Desarrollo Social, Cochabamba, Bolivia.

^lTaller de Educación y Comunicación TEKO-GUARANÍ, Camiri, Bolivia.

^mDipartimento G.F. Ingrassia Sezione di Neuroscienze, Università di Catania, Catania, Italy.

References

1. Garcia HH, Del Brutto OH. *Taenia solium* cysticercosis. *Infect Dis Clin North Am* 2000; **14**: 97–119, ix.
2. Pawlowski Z, Allan J, Sarti E. Control of *Taenia solium* taeniasis/cysticercosis: from research towards implementation. *Int J Parasitol* 2005; **35**: 1221–1232.
3. Schantz PM, Moore AC, Munoz JL *et al.* Neurocysticercosis in an Orthodox Jewish community in New York City. *N Engl J Med* 1992; **327**: 692–695.

L. Zammarchi *et al.* **COHEMI recommendations on neurocysticercosis**

4. Bruno E, Bartoloni A, Zammarchi L *et al.* Epilepsy and neurocysticercosis in Latin America: a systematic review and meta-analysis. *PLoS Negl Trop Dis* 2013; 7: e2480.
5. Ndimubanzi PC, Carabin H, Budke CM *et al.* A systematic review of the frequency of neurocysticercosis with a focus on people with epilepsy. *PLoS Negl Trop Dis* 2010; 4: e870.
6. Zammarchi L, Strohmeyer M, Bartalesi F *et al.* Epidemiology and management of cysticercosis and *Taenia solium* taeniasis in Europe, systematic review 1990–2011. *PLoS One* 2013; 8: e69537.
7. The COHEMI Project Study Group. COHEMI web site, 2011. (Available from: <http://www.cohemi-project.eu/>) [21 Sept 2012].
8. Bruno E, Bartoloni A, Sofia V *et al.* Sociocultural dimension of epilepsy: an anthropological study among Guarani communities in Bolivia – an International League Against Epilepsy/International Bureau for Epilepsy/World Health Organization Global Campaign against Epilepsy regional project. *Epilepsy Behav* 2011; 22: 346–351.
9. Bruno E, Bartoloni A, Sofia V *et al.* Epilepsy-associated stigma in Bolivia: a community-based study among the Guarani population: an International League Against Epilepsy/International Bureau for Epilepsy/World Health Organization Global Campaign Against Epilepsy Regional Project. *Epilepsy Behav* 2012; 25: 131–136.
10. Buonfrate D, Angheben A, Gobbi F *et al.* Imported strongyloidiasis: epidemiology, presentations, and treatment. *Curr Infect Dis Rep* 2012; 14: 256–262.
11. Bisoffi Z, Buonfrate D, Montresor A *et al.* *Strongyloides stercoralis*: a plea for action. *PLoS Negl Trop Dis* 2013; 7: e2214.
12. Buonfrate D, Requena-Mendez A, Angheben A *et al.* Severe strongyloidiasis: a systematic review of case reports. *BMC Infect Dis* 2013; 13: 78.
13. Pinazo MJ, Espinosa G, Cortes-Lletget C *et al.* Immunosuppression and Chagas disease: a management challenge. *PLoS Negl Trop Dis* 2013; 7: e1965.
14. Requena-Mendez A, Chiadini P, Bisoffi Z *et al.* The laboratory diagnosis and follow up of strongyloidiasis: a systematic review. *PLoS Negl Trop Dis* 2013; 7: e2002.
15. Requena-Mendez A, Lopez MC, Angheben A *et al.* Evaluating Chagas disease progression and cure through blood-derived biomarkers: a systematic review. *Expert Rev Anti Infect Ther* 2013; 11: 957–976.
16. Ventura-Garcia L, Roura M, Pell C *et al.* Socio-cultural aspects of Chagas disease: a systematic review of qualitative research. *PLoS Negl Trop Dis* 2013; 7: e2410.
17. Zammarchi L, Bartoloni A, Munoz J. Chagas disease is a consideration in Latino patients. *Am Fam Physician* 2013; 88: 566.
18. Bisoffi Z, Buonfrate D, Sequi M *et al.* Diagnostic accuracy of five serologic tests for *Strongyloides stercoralis* infection. *PLoS Negl Trop Dis* 2014; 8: e2640.
19. Guyatt GH, Oxman AD, Vist GE *et al.* GRADE: an emerging consensus on rating quality of evidence and strength of recommendations. *BMJ* 2008; 336: 924–926.
20. Garcia HH, Rodriguez S, Gilman RH, Gonzalez AE, Tsang VC. Neurocysticercosis: is serology useful in the absence of brain imaging? *Trop Med Int Health* 2012; 17: 1014–1018.
21. Cruz ME, Preux PM, Debrock C *et al.* Epidemiology of cerebral cysticercosis in an Andean community in Ecuador. *Bull Soc Pathol Exot* 1999; 92: 38–41.
22. Wilson J, Jungner G. *Principles and Practice of Screening for Disease*. World Health Organization: Geneva, 1968.
23. Carabin H, Ndimubanzi PC, Budke CM *et al.* Clinical manifestations associated with neurocysticercosis: a systematic review. *PLoS Negl Trop Dis* 2011; 5: e1152.
24. Del Brutto OH, Rajshekhar V, White AC Jr *et al.* Proposed diagnostic criteria for neurocysticercosis. *Neurology* 2001; 57: 177–183.
25. Del Brutto OH. Diagnostic criteria for neurocysticercosis, revisited. *Pathog Glob Health* 2012; 106: 299–304.
26. Del Brutto OH, Nash TE, White AC Jr *et al.* Revised diagnostic criteria for neurocysticercosis. *J Neurol Sci* 2017; 372: 202–210.
27. Carpio A, Fleury A, Romo ML *et al.* New diagnostic criteria for neurocysticercosis: reliability and validity. *Ann Neurol* 2016; 80: 434–442.
28. Del Brutto OH, Wadia NH, Dumas M *et al.* Proposal of diagnostic criteria for human cysticercosis and neurocysticercosis. *J Neurol Sci* 1996; 142: 1–6.
29. Rodriguez S, Wilkins P, Dorny P. Immunological and molecular diagnosis of cysticercosis. *Pathog Glob Health* 2012; 106: 286–298.
30. Craig P, Ito A. Intestinal cestodes. *Curr Opin Infect Dis* 2007; 20: 524–532.
31. Garcia HH, Gonzalez AE, Evans CA, Gilman RH. *Taenia solium* cysticercosis. *Lancet* 2003; 362: 547–556.
32. Allan J, Avila G, Brandt J *et al.* Chapter 2: Clinical cysticercosis: diagnosis and treatment. In: Murrell KD (ed). *WHO/FAO/OIE Guidelines for the Surveillance, Prevention and Control of Taeniosis/Cysticercosis*. World Organisation for Animal Health (OIE), World Health Organization (WHO) and Food and Agriculture Organization (FAO): Geneva, 2005.
33. Sorvillo F, Wilkins P, Shafir S, Eberhard M. Public health implications of cysticercosis acquired in the United States. *Emerg Infect Dis* 2011; 17: 1–6.
34. Del Brutto OH. Neurocysticercosis in infants and toddlers: report of seven cases and review of published patients. *Pediatr Neurol* 2013; 48: 432–435.
35. Gilman RH, Del Brutto OH, Garcia HH, Martinez M, the Cysticercosis Working Group in Peru. Prevalence of taeniosis among patients with neurocysticercosis is related to severity of infection. *Neurology* 2000; 55: 1062.
36. Lescano AG, Garcia HH, Gilman RH *et al.* *Taenia solium* cysticercosis hotspots surrounding tapeworm carriers: clustering on human seroprevalence but not on seizures. *PLoS Negl Trop Dis* 2009; 3: e371.
37. Rodriguez-Canul R, Fraser A, Allan JC *et al.* Epidemiological study of *Taenia solium* taeniasis/cysticercosis in a rural village

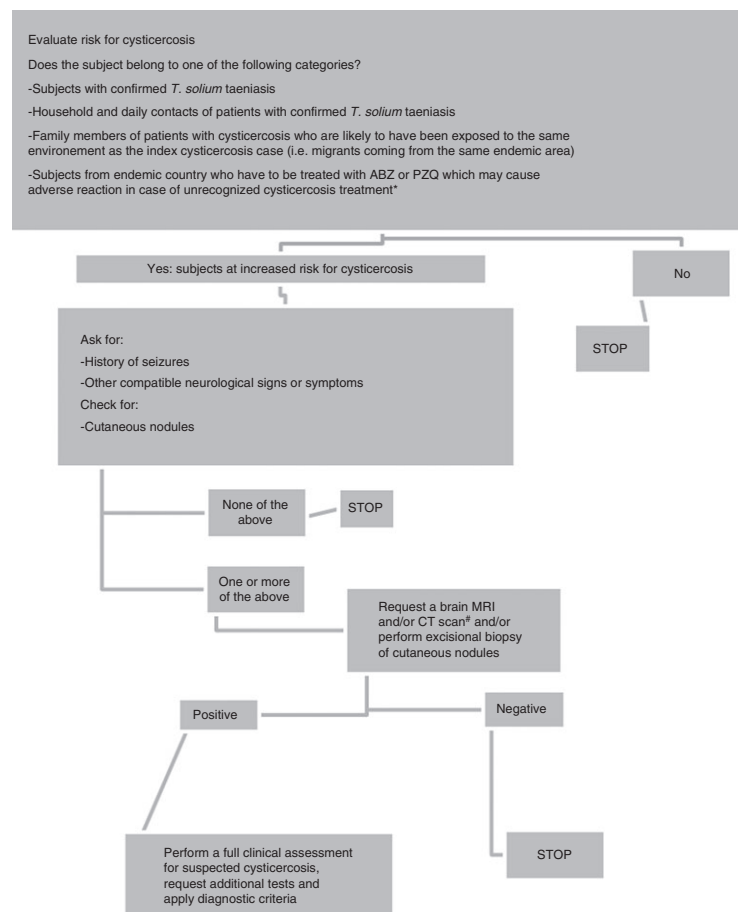
L. Zammarchi *et al.* **COHEMI recommendations on neurocysticercosis**

- in Yucatan state, Mexico. *Ann Trop Med Parasitol* 1999; **93**: 57–67.
38. Allan JC, Mencos F, Garcia-Noval J *et al.* Dipstick dot ELISA for the detection of *Taenia* coproantigens in humans. *Parasitology* 1993; **107**(Pt 1): 79–85.
 39. Flisser A. Where are the tapeworms? *Parasitol Int* 2006; **55** (Suppl): S117–S120.
 40. Jeri C, Gilman RH, Lescano AG *et al.* Species identification after treatment for human taeniasis. *Lancet* 2004; **363**: 949–950.
 41. Guezala MC, Rodriguez S, Zamora H *et al.* Development of a species-specific coproantigen ELISA for human *Taenia solium* taeniasis. *Am J Trop Med Hyg* 2009; **81**: 433–437.
 42. Allan JC, Velasquez-Tohom M, Torres-Alvarez R, Yurrita P, Garcia-Noval J. Field trial of the coproantigen-based diagnosis of *Taenia solium* taeniasis by enzyme-linked immunosorbent assay. *Am J Trop Med Hyg* 1996; **54**: 352–356.
 43. Praet N, Verweij JJ, Mwape KE *et al.* Bayesian modelling to estimate the test characteristics of coprology, coproantigen ELISA and a novel real-time PCR for the diagnosis of taeniasis. *Trop Med Int Health* 2013; **18**: 608–614.
 44. Garcia HH, Pretell EJ, Gilman RH *et al.* A trial of antiparasitic treatment to reduce the rate of seizures due to cerebral cysticercosis. *N Engl J Med* 2004; **350**: 249–258.
 45. Sotelo J, del Brutto OH, Penagos P *et al.* Comparison of therapeutic regimen of anticysticercal drugs for parenchymal brain cysticercosis. *J Neurol* 1990; **237**: 69–72.
 46. Baird RA, Wiebe S, Zunt JR *et al.* Evidence-based guideline: treatment of parenchymal neurocysticercosis: report of the Guideline Development Subcommittee of the American Academy of Neurology. *Neurology* 2013; **80**: 1424–1429.
 47. Otte WM, Singla M, Sander JW, Singh G. Drug therapy for solitary cysticercus granuloma: a systematic review and meta-analysis. *Neurology* 2013; **80**: 152–162.
 48. Zhao BC, Jiang HY, Ma WY *et al.* Albendazole and corticosteroids for the treatment of solitary cysticercus granuloma: a network meta-analysis. *PLoS Negl Trop Dis* 2016; **10**: e0004418.
 49. Garcia HH, Gonzales I, Lescano AG *et al.* Efficacy of combined antiparasitic therapy with praziquantel and albendazole for neurocysticercosis: a double-blind, randomised controlled trial. *Lancet Infect Dis* 2014; **14**: 687–695.
 50. Garcia HH, Lescano AG, Gonzales I *et al.* Cysticidal efficacy of combined treatment with praziquantel and albendazole for parenchymal brain cysticercosis. *Clin Infect Dis* 2016; **62**: 1375–1379.
 51. Nash TE, Garcia HH. Diagnosis and treatment of neurocysticercosis. *Nat Rev Neurol* 2011; **7**: 584–594.
 52. Cuello-Garcia CA, Roldan-Benitez YM, Perez-Gaxiola G, Villarreal-Careaga J. Corticosteroids for neurocysticercosis: a systematic review and meta-analysis of randomized controlled trials. *Int J Infect Dis* 2013; **17**: e583–e592.
 53. Garcia HH, Gonzalez AE, Gilman RH. Cysticercosis of the central nervous system: how should it be managed? *Curr Opin Infect Dis* 2011; **24**: 423–427.
 54. Nash TE, Mahanty S, Garcia HH. Corticosteroid use in neurocysticercosis. *Expert Rev Neurother* 2011; **11**: 1175–1183.
 55. Garcia HH, Gonzales I, Lescano AG *et al.* Enhanced steroid dosing reduces seizures during antiparasitic treatment for cysticercosis and early after. *Epilepsia* 2014; **55**: 1452–1459.
 56. Vazquez ML, Jung H, Sotelo J. Plasma levels of praziquantel decrease when dexamethasone is given simultaneously. *Neurology* 1987; **37**: 1561–1562.
 57. Grover JK, Vats V, Uppal G, Yadav S. Anthelmintics: a review. *Trop Gastroenterol* 2001; **22**: 180–189.
 58. Nash TE, Bustos JA, Garcia HH. Disease centered around calcified *Taenia solium* granuloma. *Trends Parasitol* 2017; **33**: 65–73.
 59. Nash T. Edema surrounding calcified intracranial cysticerci: clinical manifestations, natural history, and treatment. *Pathog Glob Health* 2012; **106**: 275–279.
 60. Fleury A, Carrillo-Mezo R, Flisser A, Sciotto E, Corona T. Subarachnoid basal neurocysticercosis: a focus on the most severe form of the disease. *Expert Rev Anti Infect Ther* 2011; **9**: 123–133.
 61. Kelley R, Duong DH, Locke GE. Characteristics of ventricular shunt malfunctions among patients with neurocysticercosis. *Neurosurgery* 2002; **50**: 757–761; discussion 761–752.
 62. Sinha S, Sharma BS. Intraventricular neurocysticercosis: a review of current status and management issues. *Br J Neurosurg* 2012; **26**: 305–309.
 63. Callacondo D, Garcia HH, Gonzales I, Escalante D, Nash TE. High frequency of spinal involvement in patients with basal subarachnoid neurocysticercosis. *Neurology* 2012; **78**: 1394–1400.
 64. Del Brutto OH, Garcia HH. Intramedullary cysticercosis of the spinal cord: a review of patients evaluated with MRI. *J Neurol Sci* 2013; **331**: 114–117.
 65. Sharma T, Sinha S, Shah N *et al.* Intraocular cysticercosis: clinical characteristics and visual outcome after vitreoretinal surgery. *Ophthalmology* 2003; **110**: 996–1004.
 66. Sundar U, Chawla V, Lakkas Y *et al.* Monocular blindness during therapy for cerebral neurocysticercosis. *J Assoc Physicians India* 2010; **58**: 570–572.
 67. Garcia HH, Gilman RH, Catacora M, Verastegui M, Gonzalez AE, Tsang VC. Serologic evolution of neurocysticercosis patients after antiparasitic therapy. Cysticercosis Working Group in Peru. *J Infect Dis* 1997; **175**: 486–489.
 68. Gabriel S, Blocher J, Dorny P *et al.* Added value of antigen ELISA in the diagnosis of neurocysticercosis in resource poor settings. *PLoS Negl Trop Dis* 2012; **6**: e1851.
 69. Del Brutto OH, Santibanez R, Noboa CA *et al.* Epilepsy due to neurocysticercosis: analysis of 203 patients. *Neurology* 1992; **42**: 389–392.
 70. Bustos JA, Garcia HH, Del Brutto OH. Antiepileptic drug therapy and recommendations for withdrawal in patients with seizures and epilepsy due to neurocysticercosis. *Expert Rev Neurother* 2016; **16**: 1–7.
 71. Singh G, Burneo JG, Sander JW. From seizures to epilepsy and its substrates: neurocysticercosis. *Epilepsia* 2013; **54**: 783–792.

72. Drug digest online database. (Available from: <http://www.drugdigest.org>) [31 Oct 2013].
73. Sharma M, Singh T, Mathew A. Antiepileptic drugs for seizure control in people with neurocysticercosis. *Cochrane Database Syst Rev* 2015; 10: CD009027.
74. Takayanagui OM, Odashima NS, Bonato PS, Lima JE, Lanchote VL. Medical management of neurocysticercosis. *Expert Opin Pharmacother* 2011; 12: 2845–2856.
75. Garcia HH, Nash TE, Del Brutto OH. Clinical symptoms, diagnosis, and treatment of neurocysticercosis. *Lancet Neurol* 2014; 13: 1202–1215.
76. World Health Organization. *Breastfeeding and Maternal Medication. Recommendations for Drugs in the Eleventh WHO Model List of Essential Drugs*, 2002.
77. Cruz M, Davis A, Dixon H, Pawlowski ZS, Proano J. Operational studies on the control of *Taenia solium* taeniasis/cysticercosis in Ecuador. *Bull World Health Organ* 1989; 67: 401–407.
78. Bustos JA, Rodriguez S, Jimenez JA *et al.* Detection of *Taenia solium* taeniasis coproantigen is an early indicator of treatment failure for taeniasis. *Clin Vaccine Immunol* 2012; 19: 570–573.

Appendix I

Algorithm: Screening for unrecognised symptomatic cysticercosis



L. Zammarchi *et al.* **COHEMI recommendations on neurocysticercosis**

ABZ, albendazole; PZQ, praziquantel; MRI, magnetic resonance imaging; CT, computed tomography.

*This category of subjects is not at increased risk of cysticercosis, but is at risk of having an adverse reaction (i.e. seizures) after receiving treatment with albendazole or praziquantel in case of unrecognised cysticercosis.

#Brain MRI and CT scan are both useful to detect neurocysticercosis as MRI has a higher sensitivity to detect viable extraparenchymal neurocysticercosis, while CT scan has a better performance in detecting calcifications [26, 75].

Corresponding Author Alessandro Bartoloni, Unità di Malattie Infettive, Dipartimento di Medicina Sperimentale e Clinica, Università Degli Studi di Firenze, Largo Brambilla 3, 50134 Florence, Italy. Tel.: +39 0557949431; E-mail: alessandro.bartoloni@unifi.it