

Available online at www.sciencedirect.com

ScienceDirect

journal homepage: <http://www.elsevier.com/locate/pjnns>

Case report

Hypoglossal nerve paralysis in a child after a dental procedure

Simona D. Marino^a, Laura Schiavone^a, Flavia M.C. La Mendola^a,
Tiziana Timpanaro^a, Maria Elena Cucuzza^a, Filippo Greco^a,
Pierluigi Smilari^a, Agata Fiumara^a, Andrea Domenico Praticò^{a,b,*}

^a Section of Pediatrics and Child Neuropsychiatry, Department of Clinical and Experimental Medicine, University of Catania, Catania, Italy

^b Maurice Wohl Clinical Neuroscience Institute, King's College London, London, UK

ARTICLE INFO

Article history:

Received 5 July 2017

Accepted 27 January 2018

Available online 6 February 2018

Keywords:

Hypoglossal palsy

Orthodontic procedures

Seddon/Sunderland classification

ABSTRACT

Unilateral palsy of the hypoglossal nerve is a rare complication of orthodontic procedures. The main reported causes of HNP are: orthopedic and otorhinolaryngology surgical interventions, and in particular maneuvers involving compression or overstretching of the hypoglossal nerve, dental procedures and traumas, and also infections, motoneuron disorders, tumors, vascular diseases. Diagnosis is usually performed by electrophysiology studies (EMG-VCN), and brain magnetic resonance imaging (MRI) is useful to exclude other causes. The prognosis depends on the location and extension of the damage. Currently there is not a standardized treatment approach except the speech therapy, although, in some cases, the high-dose steroid treatment could be useful. We describe the case of a ten-year-old female, who was admitted in our Unit after a deviation of the tongue associated with dysarthria and dysphagia, occurred after the application of a mobile orthodontic device.

© 2018 Polish Neurological Society. Published by Elsevier Sp. z o.o. All rights reserved.

1. Introduction

The hypoglossal nerve (Cranial Nerve XII) innervates the intrinsic and extrinsic muscles of the tongue, and is a pure motor nerve. It has both bulbar and spinal origin; nerve fibers originate from the medulla oblongata, and C1 fibers join the nerve as it exits the skull. The cervical root fibers innervate the strap muscles of the neck. Supranuclear fibers originate from the contra-lateral primary motor cortex. Both genioglossus

muscles must be innervated and properly functioning to protrude the tongue in the midline [1] (Fig. 1).

When monolateral, hypoglossal nerve palsy (HNP) is usually caused by intracranial or extracranial space occupying lesions, surgical or anesthesiology procedures, infections (dengue, poliomyelitis), motoneuron disorders, trauma, head and neck injuries, vascular anomalies, neuropathy or autoimmune diseases [2]. More rarely it can be idiopathic.

The anatomical location of the lesion is usually related to a different clinical presentation: (a) supranuclear lesions cause tongue deviation opposite to nerve lesion. There is not atrophy

* Corresponding author at: Section of Pediatrics and Child Neuropsychiatry, Department of Clinical and Experimental Medicine, University of Catania, via Santa Sofia 78, 95123 Catania, Italy.

E-mail address: terrenere178@alice.it (A.D. Praticò).

<https://doi.org/10.1016/j.pjnns.2018.01.006>

0028-3843/© 2018 Polish Neurological Society. Published by Elsevier Sp. z o.o. All rights reserved.

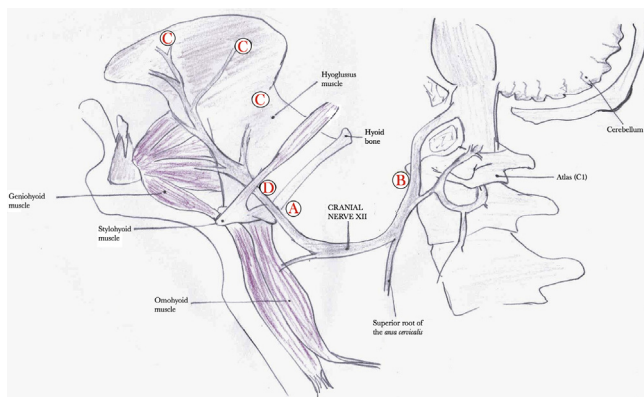


Fig. 1 – Anatomic locations of hypoglossal nerve injury: (A) Nerve compression or impingement (B) Nerve stretching (C) Pressure of the distal nerve fibers (D) Calcified stylohyoid ligament.

or fasciculation of the tongue and vascular disease is often the main cause; (b) nuclear or intranuclear lesions (unilateral or bilateral) cause a lower motor neuron dysfunction ipsilateral to the lesion, with fasciculation and atrophy: it is mainly caused by tumors and neurodegenerative diseases; (c) isolated lesions of nerve during its course cause ipsilateral deviation of tongue, and are sometime associated other cranial nerves (IX, X, XI) involvement. It is generally caused by trauma or expansive or compressive lesions [1,3].

2. Case report

We report a case of unilateral palsy of hypoglossal nerve in a 10-year-old aged female, admitted at our Unit. The patient, in full-health and not submitted to any treatment, presented a deviation of the tongue toward left (Fig. 2), associated with atypical swallowing and slurred speech, which had occurred for one year, after the insertion of a mobile orthodontic device. These symptoms still persisted during admission, after orthosis removal. At a phoniatric counseling, tongue deviation, fasciculation, atypical swallowing and dyspraxia were observed, without muscle atrophy. Speech therapy was therefore initiated but without benefit. At physical examination, adeno-tonsillar hypertrophy was observed, and, beside the tongue deviation, the neurological exam was normal. Routine laboratory exams (blood count, inflammatory markers, liver and kidney function, anti-streptolysin titer, thyroid hormones, EBV, CMV, Toxoplasma) were normal.

The electromyography (EMG) of the genioglossus muscles and the nerve conduction velocity (NCV) of hypoglossal nerves showed a motor axonal neuropathy of the left hypoglossal nerve. In particular, at EMG, a spontaneous activity and positive sharp waves were noticed only in the left genioglossus muscle. At a maximum contraction, the recruitment pattern of the same muscle was markedly reduced. The NCV of the right hypoglossal nerve showed normal distal latency (1.9 milliseconds), and a normal amplitude after mandibular-angle stimulation (2 mV). In the left nerve, latency was normal (1.7 ms), while the amplitude after mandibular-angle stimulation was reduced [0.1 mV (–95%)].

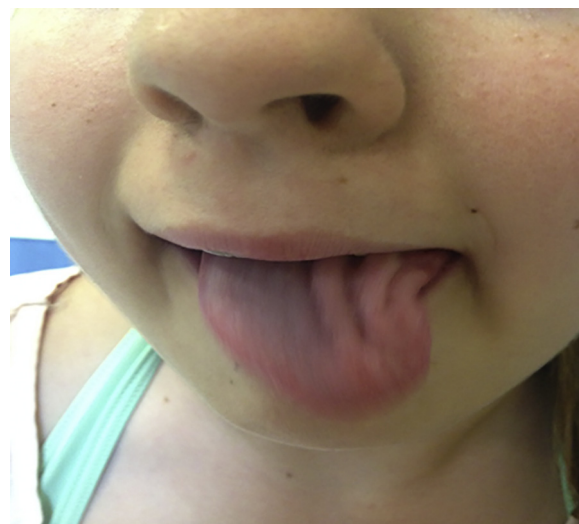

Fig. 2 – The present patient, at admission (10 years of age). The tongue is markedly deviated to the left as a consequence of left HNP.

At brain MRI, an asymmetry of the size of the vertebral arteries (left larger than right) was observed; the left hypoglossal nerve ran posteriorly to the left vertebral artery, and there were not any pathologic impregnation areas after CM. In order to exclude a neurovascular conflict, MRI was performed including cervical spine with vascular sequences, with normal results; moreover, a reduction of volume and a reduced enhancement after contrast of the left side of the tongue was observed.

After a 1-year speech therapy, the left-deviation of the tongue was reduced, even if the tongue, in its left side, appears to be still partially contracted (Fig. 3). The patient can speak properly and has not present anymore difficulties in swallowing. A new EMG of the muscle has showed a marked improvement of EMG (increase in recruitment pattern of the genioglossus muscle) and NCV of the left hypoglossal nerve, whose amplitude potential after mandibular angle stimulation had increased to 1.2 mV.

3. Discussion

The patient was admitted to our Unit for a left-deviation of the tongue, associated to atypical swallowing and slurred speech. Her medical history revealed an orthodontic appliance about 12 months before and her clinical symptoms had their onset few days after this procedure, without history of trauma nor signs of other neurological disorders. In the first months, the girl's symptoms had been overlooked, as it was thought that the fasciculation were a normal effect of the orthosis.

At admission, the general and neurological conditions and laboratory examinations were normal, thus an isolated lesion of the hypoglossal nerve was suspected. EMG – VCN confirmed a motor axonal neuropathy and a brain MRI with vascular sequences excluded intracranial masses, vascular disease or trauma.

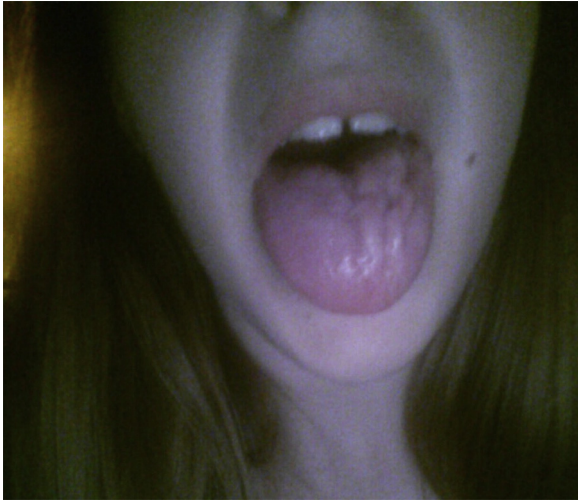


Fig. 3 – The patient, at 11 years of age. The tongue is not deviated, but it presents a corrugated aspect in the left side.

The HNP is a complication observed after orthopedic and otorhinolaryngoiatric interventions (septo and/or rhinoplasty) [2], but it can be also caused by maneuvers causing compression or overstretching of the nerve, such as tracheal intubation [2,4,5], post-operative complications, dental procedures (extraction of third molar) [6,7], and trauma of the jaw or the cervical spinal region (occipital condyle fracture) [8]. Other causes include: infections (dengue, poliomyelitis), endocrine or autoimmune diseases, motoneuron disorders, tumors, vascular disease (ischemic or hemorrhagic brainstem stroke, aneurysm of the carotid artery, vascular malformations of vertebral or basilar artery) [9], neurinomas or schwannomas of the hypoglossal nerve.

Four different mechanisms of injury causing unilateral paralysis of the XII are known (Fig. 1) [4]:

1. nerve compression or impingement can occur at the hyoid bone where the nerve is relatively superficial in its course;
2. nerve stretching can occur at the lateral aspect of the transverse process of the first cervical vertebrae (C1);
3. pressure exerted by the laryngoscope blade can lead to lateral retraction and shearing of the distal nerve fibers that supply motor input to the tongue;
4. a calcified stylo-hyoid ligament has also been reported in association with hypoglossal nerve impingement.

In our patient, HNP was due to iatrogenic damage during orthodontic surgery and, given the results of the EMG, NCV and MRI, corresponded to the stage II of the five-degree classification of peripheral nerve injury by Sunderland [10]. The first degree corresponds to neurapraxia and the second degree to axonotmesis. The third, fourth, and fifth degrees involve injury to endoneurial tubes, perineurium, and epineurium, respectively.

Other similar clinical cases due to dental procedures have been so far described [6,7], and XII nerve paralysis has been associated with a damage of the lingual nerve, causing both deficiency in motor and sensitive functions. In such cases, a

deep clinical evaluation is sufficient to predict the location of neuronal damage (i.e. supranuclear, nuclear or peripheral) [3]. In order to exclude tumor and/or vascular diseases, a brain MRI is usually performed. Other useful data can be drawn by EMG-VCN; however this exam cannot differentiate fourth-degree injury from fifth-degree injury [10].

In affected patients, prognosis is usually good: signs and symptoms are self-limited, with resolution occurring within 2 months in 50% of patients, and 80% resolving by 4 months [4]. Currently there is no standardized treatment, with the exception of speech therapy, which has shown appreciable results in most of the studies [3]. In some cases, high-dose steroid treatment [11] can reduce the swelling and inflammation of the tissues, especially in post-traumatic cases. In the present case, speech therapy has been performed for one year, with noticeable results in term of expressive speech ability and improvements in swallowing. Nevertheless, the tongue still appears contracted in its left side, with an asymmetrical tone that can be noticed only when the tongue is protruded outside of the mouth.

Consent

A written consent was obtained by the parents for the publication of this case report.

Conflict of interest

None declared.

Acknowledgement and financial support

None declared.

REFERENCES

- [1] Weissman O, Weissman O, Farber N, Berger E, Grabov Nardini G, Zilinsky I, et al. Hypoglossal nerve paralysis in a burn patient following mechanical ventilation. *Ann Burns Fire Disasters* 2013;26:86–9.
- [2] Ulusoy H, Besir A, Cekic B, Kosucu M, Gezelya S. Transient unilateral combined paresis of the hypoglossal nerve and lingual nerve following intubation anesthesia. *Rev Bras Anesthesiol* 2014;64:124–7.
- [3] Thompson EO, Smoker WR. Hypoglossal nerve palsy: a segmental approach. *Radiographics* 1994;14:939–58.
- [4] Shah AC, Barnes C, Spiekerman CF, Bollag LA. Hypoglossal nerve palsy after airway management for general anesthesia: an analysis of 69 patients. *Anesth Analg* 2015;120:105–20.
- [5] Lopes G, Denoel C, Desuter G, Docquier MA. Two cases of isolated unilateral paralysis of hypoglossal nerve after uncomplicated orotracheal intubation. *Acta Anaesthesiol Belg* 2009;60:191–3.
- [6] Stankiewicz JA, Pazevic JP. Hypoglossal nerve palsy after tooth extraction. *J Oral Maxillofac Surg* 1988;46:18–149.
- [7] Durrani F, Singh R. Isolated hypoglossal nerve palsy due to infected impacted tooth. *Case Rep Med* 2009;2009:231947.

-
- [8] Castling B, Hicks K. Traumatic isolated unilateral hypoglossal nerve palsy: case report and review of the literature. *Br J Oral Maxillofac Surg* 1995;33:171-3.
- [9] Graham RM, Thomson EF, Baldwin AJ. Isolated hypoglossal nerve palsy due to a vascular anomaly. *Int J Oral Maxillofac Surg* 2007;36:759-61.
- [10] Sunderland S. A classification of peripheral nerve injuries producing loss of function. *Brain* 1951;74:491-516.
- [11] Lagalla G, Logullo F, Di Bella P, Provinciali L, Ceravolo MG. Influence of early high-dose steroid treatment on Bell's palsy evolution. *Neurol Sci* 2002;23:107-12.