

# Ductopenia and fetal liver-like architecture as unique and evocative sign of Turner syndrome

P. VALENTINI, D.F. ANGELONE\*, A. ROSSODIVITA, P. FRANCALANCI\*\*,  
D. BUONSENSO, M. CECCARELLI, F. CALLEA\*\*

Department of Pediatrics, School of Medicine, Catholic University of the Sacred Heart, Rome, Italy

\*Department of Pediatrics, School of Medicine, Sapienza University, Rome, Italy

\*\*Pathology Department, Bambino Gesù Hospital, Rome, Italy

**Abstract. – BACKGROUND:** Turner syndrome is the most common genetic disorder in females. In most subjects, with a normal physical appearance at birth, the diagnosis is suspected long after birth because of short stature, delayed puberty, primary or secondary amenorrhea or infertility. Abnormalities of liver function tests are reported in literature, with a prevalence ranging from 20% to 80%. In most subjects liver diseases are self-limiting, associated with obesity, hormonal therapy and autoimmune diseases. An association between Turner syndrome and cryptogenic liver disease has been reported.

Abnormalities of liver function tests could be the unique sign of Turner syndrome in subjects with normal phenotypes. The histological picture of “fetal liver-like architecture” and “ductopenia” is of fundamental importance for the diagnosis of chromosomopathy.

**AIM:** Review the causes of hypertransaminasemia by focusing on more rare as metabolic and genetic diseases.

**MATERIALS AND METHODS:** We evaluated a 10 year old girl with a normal phenotype affected by chronic hypertransaminasemia and cholestasis, in whom a needle liver biopsy was performed after the most common causes of hypertransaminasemia were excluded.

**RESULTS:** Liver histological evaluation revealed a smoldering colangiopathy with mild ductopenia and a fetal liver-like architecture. Turner syndrome, suspected on the basis of this histological picture, was confirmed by a pelvic ultrasound and a chromosome analysis.

**CONCLUSIONS:** The histological features of “fetal liver-like architecture” and “ductopenia” represent an evocative sign that could indicate the diagnostic suspicion of Turner syndrome in a subject lacking in signs or symptoms of this disease. It is important to perform a pelvic ultrasound and an endocrinological evaluation in all females with chronic asymptomatic hypertransaminasemia even though they have normal phenotypes.

*Key Words:*

Turner syndrome, Hypertransaminasemia, Ductopenia.

## Introduction

The widespread use of routine laboratory tests in periodic health screenings, blood donors' check-ups and before surgery has recently resulted in an increased incidental findings of hypertransaminasemia. The prevalence of increased aminotransferase levels differs depending on the population studied, and among asymptomatic adults ranges from 0.4% to 11.3%<sup>1-3</sup>.

Aspartate aminotransferase (AST) and alanine aminotransferase (ALT) are intracellular enzymes that are expressed in different tissues, in the following decreasing order of activity: liver, heart, muscle, kidneys, brain, pancreas, lungs, leukocytes and erythrocytes. Due to their great activity in the liver, aminotransferases are sensitive indicators of liver-cell injury and hepatocellular disease<sup>1,4</sup> or may reveal the presence of transient and benign diseases<sup>2</sup>.

In children, hypertransaminasemia can be the first manifestation of non-hepatic diseases, such as cystic fibrosis, celiac disease (9% of patients with chronic unexplained hypertransaminasemia)<sup>5</sup> and muscular dystrophy. It can be the first manifestation of inborn errors of metabolism, or can be bound to a non-pathological profile (i.e., MacroAST)<sup>6</sup>. Iorio et al<sup>2</sup> demonstrated a high percentage of genetic disorders (Wilson disease, muscular dystrophy, Alagille syndrome,  $\alpha$ 1-antitrypsin deficiency, Shwachman' syndrome and hemochromatosis) in children with isolated hypertransaminasemia and without typical signs of the disease.

Guidelines have been developed to provide a rational approach to the interpretation of transaminase elevation both in symptomatic and asymptomatic subjects<sup>1,7</sup>.

## Case Report

A 10 year old female was admitted to our Pediatric Infectious Diseases Unit because of hypertransaminasemia discovered 3 years earlier.

Her past medical history was unremarkable. Her vaccination status was up to date. She had never received blood transfusions. There was no family history of liver diseases. Her family history was positive for maternal delayed menarche.

At a first evaluation, a physical examination revealed a weight of 36 kg (75<sup>th</sup> percentile, according to Tanner-Whitehouse growth charts) and a height of 130 cm (3<sup>rd</sup> percentile)<sup>8</sup>. Her target height (TH) was 158.7 cm (28<sup>th</sup> percentile) (Figure 1).

She showed a normal female phenotype except for a mild cubitus valgus (Figure 2).

Laboratory investigations included: haemoglobin of 14.2 g/dl (normal range 11.5-14.5); a white blood cell count (WBC) of  $8.6 \times 10^3/\text{mm}^3$  (normal range 4.5-13.5); a normal WBC differential count; and a platelet count of  $445 \times 10^3/\text{mm}^3$  (normal range 250-550). Her clotting tests were normal.

A liver function evaluation showed: serum AST levels of 103 UI/l (normal range 7-45); serum ALT levels of 236 UI/l (normal range 7-45);  $\gamma$ -glutamyl transpeptidase ( $\gamma$ -GT) levels of 147 UI/l (normal range 2-25); alkaline phosphatase levels of 750 UI/l (normal value < 1000 UI/l); total bilirubin levels of 0.4 mg/dl (normal range 0.3-1.2); and direct bilirubin levels of 0.1 mg/dl (normal range 0.1-0.3).

Appropriate laboratory investigations were performed to rule out the most common causes of hypertransaminasemia.

Serological studies for the hepatotropic virus showed the presence of immunity to hepatitis B (anti-surface and core antigen antibodies positive, core antibodies IgM negative; surface antigen and HBV-DNA negative). Hepatitis C antibodies and RNA, delta hepatitis antibodies, HIV antibodies and hepatitis G virus RNA were all negative.

Serum ammoniemia, pyruvic and lactic acid, ( $\alpha$ -fetoprotein), ceruloplasmin, copper, iron, ferritin, uroporphyrin,  $\alpha_1$ -antitrypsin, complement, circulating immunocomplexes and autoantibody levels (antigliadin IgG and IgA, anti-endomysium, anti-transglutaminase, anti-nuclear, anti-smooth muscle cell, anti-mitochondrial, anti-liver-kidney-microsome, perinuclear and circulating anti-neutrophil cytoplasmic, anti-cardiolipin, anti-thyroglobulin and anti-extractable nuclear antigen) were all within the normal range. A sweat test result for cystic fibrosis was negative. The most common inborn errors of glucose and aminoacid metabolism associated with hypertransaminasemia were excluded.

Our patient remained in good clinical condition, with a normal neurological and cognitive development. Her statural growth remained be-

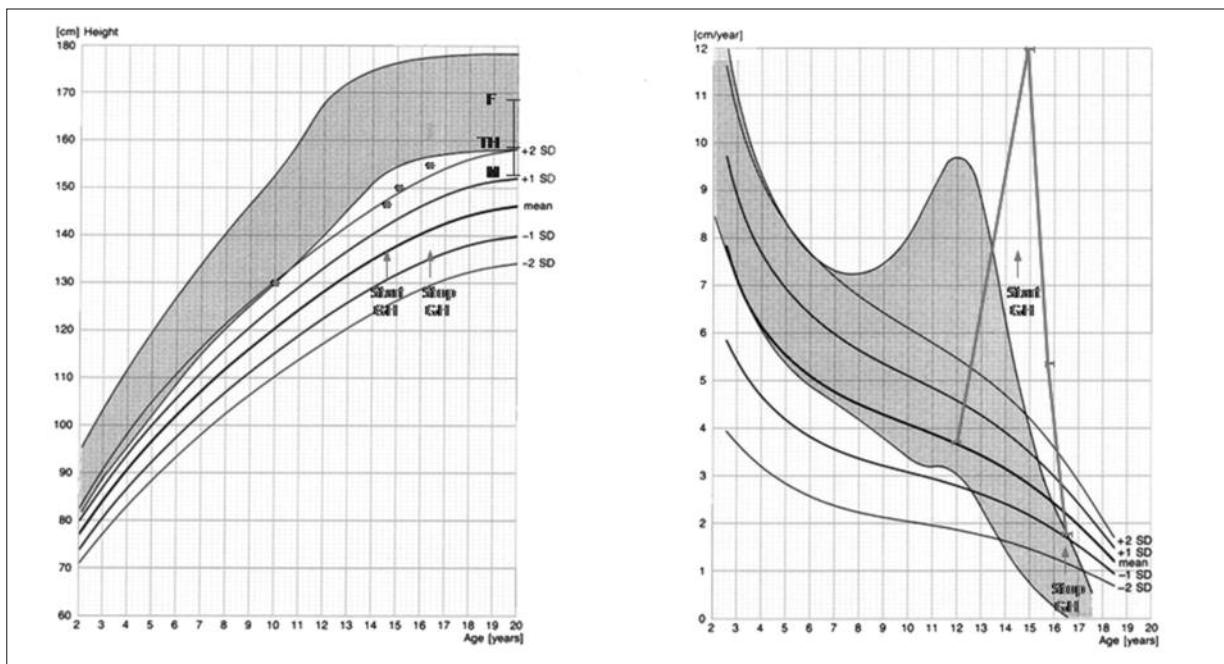
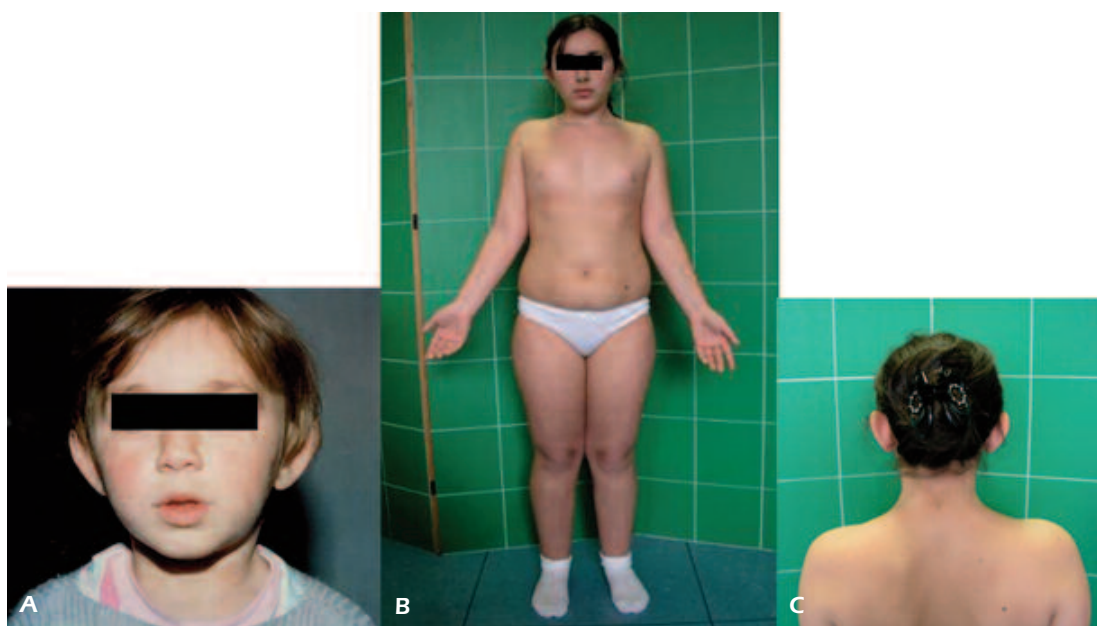

Figure 1. Height and velocity growth charts. (Ranke MB. Eur J Pediatr 1983;141: 81-88).



**Figure 2.** Patient's phenotype at 4 (A) and 14 (B-C) years of age.

tween the limits of genetic targets (Figure 1). Her liver function tests were evaluated every six months. Periodical ultrasound study of the liver and the echo-Doppler of the portal vein never revealed structural anomalies or parenchymal focal lesions nor abnormalities of the blood flow.

When she was 14 years old, because of persistent liver tests abnormality (AST 2-8 $\times$ , ALT 2-8 $\times$ ,  $\gamma$ -GT 3-8 $\times$ ), she underwent a needle liver biopsy. Specimens were fixed in formalin and stained with Hematoxylin-Eosin, PAS, PAS after diastase, Masson trichrome, Perls and Cytokeratin 7.

The histological evaluation revealed a smoldering colangiopathy with moderate ductopenia, and a fetal liver-like architecture (hepatocytes arranged in a mosaic pattern with macrotrabecular or pseudorosette arrangements). In particular, it revealed a paucity of small interlobular bile ducts in the absence of histological changes, suggesting the mechanisms causing ductopenia. Cholangiolitis and mild inflammatory infiltrates were present in a few portal spaces (Figures 3 and 4).

On the basis of this histological picture, with a suspicion of Turner syndrome, a pelvic ultrasound was performed. It showed "streak gonads" and a small, tubular-shaped uterus (volume 1.4 ml) with prepubertal morphology and a not recognizable endometrial echo.

Based on a 50 lymphocyte karyotype, the chromosome analysis documented a mosaicism [45,X0/46,X,i(Xq)] with a monosomic cell line

in 80% of analyzed cells and an isochromosome X in the other 20%, resulting from duplication of the long arm and loss of the short arm. Her parents' chromosome analyses were normal.

Associated congenital cardiac or renal anomalies and autoimmune disorders were excluded. A hearing examination was normal.

The girl was referred to the pediatric endocrinologist, who confirmed primary amenorrhea and short stature.

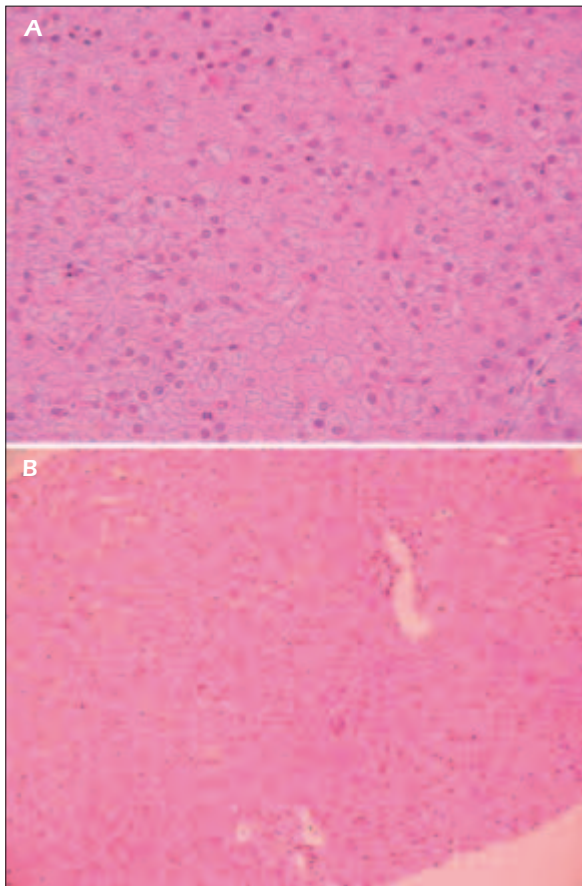
Her standing height was 146.3 cm, below the target height (+ 1.6 SDS for Turner's standards) (Figure 1). The ratio of sitting to standing height was increased (1.14). Her weight was 52.5 kg; BMI 24.5.

At that time she had no pubertal signs but normal pubarche (Stage P3, according to Tanner and Marshall)<sup>9</sup>.

Measurement of serum gonadotropin and estrogen levels confirmed the ovarian hypergonadotropic dysfunction (basal FSH levels of 141 MUI/ml, basal LH levels of 34.3 MUI/ml).

Thyroid function was normal and thyroid autoimmunity was negative. An oral glucose tolerance test (OGTT) showed normal glucose tolerance as well as normal fasting and stimulated insulin plasma levels.

After discussing growth hormone therapy with the parents and patient, including its efficacy and side effects, since her epiphysis were not still completely fused, the girl started on recombinant



**Figure 3.** *A*, Parenchyma with hepatocytes arranged in a mosaic pattern with macrotrabecular disposition. This pattern is suggestive of fetal architecture (Hematoxylin-Eosin; magnification 20 ×). *B*, Normal liver histology with two portal spaces containing both artery and vein but lacking in bile duct (Hematoxylin-Eosin; magnification 10 ×).

human growth hormone (rhGH) treatment at a daily dose of 50 µg/kg, to promote residual statural growth.

Her height velocity significantly improved in the absence of side effects: growth velocity reached 12 cm/year after 6 months and 5.4 cm/year after the first year of therapy (Figure 1).

Moreover, ursodeoxycholic acid therapy was started (15 mg/kg/die).

Aminotransferase and  $\gamma$ -GT levels normalized in a year of therapy (AST 34 UI/l, ALT 43 UI/l,  $\gamma$ -GT 43 UI/l).

Estrogens therapy was deferred until the age of 16 with the aim of achieving the maximal height gain with rhGH. Low dose transdermal estradiol was preferred since with this approach the natural estradiol reaches the systemic circulation directly without first undergoing metabolism by the intestine and liver. The patient gradually

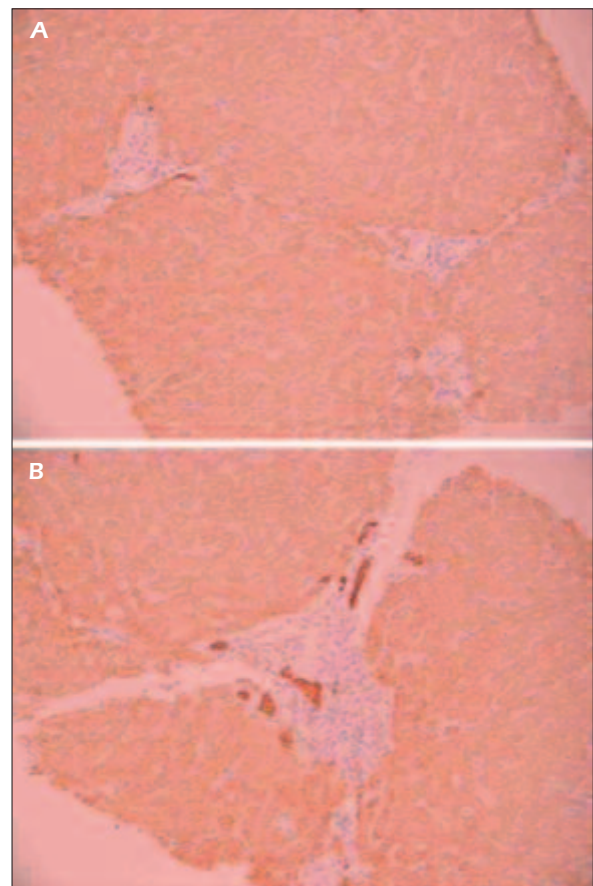
developed secondary sexual characteristics and attained a final height of nearly 155 cm (in the range of TH). She stopped rhGH at the age of 16 and a half when her growth rate fell below 1.8 cm/year (Figure 1).

During treatment, carbohydrate tolerance and fasting insulin levels were normal.

## Discussion

Turner syndrome is the most common genetic disorder in females; it occurs in approximately one in 2500 female live births<sup>10-12</sup>. It is associated with a cell line with only a single normal X chromosome; the other sex chromosome is either missing or structurally abnormal<sup>13</sup>.

The phenotypic expression can be extremely varied. Almost 15% of patients present a typical phenotype from birth. Most subjects, in particu-



**Figure 4.** *A*, Three minor portal spaces lacking in interlobular bile ducts, ductopenia. *B*, Major portal spaces with no alteration of number or structure of bile ducts. (Cytochrome 7; magnification 10 ×).

lar those with mosaicism or anomalies of an X-chromosome, have a normal physical appearance. In these cases the diagnosis is suspected long after birth because of short stature, delayed puberty, primary or secondary amenorrhea in adolescence or infertility in adulthood<sup>10</sup>.

The standard care for children with Turner syndrome includes rhGH and estrogen therapy.

Associated endocrine, renal and cardiovascular anomalies are common. The prevalence of cardiovascular abnormalities (bicuspid aortic valve and coarctation of the aorta) varies between 20% and 40%; it is higher in patients with monosomy X<sup>13</sup>.

Abnormalities of liver function tests in patients with Turner syndrome are reported in literature, even in the absence of the signs and symptoms of liver disease. The prevalence of these abnormalities ranges from 23% to 28% in young patients<sup>14,15</sup> and reaches 80% in middle-aged women<sup>16,17</sup>.

In most cases, liver disease is self-limiting, associated with obesity<sup>18</sup>, even in pediatric age<sup>19,20</sup>, or hormonal therapy, more often in patients treated with estrogens than in those treated with rhGH. Hepatic function normalizes with loss of weight or after the interruption of treatment.

Several studies have demonstrated the absence of a correlation between hepatic abnormalities and estrogen therapy<sup>15</sup>, but an improvement in liver function in Turner patients during estrogen replacement therapy, may be due to a protective hormonal effect on hepatocyte integrity<sup>17,19,21</sup>.

In some cases, the liver involvement is related to autoimmune diseases, such as celiac disease, primary biliary cirrhosis (PBC), primary sclerosing cholangitis and autoimmune hepatitis<sup>14,19,20</sup>.

Moreover, an association between Turner syndrome and “cryptogenic hepatopathy”, often associated with cholestasis, has been reported in literature<sup>12,22</sup>, with a varied prognosis ranging from mild liver tests abnormalities with benign and self-limiting course<sup>14,15</sup>, not associated with histopathological progression<sup>11</sup>, to chronic asymptomatic cholestasis<sup>23,24</sup> up to a possible evolution to cirrhosis<sup>25</sup>.

The liver histological pictures described in Turner syndrome include minimal abnormalities<sup>24</sup>, steatosis and steatohepatitis<sup>11,14</sup>, biliary involvement as primary sclerosing cholangitis<sup>23,26</sup>, cirrhosis<sup>25</sup>, nodular regenerative hyperplasia and portal hypertension<sup>27,28</sup>.

In a recent study, including the most numerous series of liver biopsies in Turner patients, Roulot et al<sup>18</sup> described hepatic histological features of liver involvement in this syndrome; they ascribed

the main causes of liver involvement to congenital vascular disorders, biliary lesions and nonalcoholic fatty liver disease linked to metabolic disease. In 27 liver specimens the features described were: architectural changes associated with vascular abnormalities; portal and periductal fibrosis; inflammatory infiltrates; nonalcoholic fatty liver disease; small duct sclerosing cholangitis; and ductopenia, defined as the absence of bile ductules in more than 50% of the portal spaces. They did not find signs of liver toxicity caused by estrogen therapy.

Our patient showed ductopenia and a fetal liver-like architecture at the liver biopsy. She had a history of prior hepatitis B. However, the patient presented signs of seroconversion, negative HBV-DNA and lack of histological signs of chronic hepatitis, such as portal inflammation associated with interface hepatitis, and variable degrees of lobular changes<sup>29</sup>.

Paucity of interlobular bile ducts, or ductopenia, defined as a reduced ratio of the number of interlobular ducts to the number of portal tracts, may be “*syndromic*”, when associated with other anomalies, or “*non syndromic*”, when associated with infections (cytomegalovirus, rubella, hepatitis B, syphilis),  $\alpha_1$ -antitrypsin deficiency, endocrine disorders (hypopituitarism), chromosomal anomalies (Trisomy 21, Turner syndrome), altered bile acid metabolism and mucoviscidosis<sup>30</sup>.

Congenital diseases of intrahepatic bile ducts are related to a persistent or lack of remodeling of the embryonic ductal plate. This abnormality has been termed “ductal plate malformation”<sup>30</sup>.

Ulissi and Ricci<sup>31</sup> in 1989 and Garavelli et al<sup>27</sup> in 1998 described the particular picture of ductopenia and fetal liver-like architecture in two adult patients who underwent a liver biopsy because of a hypertransaminasemia, in one case associated with portal hypertension.

The Authors hypothesized that this kind of architecture was due to an arrested liver development, possibly due to lack of stimulation by sex hormones<sup>17</sup>.

In 1974, Gardner<sup>26</sup> described two pediatric cases of cholestasis associated with ductopenia and bile plugs in the canaliculi at the liver biopsy. He hypothesized that hepatic disorder could be the expression of a mutant allele located on the homologous pairing segment of the X-chromosome. Turner syndrome represents the only clinical state in which the patient could be monosomic for the mutant allele. This hypothesis has been reevaluated, based on the evidence that conditions

associated with X chromosome monosomy or structural abnormalities, such as Turner syndrome, are often associated with autoimmune disorders and chronic cholestasis<sup>32</sup>.

Selmi C et al<sup>32</sup>, studying the etiopathogenetic factors of primary biliary cirrhosis (PBC) and its frequent association with females, suggested that the enhanced monosomy X in lymphocytes could play a role in the induction of PBC, through alteration of the immune response.

Some similarities between Turner syndrome and PBC have been revealed: chronic cholestasis with an incidence increasing with age, association with autoimmune thyroiditis, osteopenia and celiac disease<sup>33</sup>.

Invernizzi et al<sup>34</sup> reported an enhanced monosomy X in the peripheral blood cells of the adaptive immune system of women with PBC, compared to healthy controls and women with chronic hepatitis C. They hypothesized that loss of genes involved in immunological tolerance and located on the X chromosome could predispose the development of autoimmune diseases.

Because of the recent availability of noninvasive diagnostic tests that allow the establishment of a correct diagnosis, the role of histology in the management of patients with chronic aspecific liver tests abnormalities is controversial and the decision to perform a percutaneous liver biopsy needs to be made on an individual basis<sup>1,35</sup>.

Sorbi et al<sup>35</sup> studied 36 asymptomatic patients with chronic hypertransaminasemia and without strong evidence of a particular liver disease who underwent a liver biopsy. The histological picture led to a change in the diagnosis in only 14% of cases.

In our patient, the familiar history of maternal delayed menarche and a growth consistent with parental background for height were compatible with the hypothesis of a "constitutional delay of growth and puberty". However, the peculiar histological features of "fetal liver-like architecture" and "ductopenia" were of basic importance in addressing the diagnostic suspicion of chromosomopathy in a subject with a normal phenotype.

## Conclusions

Other cases reported in literature usually concern adult patients in whom the diagnosis of Turner syndrome precedes that of liver involvement. These studies evaluate the incidence, etiology and outcome of liver disease associated with this chromosomopathy.

On the contrary, in our patient the diagnostic process performed because of the chronic hypertransaminasemia and asymptomatic cholestasis led to the diagnosis of Turner syndrome in a subject until that moment lacking in signs or symptoms characteristic of this disease.

The diagnosis of Turner syndrome before complete conjugation cartilage ossification allowed the starting of rhGH therapy and the obtaining of a significant increase in growth velocity. Moreover, the prompt treatment with ursodeoxycholic acid has been associated with a significant improvement of liver tests, as previously reported in Turner patients<sup>22,23</sup>.

We would underline that the association between Turner syndrome and liver abnormalities could have extremely different expressions, from mild and asymptomatic disease to progression to cirrhosis.

We suggest performing a pelvic ultrasound associated with an endocrinological evaluation in all females with chronic asymptomatic hypertransaminasemia of unknown origin, even with normal phenotypes.

A standard karyotype is to be recommended in the evaluation of all short prepubertal females, to achieve an early diagnosis and to commence rhGH treatment before the age of 6 years.

Surveillance of liver function should be included in the management of Turner patients, both before and after the start of hormonal treatment, to identify the possible progression of liver disease to cirrhosis.

## Acknowledgements

We thank Vanessa Thubron for technical assistance in the manuscript preparation and linguistic revision.

## References

- 1) PRATT DS, MARSHALL M, KAPLAN MD. Evaluation of abnormal liver-enzyme results in asymptomatic patients. *N Engl J Med* 2000; 342: 1266-1271.
- 2) IORIO R, SEPE A, GIANNATTASIO A, CIRILLO F, VEGNENTE A. Hypertransaminasemia in childhood as a marker of genetic liver disorders. *J Gastroenterol* 2005; 40: 820-826.
- 3) CLARK JM, BRANCATI FL, DIEHL AM. The prevalence and etiology of elevated aminotransferase levels in the United States. *Am J Gastroenterol* 2003; 98: 960-967.
- 4) MATSUI A. Hypertransaminasemia: the end of a thread. *J Gastroenterol* 2005; 40: 859-860.

- 5) RUBIO-TAPIA A, MURRAY J. The liver in celiac disease. *Hepatology* 2007; 46: 1650-1658.
- 6) KAMATH BM, DHAWAN A, MIELI-VERGANI G. Raised serum transaminases: not always liver disease. *Arch Dis Child* 2000; 82: 270-271.
- 7) GREEN RM, FLAMM S. AGA technical review on the evaluation of liver chemistry test. *Gastroenterology* 2002; 123: 1367-1384.
- 8) TANNER JM, BUCKLER JM. Revision and update of Tanner-Whitehouse clinical longitudinal charts for height and weight. *Eur J Pediatr* 1997; 156: 248-249.
- 9) MARSHALL WA, TANNER JM. Variations in pattern of pubertal changes in girls. *Arch Dis Child* 1969; 44: 291-303.
- 10) DOSWELL BH, VISOOTSAK J, BRADY AN, GRAHAM JM. Turner syndrome: an update and review for the primary pediatrician. *Clin Pediatr* 2006; 45: 301-313.
- 11) WARDI J, KNOBEL B, SHAHMUROV M, MELAMUD E, AVNI Y, SHIRIN H. Chronic cholestasis associated with Turner's syndrome: 12 years of clinical and histopathological follow-up. *Digestion* 2003; 67: 96-99.
- 12) ELINAV H, ISRAELI E, SHIBOLET O, HERSHKO A, SELA C, MIGDAL A, ILAN Y. Idiopathic liver involvement in Turner syndrome. *Israel Med Assoc J* 2004; 6: 56-57.
- 13) BONDY CA; TURNER SYNDROME CONSENSUS STUDY GROUP. Care of girls and women with Turner Syndrome: a guideline of the Turner Syndrome Study Group. *J Clin Endocrinol Metab* 2007; 92: 10-25.
- 14) SALERNO M, DI MAIO S, GASPARINI N, RIZZO M, FERRI P, VAJRO P. Liver abnormalities in Turner syndrome. *Eur J Pediatr* 1999; 158: 618-623.
- 15) LARIZZA D, LOCATELLI M, VITALI L, VIGANÒ C, CALCATERA V, TINELLI C, SOMMARUGA MG, BOZZINI A, CAMPANI R, SEVERI F. Serum liver enzymes in Turner syndrome. *Eur J Pediatr* 2000; 159: 143-148.
- 16) SYLVÉN L, HAGENFELDT K, BRONDUM-NIELSEN K, VON SCHOULTZ B. Middle-aged women with Turner's syndrome. Medical status, hormonal treatment and social life. *Acta Endocrinol (Copenh)* 1991; 125: 359-365.
- 17) ELSHEIKH M, HODGSON HJ, WASS JA, CONWAY GS. Hormone replacement therapy may improve hepatic function in women with Turner's syndrome. *Clin Endocrinol (Oxf)* 2001; 55: 227-231.
- 18) ROULOT D, DEGOTT C, CHAZOUILLES O, OBERTI F, CALES P, CARBONELL N, BENFERHAT S, BRESSON-HADNI S, VALLA D. Vascular involvement of the liver in Turner's syndrome. *Hepatology* 2004; 9: 239-247.
- 19) KOULOURI O, OSTBERG J, CONWAY GS. Liver dysfunction in Turner's syndrome—prevalence, natural history and effect of exogenous oestrogen. *Clin Endocrinol* 2008; 69: 306-310.
- 20) SATO H, MIYAMOTO S, SASAKI N. Liver abnormality in Turner syndrome. *Eur J Pediatr* 2001; 160: 59.
- 21) GRAVHOLT CH, POULSEN HE, OTT P, CHRISTIANSEN JS, VILSTRUP H. Quantitative liver functions in Turner syndrome with and without hormone replacement therapy. *Eur J Endocrinol* 2007; 156: 679-686.
- 22) ANDRADE RJ, ALCANTARA R, FRAILE JM, LAZO MD, LLAMAS A, CARMONA C, FRANQUELO E. Chronic asymptomatic intrahepatic cholestasis associated with Turner's syndrome. *Gastroenterol Hepatol* 1995; 18: 375-378.
- 23) FLOREANI A, MOLARO M, BARAGIOTTA A, NACCARATO R. Chronic cholestasis associated with Turner's syndrome. *Digestion* 1999; 60: 587-589.
- 24) ALBAREDA MM, GALLEGRO A, ENRIQUEZ J, RODRIGUEZ JL, WEBB SM. Biochemical liver abnormalities in Turner's syndrome. *Eur J Gastroenterol Hepatol* 1999; 11: 1037-1039.
- 25) IDILMAN R, DE MARIA N, COLANTONI A, KUGELMAS M, VAN THIEL DH. Cirrhosis in Turner's syndrome: case report and literature review. *Eur J Gastroenterol Hepatol* 2000; 12: 707-709.
- 26) GARDNER LI. Intrahepatic bile stasis in 45,X Turner's syndrome. *N Engl J Med* 1974; 290: 406.
- 27) GARAVELLI L, DONADIO A, BANCHINI G, FORNACIARI G, PLANCHER AC, FRANCHI F, GARDINI G. Liver abnormalities and portal hypertension in Ullrich-Turner syndrome. *Am J Med Genet* 1998; 80: 180-182.
- 28) THEVENOT T, DHOTE R, TULLIEZ M, BAVEREL F, PERMAL S, RABINEAU D, CHRISTOFOROV B. Turner syndrome and nodular regenerative hyperplasia of the liver. *Ann Méd Interne (Paris)* 1998; 149: 295-296.
- 29) GUIDO M, MANGIA A, FAA G. Chronic viral hepatitis: the histology report. *Dig Liver Dis* 2011; 43(Suppl 4): S331-343.
- 30) DESMET JD. The Cholangiopathies. In: *Liver disease in children*. edn 2. Eds FJ Suchy, RJ Sokol, WF Balistreri. Lippincot Williams & Wilkins, 2001, pp 39-62.
- 31) ULISSI A, RICCI GL. Hepatic histology in a case of Turner's syndrome. *It J Gastroenterol* 1989; 21: 340-341.
- 32) SELMI C, INVERNIZZI P, MIOZZO M, PODDA M, GERSHWIN ME. Primary biliary cirrhosis: does X mark the spot? *Autoimmun Rev* 2004; 3: 493-499.
- 33) MILKIEWICZ P, HEATHCOTE J. Can Turner syndrome teach us about the pathogenesis of chronic cholestasis? *Hepatology* 2004; 40: 1226-1228.
- 34) INVERNIZZI P, MIOZZO M, BATTEZZATI PM, BIANCHI I, GRATI FR, SIMONI G, SELMI C, WATNIK M, GERSHWIN ME, PODDA M. Frequency of monosomy X in women with primary biliary cirrhosis. *Lancet* 2004; 363: 533-534.
- 35) SORBI D, MCGILL DB, THISTLE JL, THERNEAU TM, HENRY J, LINDOR KD. An assessment of the role of liver biopsies in asymptomatic patients with chronic liver test abnormalities. *Am J Gastroenterol* 2000; 95: 3206-3210.