

Achilles tendon ultrasonography in familial hypercholesterolemia: A sub-study of the Lipid transPort disorders Italian GENetic Network (LIPIGEN)

Dear Editor,

Familial hypercholesterolemia (FH) is a common genetic disease due to mutations causing lifelong exposure to elevated low-density lipoprotein cholesterol (LDL-C) levels, a causal factor for premature occurrence of atherosclerotic cardiovascular disease (ASCVD) [1, 2]. The clinical diagnosis of FH principally relies on clinical algorithms, such as the Dutch Lipid Clinic Network (DLCN) criteria (considering personal and family history of high LDL-C, premature ASCVD, premature corneal arcus, and tendon xanthomata) and can be confirmed by genetic testing [3]. However, DLCN diagnostic performance is far from optimal [4], with the physical analysis of Achilles tendon xanthomata representing a critical point [5], not only because of the interoperator variability [6], but also because xanthomata are not always easily detectable. Achilles tendon ultrasonography represents a safe, reproducible, and inexpensive alternative technique [7] that allows physicians to identify either focal lesions or diffuse changes in tendon echotexture and to measure calcaneal tendon thickness [8]. Here we aimed to evaluate the ability of Achilles tendon ultrasonography in the clinical and genetic classification of subjects with FH, taking advantage of data from five centers belonging to the established Lipid transPort disorders Italian GENetic Network (LIPIGEN [9], see Supplementary Material for all methodological information).

We evaluated 769 adults with a clinical diagnosis of FH. Seventy-five subjects (9.8%) presented with clinically detected xanthomata, and 255 subjects (33.2%) presented with xanthomata detected by ultrasound analysis. Therefore, 180 subjects presented with xanthomata only detected by ultrasound that could not have been identified by clinical examination (Table S1). This latter group showed pretreatment LDL-C levels lower than those of subjects with clinically detected xanthomata (300.5 ± 78.5 vs 347.6 ± 85.3 mg/dL, $p < 0.0001$) but significantly higher than those

of subjects without xanthomata (254.4 ± 63.4 mg/dL, $p < 0.0001$), and lower prevalence of early cardiovascular events than that of subjects with clinically detected xanthomata (13.3% vs 24.0%, $p = 0.04$) but higher compared to subjects without xanthomata (13.3% vs 7.8%, $p < 0.0001$).

Considering xanthomata detected by ultrasound analysis instead of clinically detected xanthomata in the DLCN score calculation, the performance of the DLCN score increased from 61.8% to 65.7% with the cut-off at 6 points (probable diagnosis), and from 32.5% to 43.2% with the cut-off at 9 points (definite diagnosis) (Fig. 1). Among definite FH subjects, the prevalence of clinically detected xanthomata and of xanthomata detected by ultrasound analysis was 30.0% and 67.6%, respectively.

The ultrasound evaluation also showed a higher concordance with the genetic diagnosis; in the whole cohort, the number of subjects with xanthomata and monogenic FH increased from 9.4% to 31.5% using ultrasound instead of clinical detection (Table S2).

Finally, we found that maximum Achilles tendon thickness (higher in subjects with clinically detected xanthomata vs those with xanthomata detected only by ultrasound analysis) positively correlated to the LDL-C burden in subjects with positive genetic diagnoses, but not in those with negative genetic tests (Figure S1, panels A, B, and C). However, the measurement of Achilles tendon thickness demonstrated poor sensitivity both for identifying subjects with clinically defined FH as well as subjects with genetic confirmation of the FH phenotype (Table S3; Figure S2, panels A and B).

In line with previous monocentric studies [10], our findings support that ultrasonography improves the diagnosis of monogenic forms of FH. Therefore, ultrasonography represents an additional opportunity for the physician to detect FH patients when

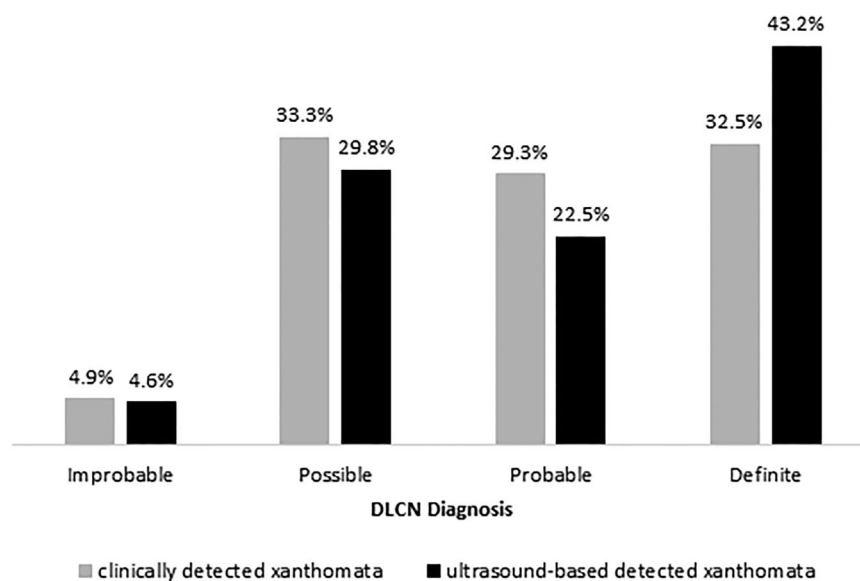


Fig. 1 Reclassification of Dutch Lipid Clinic Network (DLCN) categories by ultrasound-based analysis of Achilles tendon xanthomata.

the genetic test is not available, since the prevalence of xanthomata only detected by ultrasound was significantly higher in FH/M+ versus FH/M-, even stratifying for LDL-C levels (not shown). This finding also supports that ultrasonography could allow for the identification of FH subjects with more severe phenotypes secondary to a lifetime exposure to elevated LDL-C, underscoring the possible prognostic value of this clinical tool. The variability of this technique, however, does not allow for drawing firm indications on the values at which Achilles tendon ultrasonography identifies tendon xanthomata, and limits its universal use for FH diagnosis unless a reference value is established in each center [7]. However, the real-life setting from which we collected data decided to standardize its activity on the grounds that a shared protocol might serve as a proof-of-concept of ultrasound as an additional tool to identify FH patients at higher ACVD risk. The approach will eventually help to increase the sensitivity of physicians, general practitioners, and healthcare providers towards early and effective preventive LDL-C lowering interventions. In conclusion, ultrasonography identifies patients with tendon xanthomata that cannot be detected by physical examination, improving the number of patients correctly identified as definite FH according to the DLCN score and those with proven genetic mutations.

Conflict of interest

The authors do not report any conflict of interest related to this work.

Acknowledgments

The ACTUS-FH LIPIGEN Substudy is part of the LIPIGEN study, an initiative of the SISA Foundation supported by an unconditional research grant from Sanofi. The genetic assessment was performed in collaboration with GenInCode. The work of A. Baragetti is supported by “Cibo, Microbiota, Salute” by “Vini di Batasiolo S.p.A” (AL_RIC19ABARA_01) and “Post-Doctoral Fellowship 2020” by “Fondazione Umberto Veronesi” (2020-3318). The work of M. Casula is supported by Ministry of Health—IRCCS MultiMedica GR-2016-02361198 and Fondazione SISA.

The research is supported by Ministry of Health—Ricerca Corrente—IRCCS MultiMedica (PRIN 2017H5F943 and ERANET ER-2017-2364981). The work is also supported by funding from the Russian Ministry of Science and Higher Education (Agreement No. 075-15-2020-901).

Andrea Baragetti^{1,2} , **Manuela Casula**^{2,3} , **Paolo Scarinzi**⁴, **Federica Ristè**⁵, **Roberto Scicali**⁶, **Marta Biolo**⁴, **Simonetta Lugari**⁷, **Marco Dall'Agata**⁵,

Marta Gazzotti³, Elena Olmastroni³, Asiat S. Alieva^{3,8}, Fabio Nascimbeni⁷ & the ACTUS-FH LIPIGEN Substudy¹

From the ¹Department of Pharmacological and Biomolecular Sciences, University of Milan, Milan, Italy; ²Centre for the Study of Atherosclerosis, Istituto di Ricerca e Cura a Carattere Scientifico (IRCCS) Multimedica Hospital, Sesto San Giovanni, Italy; ³Epidemiology and Preventive Pharmacology Service (SEFAP), Department of Pharmacological and Biomolecular Sciences, University of Milan, Milan, Italy; ⁴U. O. C. Clinica Medica 1, Department of Medicine-DIMED, University of Padua, Padua, Italy; ⁵U. O. Medicina Interna Universitaria, Institute of Internal Medicine, University of Ferrara, Ferrara, Italy; ⁶Department of Clinical and Experimental Medicine, Internal Medicine, University of Catania, Catania, Italy; ⁷Unit of Internal and Metabolic Medicine, Civil Hospital of Baggiovara, A. O. U. of Modena and University of Modena and Reggio Emilia, Modena, Italy; and ⁸Research Laboratory of Lipid Metabolism Disorders and Atherosclerosis, Almazov National Medical Research Centre, St. Petersburg, Russian Federation

References

- Berberich AJ, Hegele RA. The complex molecular genetics of familial hypercholesterolaemia. *Nat Rev Cardiol.* 2019;**16**:9–20.
- Masana L, Zamora A, Plana N, Comas-Cufi M, Garcia-Gil M, Marti-Lluch R, et al. Incidence of cardiovascular disease in patients with familial hypercholesterolemia phenotype: analysis of 5 years follow-up of real-world data from more than 1.5 million patients. *J Clin Med.* 2019;**8**:1080.
- McGowan MP, Hosseini Dehkordi SH, Moriarty PM, Duell PB. Diagnosis and treatment of heterozygous familial hypercholesterolemia. *J Am Heart Assoc.* 2019;**8**:e013225.
- Casula M, Olmastroni E, Pirillo A, Catapano AL, MEMBERS OF THE LIPIGEN STEERING COMMITTEE, PRINCIPAL INVESTIGATORS: Coordinator center, et al. Evaluation of the performance of Dutch Lipid Clinic Network score in an Italian FH population: The LIPIGEN study. *Atherosclerosis.* 2018;**277**:413–8.
- Junyent M, Gilabert R, Zambon D, Núñez I, Vela M, Civeira F, et al. The use of Achilles tendon sonography to distinguish familial hypercholesterolemia from other genetic dyslipidemias. *Arterioscler Thromb Vasc Biol.* 2005;**25**:2203–8.
- Tsouli SG, Kiortsis DN, Argyropoulou MI, Mikhailidis DP, Elisaf MS. Pathogenesis, detection and treatment of Achilles tendon xanthomas. *Eur J Clin Invest.* 2005;**35**:236–44.
- Scott A, Zahradnik TM, Squier K, Beck C, Brunham LR. Diagnostic accuracy of ultrasound and MRI for Achilles tendon xanthoma in people with familial hypercholesterolemia: a systematic review. *J Clin Lipidol.* 2019;**13**:40–8.
- Kutkiene S, Petrulioniene Z, Laucevicius A, Čerkauskienė R, Samuilis A, Augaitienė V, et al. Achilles tendon ultrasonography—a useful screening tool for cardiovascular risk estimation in patients with severe hypercholesterolemia. *Atheroscler Suppl.* 2019;**36**:6–11.
- Averna M, Cefalu AB, Casula M, Noto D, Arca M, Bertolini S, et al. Familial hypercholesterolemia: The Italian Atherosclerosis Society Network (LIPIGEN). *Atheroscler Suppl.* 2017;**29**:11–6.
- Descamps OS, Leysen X, Van Leuven F, Heller FR. The use of Achilles tendon ultrasonography for the diagnosis of familial hypercholesterolemia. *Atherosclerosis.* 2001;**157**:514–8.

Correspondence: Andrea Baragetti, Department of Pharmacological and Biomolecular Sciences, University of Milan, Via G. Balzaretto, 9, 20133, Milan, Italy.
Email: andrea.baragetti@unimi.it
Fabio Nascimbeni, Unit of Internal and Metabolic Medicine, Civil Hospital of Baggiovara, A. O. U. of Modena and University of Modena and Reggio Emilia, Via Giardini 1355, 41126, Modena, Italy.
Email: fabio.nascimbeni@libero.it

Supporting Information

Additional Supporting Information may be found in the online version of this article:

Supporting Information

Supporting Information ■