



ELSEVIER

Contents lists available at ScienceDirect

International Journal of Infectious Diseases

journal homepage: www.elsevier.com/locate/ijid

Case report

SARS-CoV-2's high rate of genetic mutation under immune selective pressure: from oropharyngeal B.1.1.7 to intrapulmonary B.1.533 in a vaccinated patient

Nicolò Musso^{1,*}, Jessica Giuseppina Maugeri², Dafne Bongiorno¹, Stefano Stracquadanio¹, Giovanni Bartoloni³, Stefania Stefani^{1,**}, Emanuela Daniela Di Stefano²¹Laboratory of Molecular and Resistant Antibiotic Medical Microbiology (MMAR), Department of Biomedical and Biotechnological Sciences (BIOMETEC), University of Catania, Catania, Italy²ARNAS Garibaldi Hospital, IC Unit Garibaldi Centro, Catania, Italy³ARNAS Garibaldi Hospital, Pathology Unit, Catania, Italy

ARTICLE INFO

Article history:

Received 4 December 2021

Revised 11 February 2022

Accepted 19 February 2022

Keywords:

COVID-19

Intra-Host Mutations

Post-vaccine

NGS

Lineages

ABSTRACT

This is the case report of an 84-year-old man affected by COVID-19 between the 2 doses of vaccination, with negative *exitus*. We analyzed nasopharyngeal samples of viral RNA collected during the disease and nasopharyngeal and lung samples collected postmortem by reverse transcription LAMP (RT-LAMP) PCR and Next Generation Sequencing (NGS). NGS results were analyzed with different bioinformatic tools to define virus lineages and the related single-nucleotide polymorphisms (SNPs).

Both lung and nasopharyngeal samples tested positive for SARS-CoV-2 on RT-LAMP. Through bioinformatic analysis, 2 viral RNAs from the nasal swabs, which belonged to the B.1.1.7 lineage, and 1 viral RNA from the lung sample, which belonged to the B.1.533 lineage, were identified.

This genetic observation suggested that SARS-CoV-2 tends to change under selective pressure. The high mutation rate of ORF1b, containing a replicase gene, was a biological image of a complex viral survival system.

© 2022 The Authors. Published by Elsevier Ltd on behalf of International Society for Infectious Diseases. This is an open access article under the CC BY-NC-ND license (<http://creativecommons.org/licenses/by-nc-nd/4.0/>)

Introduction

This is the case report of an 84-year-old man with a medical history of chronic kidney disease, dyslipidemia, systemic arterial hypertension, and coronary and peripheral arterial disease, who was admitted to our unit with dyspnoea and suspected COVID-19 disease contracted after partial vaccination (Figure 1A).

Clinical history

On 11 April 2021, the patient received his first COVID-19 vaccine dose (Pfizer mRNA BNT162B2). On around 1 May 2021, he started developing an asymptomatic COVID-19 infection after contact with

relatives. With this being unknown, he received his second vaccine dose. Five days later, a fever appeared.

On 10 May 2021, the patient's condition worsened, and he was transferred to the COVID ED-Hub. Evolution of clinical condition, laboratory results, and therapy at T₀, T₂₄, T₇₂, and T₈₄ are listed in Figure S1. Reverse transcription quantitative PCR (RT-qPCR) gave a positive result, whereas chest X-ray showed decreased lung transparency, with submantellar thickening in the mid-lower field bilaterally (Figure 1C). He immediately received non-invasive ventilation (NIV) with protective settings and fraction of inspired oxygen (FiO₂) 60%. An improvement in dyspnoea was observed.

Seven hours after entering the hub, the patient was admitted to the COVID-19 Pneumology Department, where ventilatory support was converted to facial mask with reservoir. Twenty-four hours after admission, he showed severe respiratory failure with signs of microcirculatory distress—although with mild dyspnoea—at blood gas analysis (BGA), as well as persistent lymphocytopenia and inflammation.

At 72 hours, the patient was transferred to the intensive care unit (ICU) with signs of worsening and severe dyspnoea and

** Corresponding author: Stefania Stefani, Department of Biomedical and Biotechnological Sciences (MMARL), University of Catania, Via Santa Sofia, 97, 95123 Catania, Italy, Tel: +39 0954781232.

E-mail address: stefanis@unict.it (S. Stefani).

* These authors equally contributed to the paper.

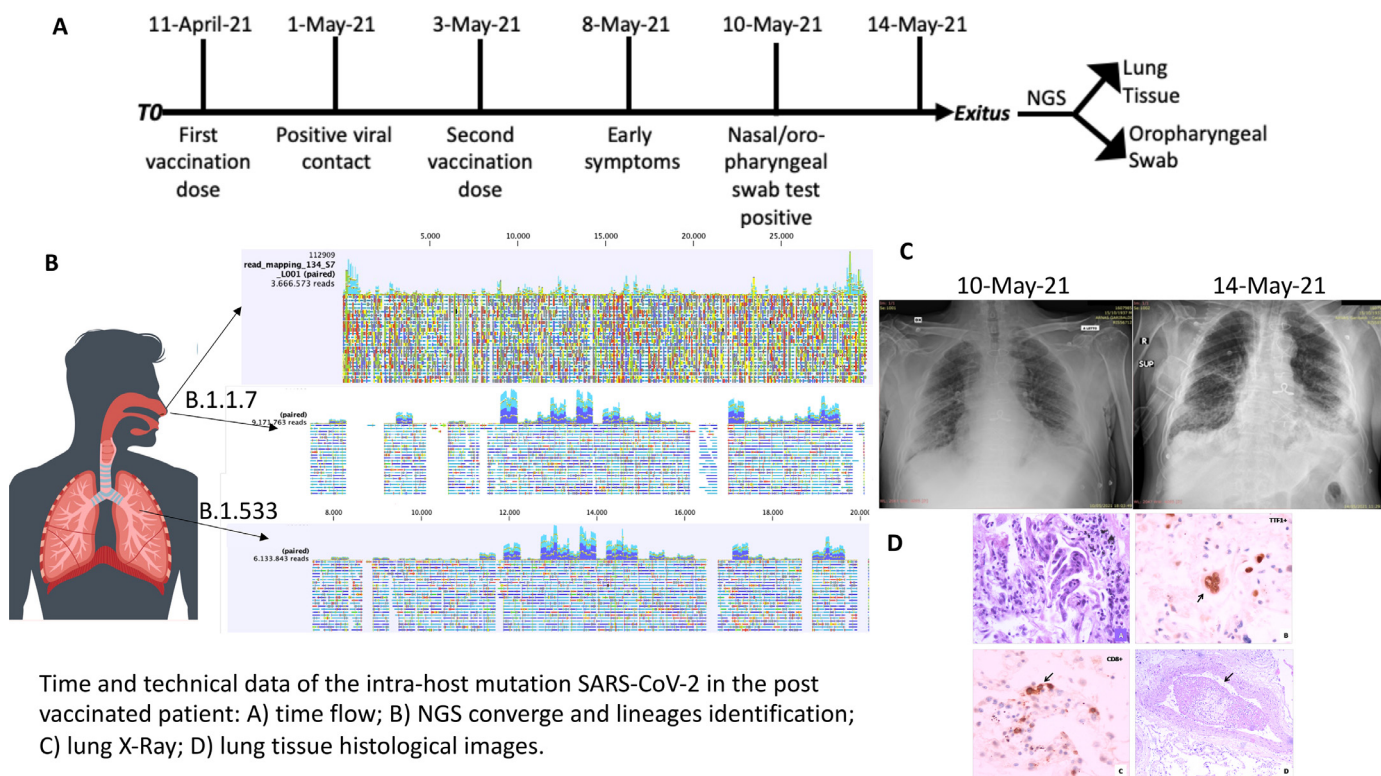


Figure 1. Time and technical data of the intra-host mutation in SARS-CoV-2 in the post-vaccinated patient. A) time flow; B) Next Generation Sequencing (NGS) converge and lineages identification; C) lung X-Ray; D) lung tissue histological images.

received NIV (Rochweg et al., 2017) in continuous positive airway pressure mode (8 cmH₂O, FiO₂ 80%). The clinical condition progressed to *Critical COVID-19* (Di Giacinto et al., 2020).

At 84 hours, upon the patient’s progression to severe hypoxemia and severe Acute Respiratory Distress Syndrome (ARDS Definition Task Force, 2012), the laboratory tests revealed persistent lymphocytopenia and systemic inflammation still in the absence of bacterial superinfections identifying a IV Stage *Critical COVID-19* as indicated by the Italian Society of Anesthesia Analgesia Resuscitation and Intensive Care (SIAARTI) guidelines 2020. Chest X-ray reported increased ground-glass opacity with a submantellar seat in the mid-lower field of the left lung with ipsilateral pleural veil (Figure 1C).

The patient was intubated and switched to mechanical ventilation with maximally protective settings and FiO₂ 100%. Respiratory mechanics measurements showed lung stiffness (Gattinoni et al., 1987).

Thirteen hours after ICU admission, the signs of multiple organ dysfunction suggested progression to *Septic Shock*, which was already reported as possibly related to *Critical COVID-19* (Critical COVID-19, VI Stage), with hypoxia and hypercarbia, and in less than 96 hours, the patient died from an episode of non-shockable rhythm.

An autopsy was performed on multi-tissue samples (Musso et al., 2021). Histology displayed the typical hallmarks of advanced COVID-19, specifically in the lung parenchyma, as well as major vascular comorbidities in the coronary tree and myocardium. Pulmonary changes included diffuse emphysematous findings with alveolar spaces filled with pneumocytes, CD68+ histiocytes, and syncytial TTF1+ pneumocytes (Figure 1D, panels A and B), with evidence of diffuse alveolar damage and intra-alveolar fibrin deposition in hyaline membranes. The inflammatory infiltrate was relatively modest and consisted mainly in clusters of

CD8+ macrophages (Figure 1D, panel C), lymphocytes, and—to a lesser extent—CD4+ cells. Multifocal occlusive thrombosis in the pulmonary arterioles (Figure 1D, panel D) and severe occlusive coronary atherosclerosis completed the pathological picture.

Material and methods

At hospital admission, a nasopharyngeal swab was collected and tested using RT-qPCR (SARS-CoV-2 Assays Allplex™ SeeGene Inc.) to perform a 4-gene molecular diagnosis of SARS-CoV-2 infection.

Another nasopharyngeal swab and a lung sample were collected on autopsy to be tested by next generation sequencing (NGS) and compared with the previous nasopharyngeal sample. RNA was extracted using the standard procedure (Musso et al., 2021; Musso et al., 2020), and all samples were also tested by reverse transcription LAMP (RT-LAMP).

RT-LAMP was performed using the SARS-CoV-2 POC kit (Enbiotech, Cat. EBT 102-48) in the ICGENE Health (Enbiotech SRL, Cat. EBT 806) system according to the manufacturer’s protocols (Stracquadanio et al., 2021).

NGS of the nasopharyngeal and lung samples was performed using the QIAseq Direct SARS-CoV-2 Primer Panel (Ref. 333896, QIAGEN, 40724 Hilden, Germany) following the manufacturer’s instructions. Libraries were quantified and evaluated for quality using the Qubit dsDNA HS Assay Kit (Ref. Q32851, Invitrogen, Carlsbad, CA, USA) fluorimeter and the Agilent® High Sensitivity DNA Kit (Agilent, Cat. No. 5067-4626).

The sequences obtained from the 3 complete viral genomes were analyzed with CLC Genomics Workbench 21 (QIAGEN Aarhus, Silkeborgvej 2 Prismet DK-8000 Aarhus C, Denmark) and uploaded to PANGOLIN (O’Toole et al., 2021) and Nextstrain (Hadfield et al., 2018) to identify and confirm the correct lineage and to GISAID

(Elbe et al., 2017) to obtain a cluster of single-nucleotide polymorphisms (SNPs) from these genomic sequences.

Results

Both the lung and the 2 nasopharyngeal samples tested positive for SARS-CoV-2 on RT-LAMP within 45 and 30 minutes of reaction, respectively.

Through bioinformatic analysis, 2 viral RNAs from the nasal swabs, which belonged to the B.1.1.7 lineage, and 1 RNA from the lung sample, which belonged to B.1.533, were identified. All NGS results were obtained with high coverage (over 6 million readings per sample, Figure 1B).

Discussion

On 10 May 2021, when the patient's oropharyngeal swab was analyzed, result of the RT-qPCR was positive but with a very high CT (>36), indicating a low viral load in the oropharyngeal cavity. However, this finding is inconsistent with the lung damage seen at the first chest X-ray. One explanation could be "RNA fragmentation"⁵ in the nasal cavity, probably owing to antibody reaction. In the 13 days of intra-pulmonary residence, the virus managed to develop "intra-host specific rearrangements" (Voloch et al., 2021; Wang et al., 2021), that is, mutations capable of making it more aggressive, such as T4087I in ORF1ab and S116T in the Spike gene. This evolution could explain the difference in lineage between the 2 different anatomical locations of the same samples: B.1.1.7 for the nasopharyngeal virus and B.1.533 for the lung virus, with the latter being apparently more aggressive (Figure 1B). In particular, B.1.533 is currently not widespread in Italy, as it is in the rest of the world, although with low percentages. This increased aggressiveness could explain the presence of both clones in the lung sample, whereas only the B.1.1.7 clone was observed in the oropharyngeal sample (O'Toole et al., 2021).

The scenario described was one of severe respiratory failure from diffuse alveolar damage associated with lymphomonocyte interstitial pneumonia and thrombotic diathesis in the lung arterioles, consistent with the reported etiopathogenesis of SARS-CoV-2 infection. The immune reaction was a combination of vaccine and immune response after infection with SARS-CoV-2, but the presence of antibodies did not lead to the disruption of the viral RNA before this could cause pulmonary infection; on the contrary, it accelerated the normal process of "intra-host specific rearrangement," as shown by the presence of a new intra-pulmonary lineage characterized by 5 worldwide low-expressed SNPs (<2%): T1022I-I23N-T145I-A185S-S116T. T1022I and I23N (in ORF1ab) have an effect on the oligomerization interface; the last SNP, also present in ORF1ab, affects the antibody recognition site/oligomerization interface (Table 1). The 2 lineages differ from each other as well as from the reference genome as follows: 11 amino-acid substitutions in ORF1a, 4 shared by both clones, 4 characterizing the B.1.1.7, and 3 characterizing the B.1.533 clone; 10 amino-acid substitutions in Spike, 6 shared by both clones, 1 characterizing B.1.1.7, and 3 being unique to B.1.533; 1 amino-acid substitution characterizing B.1.533 in ORF3; 3 amino-acid substitutions in ORF8, 1 shared by both lineages and 2 characterizing B.1.1.7; and finally, 4 amino-acid substitutions in the N gene, 2 found in both lineages, 1 characterizing B.1.1.7, and 1 characterizing B.1.533 (see Table S1).

Conclusion

This genetic observation suggested that the SARS-CoV-2 virus tends to change under selective pressure. The high mutation rate of ORF1b, containing a replicase gene, was a biological image of a complex viral survival system.

Conflicts of Interest

The authors declare that the research was conducted in the absence of any commercial or financial relationships that could be construed as a potential conflict of interest.

Funding

This work was partially supported by "linea intervento 3 Open Access Piano PIACERI 2020-2022" from University of Catania, Italy.

Acknowledgments

The authors wish to thank Prof. Cristoforo Pomara as the pathologist in charge of the autopsy and Dr. Gregoria Bufalino, who assisted the patient in the case report. We also wish to thank PharmaTranslated (<http://www.pharmatranslated.com/>), and particularly Silvia Montanari, for language support.

Contribution

NM: Formal Analysis, Investigation, Methodology, Writing the original draft. JM: Investigation, Writing the original draft. DB: Project administration, Visualization, Writing review and editing. SS: Project administration, Visualization, Writing review and editing. GB: Investigation, Writing the original draft. SS: Funding acquisition, Methodology, Resources, Supervision. EDD: Conceptualization, Methodology, Resources, Supervision.

Ethics statement

Written informed consent was obtained from the patient's family.

Supplementary materials

Supplementary material associated with this article can be found, in the online version, at [doi:10.1016/j.ijid.2022.02.044](https://doi.org/10.1016/j.ijid.2022.02.044).

References

- Ranieri VM, Gordon DR, Thompson T, Ferguson ND, Caldwell E, Fan E, Camporota L, Slutsky ASARDS Definition Task Force. Acute respiratory distress syndrome: the Berlin Definition. *JAMA* 2012;307:2526–33.
- Di Giacinto I, Grasselli G, Maggiore SM, Maugeri J, Pasero D, Viaggi B. "Raccomandazioni per la gestione del paziente critico COVID- 19. – Percorso assistenziale per il paziente affetto da COVID-19. SIAARTI 2020.
- Elbe S, Buckland-Merrett G. Data, disease and diplomacy: GISAIID's innovative contribution to global health. *Global Challenges* 2017;1:33–46.
- Gattinoni L, Pesenti A, Avalli L, Rossi F, Bombino M. Pressure- volume curve of total respiratory system in acute respiratory failure: computed tomographic scan study. *Am Rev Respir Dis* 1987;136:730–6.
- Hadfield J, Megill C, Bell SM, Huddleston J, Potter B, Callender C, Sagulenko P, Bedford T, Neher RA. Nextstrain: real-time tracking of pathogen evolution. *Bioinformatics* 2018;34:4121–3.
- Musso N, Costantino A, La Spina S, Finocchiaro A, Andronico F, Stracquadanio S, Liotta L, Visalli R, Emmanuele G. New SARS-CoV-2 Infection Detected in an Italian Pet Cat by RT-qPCR from Deep Pharyngeal Swab. *Pathogens* 2020;9:746.
- Musso N, Falzone L, Stracquadanio S, Bongiorno D, Salerno M, Esposito M, Sessa F, Libra M, Stefani S, Pomara C. Post-Mortem Detection of SARS-CoV-2 RNA in Long-Buried Lung Samples. *Diagnostics* 2021;11:1158.
- O'Toole A, Scher E, Underwood A, Jackson B, Hill V, McCrone JT, Colquhoun R, Ruis C, Abu-Dahab K, Taylor B, Yeats C, du Plessis L, Maloney D, Medd N, Attwood SW, Aanensen DM, Holmes EC, Pybus OG, Rambaut A. Assignment of epidemiological lineages in an emerging pandemic using the pangolin tool. *Virus Evol* 2021;7(2):veab064 Jul 30PMID: 34527285; PMID: PMC8344591. doi:10.1093/ve/veab064.
- Rochwerger B, Brochard L, Elliott MW, Hess D, Hill NS, Nava S, et al. Official ERS/ATS clinical practice guidelines: noninvasive ventilation for acute respiratory failure. *Eur Respir J* 2017;50.
- Stracquadanio S, Di Gaudio F, Giunta E, Falliti G, Caruso D, Pinzone C, Noto P, Di Naso C, Garozzo SF, Amedeo A, Cinà D, Cardillo MC, Zappalà S, Consoli A, Stefani S. Reverse transcriptase loop-mediated isothermal amplification (RT-LAMP) as a user-friendly system to detect SARS-CoV-2 infection: a multicentric study. *New Microbiol* 2021;44(3):181–3 JulPMID: 34783350.

Voloch CM, da Silva Francisco Jr R, de Almeida LGP, Brustolini OJ, Cardoso CC, Gerber AL, Guimarães APC, Leitão IC, Mariani D, Ota VA, Lima CX, Teixeira MM, Dias ACF, Galliez RM, Faffe DS, Pôrto LC, Aguiar RS, Castiñeira TMPP, Ferreira OC, Tanuri A, R de Vasconcelos AT. Intra-host evolution during SARS-CoV-2 prolonged infection. *Virus Evol* 2021;7:veab078.

Wang Y, Wang D, Zhang L, Sun W, Zhang Z, Chen W, Zhu A, Huang Y, Xiao F, Yao J, Gan M, Li F, Luo L, Huang X, Zhang Y, Wong SS, Cheng X, Ji J, Ou Z, Xiao M, Li M, Li J, Ren P, Deng Z, Zhong H, Xu X, Song T, Mok CKP, Peiris M, Zhong N, Zhao J, Li Y, Li J, Zhao J. Intra-host variation and evolutionary dynamics of SARS-CoV-2 populations in COVID-19 patients. *Genome Med* 2021;13:30.