


Contents lists available at [ScienceDirect](https://www.sciencedirect.com)

# American Journal of Otolaryngology–Head and Neck Medicine and Surgery

journal homepage: [www.elsevier.com/locate/amjoto](http://www.elsevier.com/locate/amjoto)

## Endaural microscopic approach versus endoscopic transcanal approach in treatment of attic cholesteatomas

Giannicola Iannella<sup>a,\*</sup>, Annalisa Pace<sup>a</sup>, Antonio Greco<sup>a</sup>, Antonella Polimeni<sup>b</sup>,  
Antonino Maniaci<sup>c</sup>, Alessandro Mucchino<sup>a</sup>, Jerome R. Lechien<sup>d</sup>, Alberto Maria Saibene<sup>e</sup>,  
Quentin Mat<sup>f,g</sup>, Stephane Gargula<sup>h</sup>, Nicolas Fakhry<sup>i</sup>, François Simon<sup>j</sup>,  
Federico Maria Gioacchini<sup>k</sup>, Massimo Re<sup>k</sup>, Giuseppe Magliulo<sup>a</sup>

<sup>a</sup> Department of ‘Organi di Senso’, University ‘Sapienza’, Viale dell’Università, 33, 00185 Rome, Italy

<sup>b</sup> Department of Oral and Maxillofacial Sciences, University of Rome, 6, Caserta St, 00161, Sapienza, Rome, Italy

<sup>c</sup> Department of Medical and Surgical Sciences and Advanced Technologies ‘GF Ingrassia’, ENT Section, University of Catania, Via S. Sofia, 78, 95125 Catania, Italy

<sup>d</sup> Department of Otolaryngology, Elsan Polyclinic of Poitiers, Poitiers, France

<sup>e</sup> Otolaryngology Unit, Santi Paolo e Carlo Hospital, Department of Health Sciences, Università degli Studi di Milano, Milan, Italy

<sup>f</sup> Department of Otorhinolaryngology, C.H.U. Charleroi, Charleroi, Belgium

<sup>g</sup> Faculty of Medicine and Pharmacy, University of Mons (UMons), Mons, Belgium

<sup>h</sup> Department of Otolaryngology, Hôpital Fondation Adolphe de Rothschild, 29 Rue Manin, 75019 Paris, France

<sup>i</sup> Department of Otolaryngology-Head and Neck Surgery, APHM, Aix-Marseille Univ, Hôpital La Conception, Marseille, France

<sup>j</sup> Department of Pediatric Otolaryngology, Necker-Sick Children’s Hospital, AP-HP-University of Paris, Paris, France

<sup>k</sup> ENT Unit, Department of Clinical and Molecular Sciences, Polytechnic University of Marche, 60121 Ancona, Italy

### ARTICLE INFO

#### Keywords:

Attic cholesteatoma  
Endoscopic ear surgery  
Otology  
Microscopic ear surgery

### ABSTRACT

**Purpose:** Compare the audiological results and postoperative outcomes of the endoscopic approach versus the endaural microscopic approach for treatment of attic cholesteatomas, using a randomized prospective model.

**Materials and methods:** Eighty patients were consecutively enrolled in the study and randomized into two groups of treatment of 40 patients: Group A –tympanoplasty with a microscopic endaural approach; Group B –tympanoplasty with an exclusive trans-meatal endoscopic approach. Preoperative, intraoperative and post-operative outcomes were evaluated. Hearing was assessed preoperatively and at 1 month, 3 months and 6 months after surgery in both groups.

**Results:** There were no differences in the parameters analyzed (CT findings, patient age, disease duration, intraoperative cholesteatoma characteristics,) between the group A and B patients. No statistical difference between the two groups regarding hearing improvement, abnormal taste sensation, dizziness, post-operative pain and healing times emerged. Graft success rate was 94.5 % and 92.1 % for MES and ESS respectively.

**Conclusion:** Both microscopic and exclusively endoscopic endaural approaches offer similar and excellent results in the surgical treatment of attic cholesteatomas.

### 1. Introduction

Attic cholesteatoma comes from the retraction of the pars flaccida or Shrapnell membrane, extending to the attic, going through the aditus, and eventually reaching the antrum, mastoid, or tympanic cavity [1].

Microscopic ear surgery (MES), using a trans-canal or retro-auricular approach, is usually used to treat this kind of pathology. Traditionally, in cases of attic cholesteatoma, most surgeons prefer to perform MES via a retro-auricular approach (canal wall up tympanoplasty +

mastoideotomy), in order to perform an epi-tympanotomy and remove lesions of the attic and middle ear. However, it should be remembered that it is also possible to treat ‘attic’ cholesteatomas by an endaural microscopic approach. This could be performed via an incision of the external auditory canal (Lampert, Heerman or Shambaugh incisions) that improves the diameter of the external auditory canal (CUE), thus widening access to the middle ear and visualization of its structures. It also requires removal of the bony wall in the attic part of the external auditory canal (atticotomy) and of the cholesteatoma, reconstruction of

\* Corresponding author at: Via Satrico 7, Rome 00183, Italy.

E-mail address: [giannicola.iannella@uniroma1.it](mailto:giannicola.iannella@uniroma1.it) (G. Iannella).

<https://doi.org/10.1016/j.amjoto.2023.103860>

Received 19 February 2023;

Available online 23 March 2023

0196-0709/© 2023 Elsevier Inc. All rights reserved.

the scutum defect and, possibly an ossiculoplasty [2–7].

The advent of endoscopes changed the therapeutic approach to middle ear diseases: in the last years various authors have proposed exclusive transcanal endoscopic ear surgery (EES) as an effective and safe surgical technique for treating middle ear cholesteatomas [8–11].

A wider and clearer view of the surgical field, less need for normal tissue disruption for access, and a better visibility of the hidden structures are some of the reasons for the wide development of the ESS worldwide. However, an exclusive middle ear endoscopic surgery does have some possible limitations linked to single-handed work, the lack of a stereoscopic view and, last but not the least, a potentially long surgical learning curve. Therefore, in consideration of these advantages and limitation, whether endoscopes can replace the microscopic approach for limited attic disease remains unclear [12–16]. Some studies compared the MES via retroauricular approach (canal wall up tympanoplasty + mastoidectomy) and the exclusive endoscopic ear surgery for the treatment of ‘attic’ cholesteatomas. These authors showed how the audiological outcomes and tympanic graft success rates achieved by EES are similar to the results obtained using a microscopic approach, although the analysis of postoperative pain and healing times showed better results for EES [17–21].

Despite these findings, no author has so far compared the endaural microscopic approach and the trans-meatal endoscopic approach for treating ‘attic’ cholesteatomas. In this study, we have attempted to

compare the audiological results and postoperative outcomes of the endoscopic approach versus the endaural microscopic approach for treatment of attic cholesteatomas, using a randomized prospective model.

## 2. Materials and methods

### 2.1. Trial design

The study protocol was a single-center controlled prospective randomized trial with two prospective arms: patients with attic cholesteatoma treated with a microscopic endaural approach vs patients with attic cholesteatoma treated using an exclusively endoscopic surgical approach. Fig. 1 shows the flow chart of the trial design.

### 2.2. Prospective patients' enrollment

All patients with a diagnosis of cholesteatoma consecutively referred to Organi di Senso Department at ‘Sapienza’ University in Rome, from January 2019 to October 2021 to evaluate the possibility of surgical treatment, were initially considered as possible candidates for the study inclusion.

Baseline assessment of all enrolled patients was performed: full medical history, otomicroscopic evaluation and a high resolution middle

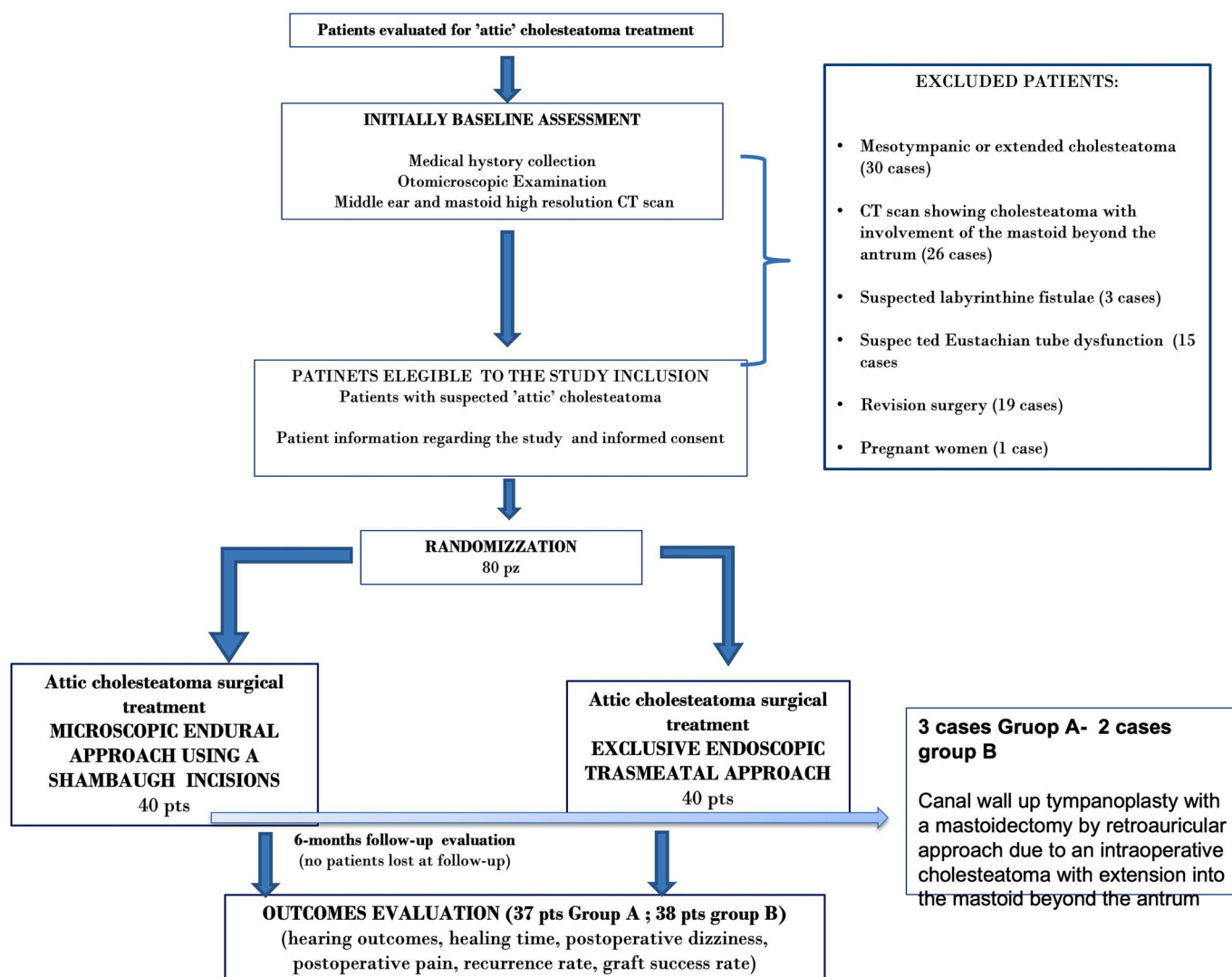


Fig. 1. Shows the flow chart of the trial design.

ear and mastoid CT scan were performed.

Initial assessment of eligibility for participating in the study was provided by a group of researchers on the basis of the inclusion/exclusion criteria defined and reported in Table 1.

Only patients with otomicroscopic findings of attic cholesteatoma/epitympanic retraction and CT imaging showing cholesteatoma located in the epitympanic region were initially enrolled in the study. Patients with CT evidence of mesotympanic or extended cholesteatomas, wide mastoid involvement, suspected labyrinthine fistulae, Eustachian tube dysfunction or revision surgery were excluded in order to keep the study groups homogenous.

### 2.3. Randomization

Eighty patients were consecutively enrolled in the study and randomized into two groups of treatment of 40 patients:

- Group A –tympanoplasty with a microscopic endaural approach
- Group B –tympanoplasty with an exclusive trans-meatal endoscopic approach

For each patient randomization was conducted by picking a piece of paper with a treatment order written on it out of a box (group A vs group B). The chances of picking group 1 or group 2 were 50/50. After randomization patients were casually distributed into two groups of study.

**Table 1**

Preoperative, intraoperative and postoperative findings in the 2 groups of patients enrolled in the study.

Parameters	MES (37 pts)	EES (38 pts)	p-Value
Sex	22 females 15 males	24 females 14 males	
Average age	40.2	43.9	
Preoperative symptoms			
Recurrent otorrhea	26 (70.2 %)	28 (73.6 %)	
Facial palsy	–	–	0.8
Vertigo/dizziness	–	–	
Mastoid cholesteatoma extension beyond the antrum on CT scan	–	–	
Facial nerve dehiscence on CT scan	5 (13.5 %)	7 (18.4 %)	0.7
Intraoperative facial nerve dehiscence	7 (18.9 %)	9 (23.6 %)	0.7
Horizontal semicircular canal fistulas	0	0	–
Complete removal of the cholesteatoma	37 (100 %)	38 (100 %)	–
Overall operation time (minutes)	68.9 min (High = 115.0 Low = 65.0; Standard Deviation = 19.9)	77.8 min (High = 93.0 Low = 55.0; Standard Deviation = 10.49)	0.1 (Student t-test)
Temporary postoperative dizziness	3 (8.1 %)	2 (5.2 %)	0.6
Postoperative pain (for 2 to 3 days after surgery and requiring analgesics)	8 (21.6 %)	5 (13.1 %)	0.3
Temporary abnormal taste sensation	13 (35.1 %)	10 (26.3 %)	0.4
Graft success rate	35 (94.5 %)	35 (92.1 %)	1
Average healing time	32.3 days (High = 54.0 Low = 18.0; Standard Deviation = 7.04)	34.8 days (High = 48.0 Low = 30; Standard Deviation = 9.4)	0.5
Recurrence of the disease	0	0	–

### 2.4. Surgery

Microscopic surgeries were performed using a Leica M620 F20. Differently, for EES, rigid endoscopes with an angulation of 0, 30 and 45°, a length of 14-cm and an outer diameter of 3 mm and 4 mm (Storz, Germany) were used: they were connected to a camera head (Storz, Germany) and a high definition monitor positioned in front of the surgeon.

The two surgical approaches differed only in the initial surgical steps. The microscopic surgery was performed with an endaural approach according to the Shambaugh incision (intertragal incision in a superior direction), with creation of a large tympanomeatal flap in the poster-osuperior and posteroinferior portions of the external auditory canal (Fig. 2). The ESS was performed with a transmeatal approach with direct creation of the tympanomeatal flap in the posterosuperior and posteroinferior portions of the external auditory canal (Fig. 3).

After creation of the tympanomeatal flap the surgical steps performed using either microscope or endoscope were the same:

- access to the middle ear and preservation of the chorda tympani;
- anterior atticotomy with identification of the ossicles, the oval and round windows, the tympanic segment of the Fallopian canal, the cocleariform process and horizontal semicircular canal;
- removal of any eroded ossicles (incus and the head of malleus);
- complete removal of the cholesteatoma matrix;
- graft with temporalis fascia or cartilage tympanoplasty using an underlay technique;
- reconstruction of the attic defect with sheets of tragus or conchal cartilage;
- repositioning of the tympanomeatal flap in its original position. Gelfoam was also used as packing for the external auditory canal.

In the microscopic endaural approach, after repositioning the tympanic-meatal flap, a 4-0 resorbable suture was placed to close the incision at the tragus.

### 3. Preoperative and intraoperative evaluation

Preoperative clinical symptoms (otorrhea, facial palsy, vertigo/dizziness) of all patients enrolled in the study were initially evaluated. The presence of facial nerve dehiscence was investigated on CT images (absence of the osseous wall of the facial nerve canal), and subsequently compared to the corresponding intraoperative findings. Any intraoperative observations of Fallopian canal erosion made using either an operating microscope or an endoscope and confirmed by palpation during the removal of the cholesteatoma matrix were considered as dehiscence.

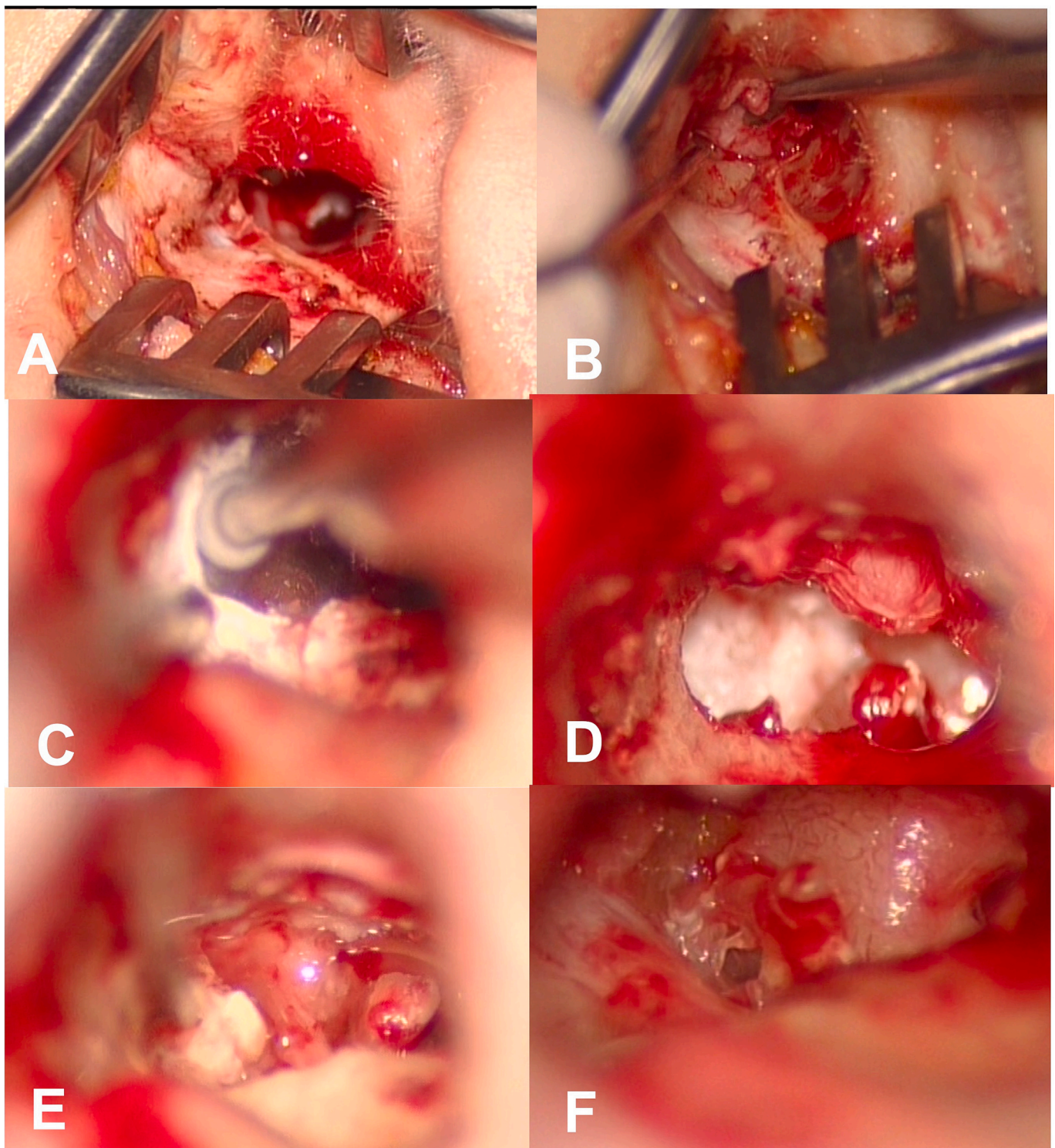
The facial nerve dehiscence and the eventual presence of labyrinthine fistula, operating times, postoperative hearing and postoperative pain were evaluated in the light of eventual surgical complications.

### 4. Postoperative evaluation

Hearing was assessed preoperatively and at 1 month, 3 months and 6 months after surgery in both groups. Final hearing recovery at six month follow-up was evaluated and classified according to the draft AAO-HNS hearing classification system [24].

All patients enrolled in the study were asked to evaluate the severity of post-operative pain. This was classified using three grades: almost no pain, mild pain requiring no analgesic drugs and pain requiring analgesic drugs [19,25,26]. In case of pain requiring analgesics, drugs were prescribed by us and consisted of non-steroidal anti-inflammatory drugs in all cases. No other medication, such as steroids, diazepam or other drugs with a possible impact on post-operative pain or healing outcomes was taken by the patients of the study.

Taste abnormalities were investigated as: presence or absence of a



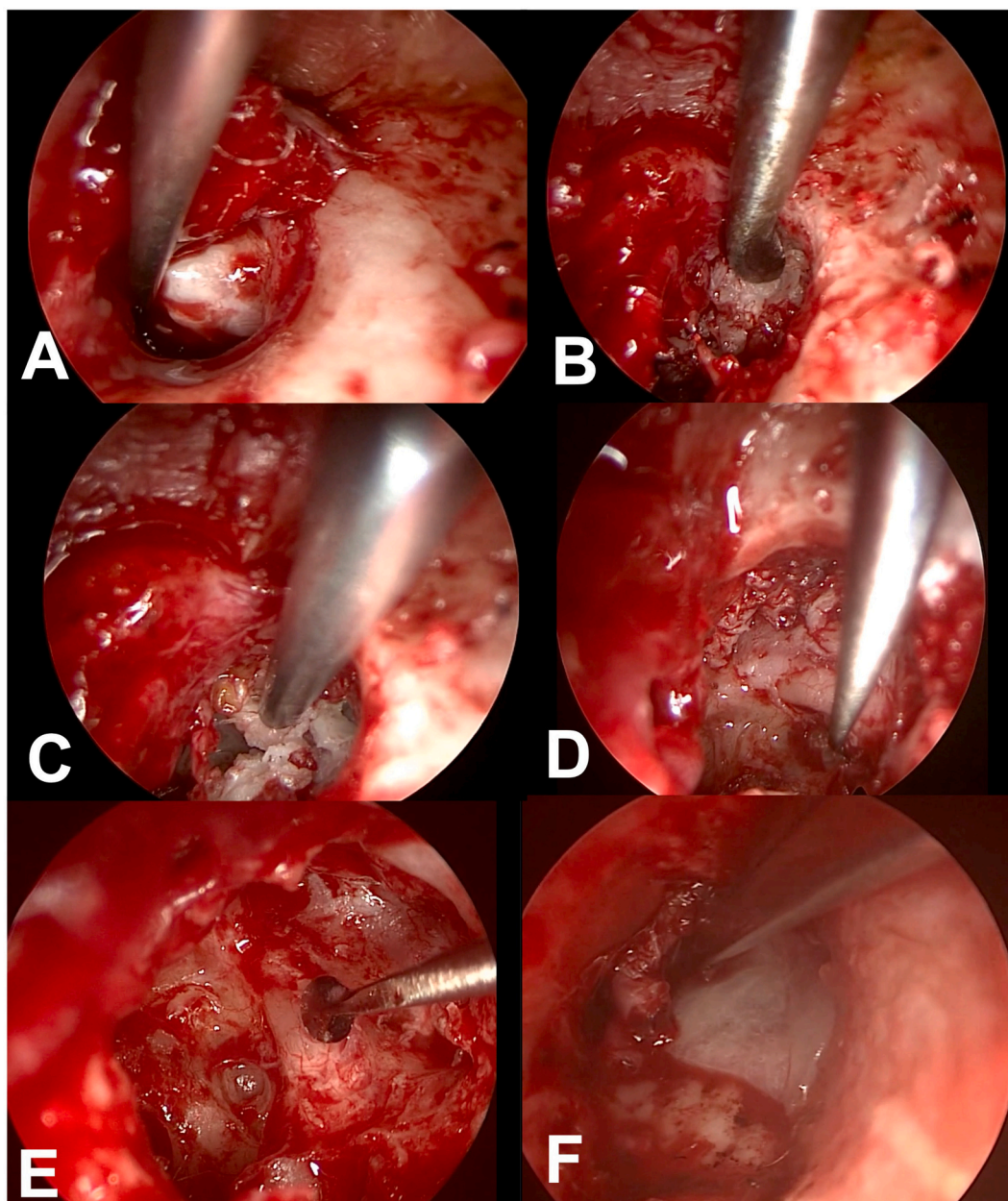
**Fig. 2.** Endaural microscopic approach. (A) Shambaugh incisions is performed to improves the diameter of the external auditory canal (CUE), thus widening access to the middle ear; (B) creation of the tympanomeatal flap; (C) removal of the bony wall in the attic part of the external auditory canal to identify the cholesteatoma and ossicular chain; (D) exposure and removal of cholesteatoma (incus was eroded); (E) removal of the last portion of the cholesteatoma between the crus of the stapes. (F) Complete removal of cholesteatoma, visualization of stapes superstructures and facial nerve.

subjective abnormal taste sensation [4,7,22].

Healing time was investigated by a physical examination and otomicroscopic investigation. It was determined as the days between surgery and successful tympanic grafting with complete eardrum repair and the patient's return to his/her normal activities. Otomicroscopic follow-up was performed approximately every 15 days for the first 3 months

after surgery and then once every 3 months.

The postoperative follow-up period ranged from 8 to 18 months (mean: 15.8 months).



**Fig. 3.** Transmeatal exclusive endoscopic approach. (A) creation of the tympanomeatal flap and cholesteatoma exposition; (B) removal of the bony wall in the attic part of the external auditory canal to identify the cholesteatoma and ossicular chain; (C) removal of cholesteatoma; (D) removal of the last portion of the cholesteatoma on the stapes platina (stapes superstructures and incus eroded) (E) complete removal of cholesteatoma, visualization of a dehiscent facial nerve.

## 5. Statistical analysis and ethical statement

To test the differences between the groups, Fisher's exact test was applied to categorical data, while Student's *t*-test was used for continuous data. ANOVA and MANOVA tests were used as appropriate. Probability values lower than 0.05 were considered statistically significant. All analyses were performed using the STATA 12.1 software (Stata Corp., College Station, TX, USA).

The local Ethics Committee approved the study and all patients signed an informed consent for inclusion in the study before their enrollment.

### 5.1. Results

In three patients (7.5 %) of the group treated via the microscopic approach there was an attic cholesteatoma with extension into the

mastoid beyond the antrum, which could not be controlled with an endaural approach. In these patients it was necessary to convert the approach to a canal wall up tympanoplasty with mastoidectomy via retroauricular approach. This measure was also necessary for two patients (5 %) of the endoscopic group. In these patients surgery started with the trans-meatal endoscopic approach but was converted to a CWU tympanoplasty with mastoidectomy and epitympanotomy due to the impossibility of completely removing the cholesteatoma in the mastoid region owing to the fact that it extended beyond the semicircular lateral canal. No statistical difference emerged between MES and ESS concerning failure to remove cholesteatoma that extended to the mastoid. In order to compare trans-canal approaches, these patients were excluded from the study analysis, meaning that postoperative results were reported for 37 patients in the MES group and 38 patients in the EES group.

The preoperative and intraoperative data for patients who

underwent both endoscopic and microscopic endaural approaches are summarized in [Table 1](#).

There were no differences in the parameters analyzed (CT findings, patient age, disease duration, intraoperative cholesteatoma characteristics) between the group A and B patients, indicating a homogeneous selection of patients that provided a good comparison of the outcomes between the two groups ( $p > 0.05$  in all variables comparison).

A diagnosis of attic cholesteatoma was intraoperatively confirmed in all patients of both groups.

Preoperative CT images showed a suspected facial nerve dehiscence in 13.5 % of the patients in the MES group and 18.4 % of EES group ( $p = 0.7$ ).

Intraoperatively, 18.9 % of MES patients showed facial nerve dehiscence, compared to 23.6 % in the EES group. This difference did not prove to be statistically significant ( $p = 0.7$ ).

The overall operation time for MES presented a mean value of 68.9 min. Despite the group of patients treated via ESS showed a lower mean surgical time of 7.8 min and no statistical differences were evident ( $p$  value = 0.08).

None of the patients in our study developed postoperative iatrogenic facial palsy.

In all of the enrolled patients of these two groups the cholesteatoma matrix was judged to have been totally removed without suspicion of a residual disease. No horizontal semicircular canal fistulas were detected in any cases.

## 5.2. Postoperative results

A transient abnormal taste sensation occurred in 35.1 % and 26.3 % of the microscopic and endoscopic groups respectively, without significant differences between the two groups ( $p = 0.5$ ). Postoperative dizziness was reported in 8.1 % of patients in the MES group and 5.2 % in the EES group.

The average postoperative air-conduction thresholds of microscopic and endoscopic approaches are showed in [Table 2](#). No statistical difference between the two groups ( $p > 0.05$ ) regarding hearing improvement emerged.

Regarding postoperative pain: 21.6 % of patients who underwent microscopic surgery and 13.1 % of the endoscopic group described pain requiring analgesic drugs for 2 to 3 days after microscopic surgery. No statistical difference emerged in terms of post-operative pain between EES and MES ( $p = 0.3$ ).

At 3-month follow-up, 2 patients of the MES group and three patients of the ESS group presented a perforation of the MT in the absence of recurrence of cholesteatoma or infection, due to the failure of the temporalis muscle fascia graft. Graft success rate was 94.5 % and 92.1 % for MES and ESS respectively.

The average healing time was 32.3 days for the microscopic group and 34.8 days for the endoscopic group. The difference in the healing times between the two approaches was not statistically significant ( $p = 0.5$ ).

Finally, no recurrence of the disease during a mean follow-up period of 6-months follow-up was observed in either group of patients.

**Table 2**

Audiological results; microscopic vs endoscopic group.

	Average preoperative air-conduction thresholds (dB)		Average postoperative air-conduction thresholds (dB)		P-value
	Microscopic surgery	Endoscopic surgery	Microscopic surgery	Endoscopic surgery	
<−10	3 (7.5 %)	4 (10 %)	2 (5 %)	3 (7.5 %)	1
−11–20	11 (27.5 %)	14 (35 %)	7 (17.5 %)	6 (15 %)	0.7
21–30	18 (45 %)	16 (40 %)	23 (57 %)	21 (52.5 %)	0.6
>30	8 (20 %)	6 (15 %)	8 (20 %)	10 (25 %)	0.2

## 6. Discussion

In this study, we aimed to compare this type of endaural microscopic approach with the ESS, in the management of attic cholesteatoma, using a randomized prospective model.

The endaural microscopic operation was first introduced by Lampert and became very popular after the introduction of the one-stage fenestration of the horizontal semicircular canal for otosclerosis. By combining the Heermann extracartilaginous endaural incision with the Surdille tympanomeatal flap, Lempert's endaural method soon spread throughout the world, popularizing the endaural operation. Shambaugh demonstrated that excision of the meatal skin was not necessary, using a long tympano-meatal flap and extending the inter-tragal incision in a superior direction [1–7]. This type of approach allows an enlargement of the EAC and of the surgical field and may be used to treat epitympanic cholesteatomas, replacing the classic CWU tympanoplasty with a retro-articular access.

The endaural approach, requires stepwise removal of the scutum and variable amounts of the canal wall to expose the epitympanum. The benefit of this is that the exposure required is tailored to the extent of the disease, reducing surgical times and overall morbidity. A partial or complete epitympanectomy may be performed, depending upon the volume of the disease. Complete epitympanectomy requires the removal of the incus and head of the malleus and complete removal of the lateral epitympanic bone to expose all the boundaries of the epitympanum. The endaural approach also allows for harvesting of reconstructive material, such as temporalis fascia (through the superior extension of the incision) or cartilage and perichondrium (from the tragus or the concha). Usually there are no problems in removing all pathological tissue from the attic, the tegmen tympani and the mastoid tegmen, because reasonable exposure of the superior part of the cavity is possible through the endaural approach [1–7].

Exclusive endoscopy for the treatment of middle ear cholesteatomas has become widely used in recent years by many authors who confirmed the efficacy, safety and excellent surgical outcomes of this surgical technique for the treatment of middle ear cholesteatomas. The main rationale is better visualization of the middle ear structures since the endoscopes comprise several angulations and allow visualization of any regions of the middle ear [10–15].

Some studies compared the microscopic and endoscopic approaches in cholesteatoma surgery [17–21]. Manzoor et al. [22] analyzed patients who underwent surgical resection of cholesteatoma via EES ( $n = 122$ ) and microscopic retroauricular ( $n = 253$ ) approach. The EES approach for cholesteatoma resection showed similar postoperative outcomes to the microscopic approach with no difference in the disease recurrence rate. Wo et al. [23], comparing a total of 190 patients diagnosed with attic cholesteatoma, showed how the endoscopic management of limited attic cholesteatoma showed definite advantages over the conventional retroauricular microscopic approach, such as providing better visualization, requiring less postoperative time, subjecting the patients to less pain, and decreasing the incidence of complications. In the meta-analysis described by Li et al. [21], thirteen studies evaluating endoscopic and microscopic surgery were included. The pooled recurrence and residual rates of cholesteatoma were significantly lower in the EES group than in the MES group [RR: 0.51, 95%CI: 0.31–0.84, heterogeneity ( $I^2$ ) = 4.7 %;  $P = 0.394$ ; RR: 0.68; 95%CI: 0.47–0.99;  $I^2 = 0.0$  %;  $P = 0.878$ ; respectively]. However, there were no significant differences in other parameters, such as graft intake success rates, audiological performance, and operation times, between the 2 groups.

Bae et al. [17] collected data from patients with attic cholesteatoma who were treated using endoscopic and microscopic approach. These authors reported that there were no significant differences between the two groups regarding hearing improvement, operating time, post-operative pain and recurrence rate. However, this was only a retrospective paper regarding few cases.

As shown above, the comparative analysis between microscopic and

endoscopic cholesteatoma showed different results according to different studies. This could be explained by the nature of the studies: more retrospective or not randomized studies. Moreover, there were different populations of patients, disease findings, stages of pathology (not only epitympanic cholesteatomas) and, an equally important aspect, different surgical approaches (retroauricular microscopic vs. transmeatal endoscopic). Besides, no evidence comparing the endaural microscopic approach with the Shambough incision and the transmeatal endoscopic approach in 'attic' cholesteatomas surgery has been reported in the literature.

In this study, comparing the endoscopic and microscopic subgroups, there were no differences in the following aspects: age, preoperative hearing; presence of intraoperative facial nerve dehiscence. This indicates that the study groups enrolled were homogenous, ideal for procedural comparison.

All patients were surgically treated with an exclusive endoscopic or microscopic approach.

Our study confirms that the MES with endaural approach and the ESS do not differ in terms of postoperative hearing outcomes, postoperative abnormal taste sensation, postoperative dizziness and graft success rates.

These results are in accordance with the systemic review described by Tseng et al. [24], and the meta-analysis performed by Li et al. [21], which both showed how tympanic graft success rates and hearing results for EES and MES are comparable.

The analysis of postoperative pain and healing times showed no differences in endaural MES and trans-canal EES. These results however, appear in contrast with other findings reported in the literature. Magliulo et al., compared MES via retroauricular approach and ESS and observed that the endoscopic surgical approach had faster healing times and less post-operative pain. Choi et al. [25], reported how the endoscopic group had a significantly lower level of pain than the microscopic groups 1 day after surgery. McCallum et al. [26] performed a retrospective study of post-operative pain scores after endoscopic and microscopic ear surgery and reported how, overall, endoscopic procedures have statistically significant lower VAS pain threshold outcomes when compared to microscopic procedures on post-operative days one ( $p < 0.001$ ), two ( $p < 0.001$ ), three ( $p = 0.001$ ) and seven ( $p = 0.007$ ).

In our opinion, and as claimed by Choi et al. [25] the increased pain observed in patients performing a retro-auricular MES approach may be attributable to the external incision and the mastoid bone drilling performed. Therefore, the smaller incision made with Shambough's endaural approach and the reduced manipulation obtained with this type of access could explain the similar values for healing time and postoperative pain obtained in our MES and ESS groups.

In our study there were no cholesteatoma recurrences in either group of patients. However, we know that the follow-up time in the present study (6 months) is too short for drawing definite conclusions regarding disease recurrence in primary EES for attic cholesteatomas. This could be considered the main limitation of this study.

Finally, in our view, the two surgical approaches reported for treating attic cholesteatoma differ only in the viewing instrument used (microscope or endoscope) and the intertragal incision, since the subsequent surgical steps are very similar. Therefore, the choice between exclusively microscopic or endoscopic approaches should depend on a meticulous balance between their advantages and disadvantages. The microscope is, traditionally, the instrument employed in otologic surgery, providing excellent vision, depth perception with possibility of magnification and the benefit of the surgeon being able to use both hands [27]. It should be also considered that in the endaural approach under microscopic view makes it possible to obtain both 3-D vision and two-hand procedure, thus avoiding postauricular incision analogously to EES surgery.

The advantages of trans-canal EES are its optimal visualization due to the proximity of the surgical field, around the corner exploration, absence of external incisions and tissue preservation [10–15]. In

contrast, the disadvantage of endoscopic surgery consists of the need for one-hand surgery. Moreover, it should be remembered that, as claimed by Prasad et al. [27] the presence of blood and bone dust in the field, requiring frequent cleaning of the endoscope, seems to determine a less efficacious management of surgical complications (trauma to vital structures, etc.) than microscopic surgery.

## 7. Conclusions

Both microscopic and exclusively endoscopic endaural approaches offer similar and excellent results in the surgical treatment of attic cholesteatomas.

In the case of epitympanic cholesteatomas, given the similarity of surgical results and postoperative outcomes, the type of surgical approach should be chosen by the surgeon in consideration of the advantages and disadvantages of the surgical approach and relative instruments, the surgeon's personal preference and experience [15–20], bearing in mind that both options should be available in the armamentarium of the otologists.

## Funding

None.

## Ethical standards

All procedures performed in studies are in accordance with the ethical standards of Sapienza University and with the 1964 Helsinki declaration.

## Ethical approval

All procedures performed in studies are in accordance with the ethical approval of the Sapienza University.

## Informed consent

Informed consent was obtained from all individual participants included in the study.

## Declaration of competing interest

The authors declare that they have no conflict of interest.

## References

- [1] Magliulo G, Iannella G. Endoscopic versus microscopic approach in attic cholesteatoma surgery. *Am J Otolaryngol* 2018;39(1):25–30.
- [2] Nikolopoulos TP, Gerbesiotis P. Surgical management of cholesteatoma: the two main options and the third way—atticotomy/limited mastoidectomy. *Int J Pediatr Otorhinolaryngol* 2009;73(9):1222–7.
- [3] Hajare P, Mathew RS, Singh A, Shetty SS. Intraoperative classification of cholesteatoma using ChOLE classification and evaluating its treatment outcomes using inside out approach mastoidectomy. *Indian J Otolaryngol Head Neck Surg* 2021;73(4):437–42.
- [4] Roth TN, Haeusler R. Inside-out technique cholesteatoma surgery: a retrospective long-term analysis of 604 operated ears between 1992 and 2006. *Otol Neurotol* 2009;30(1):59–63.
- [5] Vadiya S, Kedia A. Atticotomy, attic reconstruction, tympanoplasty with or without ossiculoplasty, canal plasty and cortical mastoidectomy as part of intact canal wall technique for attic cholesteatoma. *Indian J Otolaryngol Head Neck Surg* 2015;67(2):128–31.
- [6] Motegi M, Yamamoto Y, Akutsu T, Nakajima T, Takahashi M, Sampei S, Yamamoto K, Udagawa T, Sakurai Y, Kojima H. Retrograde mastoidectomy with canal wall reconstruction versus intact canal wall tympanomastoidectomy for cholesteatoma with minimal mastoid extension. *Eur Arch Otorhinolaryngol* 2022; 279(11):5113–21.
- [7] Lopes Noschang, da Silva M, Selaimen da Costa S, André Selaimen F, da Costa Huve F, Lang Silva A, Dias Toshiaki Koga F, Martins-Costa LL, Bernard Rosa Nery M, Zanardini M, Sperling N. Residual cholesteatoma after endoscopic-Assisted Canal wall-up tympanomastoidectomy: a randomized controlled trial. *Otol Neurotol* 2022;43(7):803–7.

- [8] Beckmann S, Mantokoudis G, Weder S, Borner U, Caversaccio M, Anschutz L. Endoscopic cholesteatoma surgery. *J Vis Exp* 2022;19:179.
- [9] Wu N, Wang F, Hou Z, Yang S. Improvement of otoendoscopic surgery for epitympanic cholesteatoma invading the mastoid. *Acta Otolaryngol* 2019;139(6):492–6.
- [10] Iannella G, Marcotullio D, Re M, Manno A, Pasquariello B, Angeletti D, Falasca V, Magliulo G. Endoscopic vs microscopic approach in stapes surgery: advantages in the middle ear structures visualization and Trainee's point of view. *J Int Adv Otol* 2017;13(1):14–20.
- [11] Angeletti D, Pace A, Iannella G, Rossetti V, Colizza A, Di Gioia C, Magliulo G. Tympanic cholesterol granuloma and exclusive endoscopic approach. *Am J Case Rep*. 2020;22(21):e925369.
- [12] Silva MNL, Selaimen FA, Huve FDC, Koga FDT, Martins-Costa LL, Bergamaschi JAP, Silva AL, da Costa SS. Endoscopic-Assisted Canal wall-up tympanomastoidectomy for reduction of residual cholesteatoma. *Int Arch Otorhinolaryngol*. 2021;26(2):e260–4.
- [13] Pace A, Visconti IC, Iannella G, Milani A, Rossetti V, Cocuzza S, Maniaci A, Messineo D, Magliulo G. Petrous bone cholesteatoma: facial and hearing preservation. *Ear Nose Throat J* 2021;19. 1455613211056554.
- [14] Marchioni D, Rubini A, Gazzini L, Alicandri-Ciuffelli M, Molinari G, Reale M, Presutti L. Complications in endoscopic ear surgery. *Otol Neurotol* 2018;39(8):1012–7.
- [15] Iannella G, De Vincentiis M, Greco A, Vicini C, De Vito A, Meccariello G, Cammaroto G, Pelucchi S, Magliulo G. Endoscopic approach in second stage ossicular chain reconstruction. *Am J Otolaryngol* 2019;40(5):735–42.
- [16] Iannella G, Angeletti D, Manno A, Pasquariello B, Re M, Magliulo G. Malleostapedotomy in stapes revision surgery: is an endoscopic approach possible? *Laryngoscope* 2018;128(11):2611–4.
- [17] Bae MR, Kang WS, Chung JW. Comparison of the clinical results of attic cholesteatoma treatment: endoscopic versus microscopic ear surgery. *Clin Exp Otorhinolaryngol* 2019;12(2):156–62.
- [18] Moneir W, Hemdan A, El-Kholy NA, El-Kotb M, El-Okda M. Endoscopic transcanal attico-antrostomy versus endoscopic-assisted canal wall up mastoidectomy in management of localized cholesteatoma: a randomized clinical trial. *Eur Arch Otorhinolaryngol* 2022;279(9):4371–8.
- [19] Toulouie S, Block-Wheeler NR, Rivero A. Postoperative pain after endoscopic vs microscopic otologic surgery: a systematic review and meta-analysis. *Otolaryngol Head Neck Surg* 2022;167(1):25–34.
- [20] Curran JF, Coleman H, Tikka T, Iyer A. Comparison of outcomes of endoscopic ear surgery with microsurgery for cholesteatoma: a prospective study of 91 cases with three-year follow-up. *Clin Otolaryngol* 2022;47(1):197–202.
- [21] Li B, Zhou L, Wang M, Wang Y, Zou J. Endoscopic versus microscopic surgery for treatment of middle ear cholesteatoma: a systematic review and meta-analysis. *Am J Otolaryngol* 2021;42(2):102451.
- [22] Manzoor NF, Totten DJ, McLeod ME, Sherry AD, Perkins EL, Haynes DS, Rivas A. Comparative analysis of recidivism after endoscopic and microscopic-based cholesteatoma resection. *Otol Neurotol* 2022;43(4):466–71.
- [23] Wu L, Liu Q, Gao B, Huang S, Yang N. Comparison of endoscopic and microscopic management of attic cholesteatoma: a randomized controlled trial. *Am J Otolaryngol* 2022;43(3):103378.
- [24] Tseng CC, Lai MT, Wu CC, Yuan SP, Ding YF. Comparison of the efficacy of endoscopic tympanoplasty and microscopic tympanoplasty: a systematic review and meta-analysis. *Laryngoscope* 2017;127(8):1890–6.
- [25] Choi N, Noh Y, Park W, Lee JJ, Yook S, Choi JE, Chung WH, Cho YS, Hong SH, Moon IJ. Comparison of endoscopic tympanoplasty to microscopic tympanoplasty. *Clin Exp Otorhinolaryngol* 2017;10(1):44–9.
- [26] McCallum R, Mohd Slim MA, Iyer A. Audit of post-operative pain scores after endoscopic and microscopic ear surgery. *Clin Otolaryngol* 2022;47(2):369–74.
- [27] Prasad SC, Giannuzzi A, Nahleh EA, Donato GD, Russo A, Sanna M. Is endoscopic ear surgery an alternative to the modified Bondy technique for limited epitympanic cholesteatoma? *Eur Arch Otorhinolaryngol* 2016;273(9):2533–40.