

## References

1. Renard S, Borentain P, Salaun E, et al. Severe pulmonary arterial hypertension in patients treated for hepatitis C with sofosbuvir. *Chest*. 2016;149(3):e69-e73.
2. Galie N, Humbert M, Vachiery JL, et al. 2015 ESC/ERS guidelines for the diagnosis and treatment of pulmonary hypertension: The Joint Task Force for the Diagnosis and Treatment of Pulmonary Hypertension of the European Society of Cardiology (ESC) and the European Respiratory Society (ERS); Endorsed by: Association for European Paediatric and Congenital Cardiology (AEPC), International Society for Heart and Lung Transplantation (ISHLT). *Eur Respir J*. 2015;46(4):903-975.
3. Savale L, Sattler C, Gunther S, et al. Pulmonary arterial hypertension in patients treated with interferon. *Eur Respir J*. 2014;44(6):1627-1634.
4. Savale L, Chaumais MC, Sitbon O, Humbert M. Pulmonary arterial hypertension in patients treated with interferon. *Eur Respir J*. 2015;46(6):1851-1853.

## Response



### To the Editor:

We would like to thank Savale et al<sup>1</sup> for their interest in our recent article in *CHEST*.<sup>2</sup> They report three additional cases of newly diagnosed pulmonary arterial hypertension (PAH) occurring during direct-acting antiviral (DAA) therapy for chronic hepatitis C virus (HCV) infection.<sup>1</sup> These observations underline the importance of systematic report of potential cardiopulmonary side effects related to DAA therapy. In their comment, Savale et al<sup>1</sup> also report safety of DAA therapy in previous known patients with PAH. They did not observe any significant hemodynamics worsening after HCV treatment completion compared with pretherapeutic assessment.<sup>1</sup> These data, collected in 13 patients, argue for a good tolerance of DAA therapy in this clinical setting. However, in our experience, we observed one case of PAH worsening occurring during DAA therapy.

A 48-year-old HIV/1a genotype HCV coinfecting cirrhotic woman with mild PAH on bosentan therapy received DAA therapy in our institution. Pretherapeutic noninvasive evaluation found World Health Organization (WHO) functional class (FC) II, systolic pulmonary arterial pressure (sPAP) estimated at 50 mm Hg, right ventricle (RV) of normal size, and brain natriuretic peptide level at 73 pg/mL. The patient started a DAA combination (sofosbuvir plus ledipasvir) for 24 weeks. Sixteen weeks after treatment initiation and 8 weeks after HCV suppression, the patient presented with dyspnea worsening (WHO FC III). Noninvasive results were sPAP at 86 mm Hg, with RV enlargement and brain natriuretic peptide level at 275 pg/mL. Despite this worsening, DAA was continued without PAH treatment modification. An early

monitoring on DAA therapy revealed a regression of PAH with WHO FC II and sPAP at 50 mm Hg with normal RV size. This regression was confirmed 1 month after DAA cessation.

The present case demonstrates that patients with PAH could experience a transient PAH worsening during DAA therapy. However, as reported here, spontaneous regression could be observed despite DAA continuation. Therefore, in accordance with Savale et al<sup>1</sup>, reported data suggest that DAA therapy remains usually safe in stable patients with PAH, but can be associated with PAH worsening. The long-term impact of DAA-induced HCV eradication in patients with PAH should be assessed.

Patrick Borentain, MD, PhD

Sébastien Renard, MD

Philippe Colson, PharmD, PhD

Marseille, France

**AFFILIATIONS:** From the Hepato-Gastroenterology, Hôpital de la Timone (Dr Borentain); Cardiology, CHU Timone (Dr Renard); and IHU Méditerranée Infection, Hôpital de la Timone (Dr Colson).

**FINANCIAL/NONFINANCIAL DISCLOSURES:** See earlier cited article for author conflicts of interest.

**CORRESPONDENCE TO:** Patrick Borentain, MD, PhD, Hôpital de la Timone - Hepato-Gastroenterology, 264 Rue St Pierre, Marseille 13385, France; e-mail: [patrick.borentain@ap-hm.fr](mailto:patrick.borentain@ap-hm.fr)

Copyright © 2016 American College of Chest Physicians. Published by Elsevier Inc. All rights reserved.

**DOI:** <http://dx.doi.org/10.1016/j.chest.2016.05.012>

## References

1. Savale L, Chaumais MC, Montani D, et al. Direct-acting antiviral medications for hepatitis C virus infection and pulmonary arterial hypertension. *Chest*. 2016;150(1):256-258.
2. Renard S, Borentain P, Salaun E, et al. Severe pulmonary arterial hypertension in patients treated for hepatitis C with sofosbuvir. *Chest*. 2016;149(3):e69-e73.

## Diagnosis of Pneumonia by Lung Ultrasound in Children and Limited Resources Subsets



### A Valuable Medical Breakthrough

#### To the Editor:

We read with a great interest the article in this issue of *CHEST* reporting the elegant and essential randomized controlled trial by Jones et al,<sup>1</sup> which challenges the “Feasibility and Safety of Substituting Lung

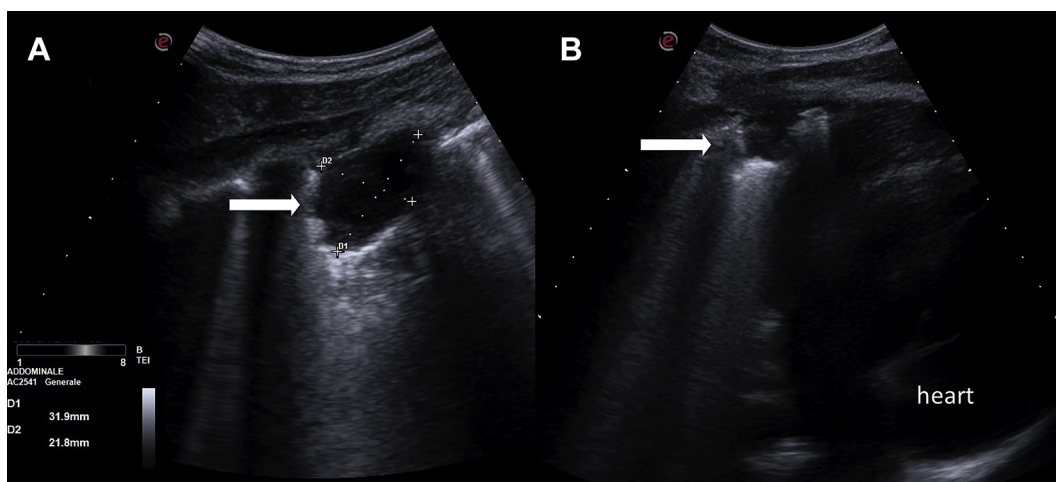


Figure 1 – A, B, Two images of the same pulmonary consolidation, with different deep setting, in a 8-year-old child referred to the ED for acute chest pain and fever. The scan was performed by a convex probe in the region of pain indicated by the patient. Chest radiograph confirmed the diagnosis of pneumonia.

Ultrasonography for Chest Radiography When Diagnosing Pneumonia in Children” by a clinical risk management approach. This contribution is particularly relevant because lung ultrasound (LUS) is an established, shared current practice.<sup>2</sup> We would respectfully add few comments. Limited resources subsets call appropriately for the dissemination and use of LUS (ie, small point-of-care hospitals or clinics; situations with serious time constraints, such as in many emergency units; either mobile or primary first aid rooms; sport or occupational medicine clinics, and units with inadequate imaging equipment).<sup>3</sup>

Moreover, the advancement of our clinical best practice by LUS is evident considering the prospect of minimizing radiation exposure of adults, but, more important, of pregnant women and children. In the past few years, referral to our emergency room with the final LUS diagnosis of pneumonia included adults, but also pregnant young women and children; the diagnosis, as a rule, was confirmed by chest x-ray (CXR) in adults and, in cases of uncertainty, in children. We would respectfully add that the association of pneumonia with even a small pleural effusion is relatively frequent in our experience; it is an easy to detect clues that are worthy of attention because they may address, concurrently with the chest area(s) abnormalities detected by physical examination and the pain possibly reported by the patient (Fig 1), to a greater focus of LUS.

We strongly agree that a “significant reduction in CXR assessment is possible when LUS is used as the

initial diagnostic imaging test. It may be feasible and safe to substitute LUS for CXR when evaluating children with suspected pneumonia.”<sup>1</sup> Nonetheless, the need for comprehensive training with an adequate duration, both in elective and emergency US procedures, is still of pivotal relevance,<sup>4,5</sup> and such expertise should be adequately guaranteed and disseminated. When LUS is used alone, one encounters limitations in nonsubpleural pneumonitis that are not accessible by US, a fact that can explain LUS pitfalls. Conversely, the smaller subpleural pneumonitis consolidation can skip the sensibility of CXR, being well visible by LUS.<sup>2</sup> Moreover, LUS is a very suitable and repeatable procedure for monitoring subpleural pneumonitis consolidation and response to therapy.<sup>2</sup>

Francesca M. Trovato, MD

Daniela Catalano, MD

Catania, Italy

**AFFILIATIONS:** From the Department of Clinical and Experimental Medicine (Drs Trovato and Catalano), The University Hospital of Catania; Accident and Emergency Department (Dr Trovato), Ospedale Civile, Ragusa, Italy; Postgraduate School of Clinical Ultrasound (Dr Catalano), University of Catania

**FINANCIAL/NONFINANCIAL DISCLOSURES:** None declared.

**CORRESPONDENCE TO:** Francesca M. Trovato, MD, Department of Clinical and Experimental Medicine, The University Hospital of Catania, via Santa Sofia 79-95123, Catania, Italy; e-mail: [trovatofrancesca@gmail.com](mailto:trovatofrancesca@gmail.com)

Copyright © 2016 American College of Chest Physicians. Published by Elsevier Inc. All rights reserved.

**DOI:** <http://dx.doi.org/10.1016/j.chest.2016.04.032>

## References

1. Jones BP, Tay ET, Elikashvili I, et al. Feasibility and safety of substituting lung ultrasonography for chest radiography when diagnosing pneumonia in children: a randomized controlled trial. *Chest*. 2016;150(1):131-138.
2. Catalano D, Trovato G, Sperandeo M, Sacco MC. Lung ultrasound in pediatric pneumonia. The persistent need of chest X-rays. *Pediatr Pulmonol*. 2014;49(6):617-618.
3. Chavez MA, Naithani N, Gilman RH, et al. Agreement between the world health organization algorithm and lung consolidation identified using point-of-care ultrasound for the diagnosis of childhood pneumonia by general practitioners. *Lung*. 2015;193(4):531-538.
4. Stolz LA, Muruganandan KM, Bisanzo MC, et al. Point-of-care ultrasound education for non-physician clinicians in a resource-limited emergency department. *Trop Med Int Health*. 2015;20(8):1067-1072.
5. Trovato FM, Musumeci G. Thoracic ultrasound limitations in the differential diagnosis of respiratory failure causes. *Chest*. 2015;148(6):e186.