

Autoimmune ear disease: clinical and diagnostic relevance in Cogan's syndrome

Luigi Maiolino,¹ Salvatore Cocuzza,¹ Angelo Conti,¹ Luisa Licciardello,¹ Agostino Serra,¹ Salvatore Gallina²

¹ENT Department, University of Catania; ²ENT Department, University of Palermo, Italy

Abstract

The autoimmune inner ear disease is a clinical syndrome with uncertain pathogenesis that is often associated to rapidly progressive hearing loss that, especially at the early stages of disease, may be at monoaural localization, although more often it is at binaural localization. It usually occurs as a sudden deafness, or a rapidly progressive sensorineural hearing loss. In this study a particular form of autoimmune inner ear disease is described, Cogan's syndrome. Cogan's syndrome is a chronic inflammatory disorder that most commonly affects young adults. Clinical hallmarks are interstitial keratitis, vestibular and auditory dysfunction. Associations between Cogan's syndrome and systemic vasculitis, as well as aortitis, also exist. We report a case of a young woman who presented audiological and systemic characteristics attributable to Cogan's syndrome. In the description of the case we illustrate how the appearance and evolution of the disease presented.

Introduction

The autoimmune inner ear disease (AIED) is a clinical syndrome with uncertain pathogenesis that is often associated to rapidly progressive hearing loss that, especially in the early stages of disease, may be at monoaural localization, although more often it is at binaural localization. It usually occurs in the form of sudden deafness or a rapidly progressive sensorineural hearing loss.¹ Hearing loss in idiopathic form may be associated with vestibular

disease. Autoimmune inner ear disease consists of a heterogeneous group of disorders that characterize the clinical presentation and immunologic reactivity of inner ear components.

The immune dysfunction of patients with AIED has been studied using the lymphocyte transformation tests, immunofluorescence techniques, Western blot and countless amount of antigen. Among these analyzes, the Western blot test is widely used to diagnose AIED and to set the therapeutic range suitable.²

The immune system is a particularly complex system and it may cause damage in different ways to the various components of the inner ear. Many systemic diseases may be associated with Cogan's syndrome, such as: ankylosing spondylitis; systemic lupus erythematosus; Sjogren's syndrome; ulcerative colitis; Wegener's granulomatosis; rheumatoid arthritis; scleroderma; psoriatic arthritis.³

Humoral and cell-mediated mechanisms are involved in the pathogenesis of autoimmune inner ear disease. Cochlear innate immunity has been proposed to contribute to the initiation of a local adaptive immune response following antigen challenge. Briefly, as a consequence of a yet undefined trigger damaging the inner ear, lymphocytes from the systemic circulation are exposed to proteins of the cochlea.

Immune cells pass from the systemic circulation, through the blood-labyrinthine barrier, to reach the endolymphatic sac. Specifically, the vessels of the spiral modiolar vein, adjacent to the scala tympani, appears to be the initial entry site of lymphocyte cells in the inner ear. Chronic activation of helper T lymphocytes reactive against self-proteins leads to the destruction of sensory and supporting cells within the cochlea. IL-1 α , IL-2, TNF- α and NF- κ B, cytokines essential in the initiation, modulation and amplification of the immune response, are expressed by infiltrating cells in the endolymphatic sac.⁴

Many studies in animal models have led to the hypothesis that in the pathogenesis of autoimmune hearing loss you can achieve a cytotoxic antibody-mediated damage (type II response) or immune complex-mediated damage (type III response). In the serum of approximately 70% of patients with sudden sensorineural hearing Loss (SSHL) of unknown aetiology, it is possible to find antibodies capable of immunostaining human inner ear tissues. Autoantibodies against type II collagen, type IX collagen, Raf-1 protein, the major peripheral myelin protein P0, B-actin, cochlin, choline transporter-like protein 2 (CTL2), cell-density enhanced protein tyrosine phosphatase-1 and connexin 26 have all been described in AIED. The stria vascularis, fibrocytes of the spiral ligament and supporting cells are the anatomical targets of those autoantibodies.⁵

Sometimes in pathogenic dynamics of such forms it is possible to detect a common denominator with diseases from autoimmune disorder and pathological conditions involving cellular oxidative stress.⁶⁻¹¹

Correspondence: Luigi Maiolino, ENT Department, Azienda Ospedaliera Universitaria Policlinico Vittorio Emanuele, University of Catania, via Santa Sofia 78, 95123 Catania, Italy.
Tel.: +39.095.3781093 - Fax: +39.095.7335738.
E-mail: maiolino@policlinico.unict.it

Key words: Autoimmune ear disorder; Cogan's syndrome; Hearing loss.

Received for publication: 11 August 2016.

Revision received: 2 January 2017.

Accepted for publication: 2 January 2017.

This work is licensed under a Creative Commons Attribution NonCommercial 4.0 License (CC BY-NC 4.0).

©Copyright L. Maiolino et al., 2017
Licensee PAGEPress, Italy
Audiology Research 2017;7:162
doi:10.4081/audiore.2017.162

In this context, a particular form of autoimmune inner ear disease is represented by Cogan's syndrome (CS).¹²

Cogan's syndrome is a chronic inflammatory disorder that most commonly affects young adults. Clinical hallmarks are interstitial keratitis, vestibular and auditory dysfunction. Associations between CS and systemic vasculitis, as well as aortitis, also exist.¹³

The mechanisms responsible for the eye and inner ear disease in Cogan's syndrome are unknown. Some evidence suggests that the disease is a result of inner ear autoimmunity. A few patients display reactivity against antigens expressed in the inner ear. These antigens share sequence homology with Ro/SSA autoantigen, laminin, cell density-enhanced protein tyrosine-1 (DEP-1/CD148), connexin 26, and the reovirus III major core protein lambda1.¹⁴

In animals, passive transfer of the autoantibodies reproduced features of CS in mice; this supports a hypothesis that infection, perhaps from reovirus type III, may be involved in triggering this autoimmune disease through molecular mimicry. This is further supported by the observations that one-quarter to one-third of patients with CS have an antecedent viral-like illness.^{15,16}

In addition, antibodies to Hsp-70 have been detected in some patients with CS and other forms of autoimmune sensorineural hearing loss.

Case Report

The female patient, aged 25, has come to our attention to the sudden appearance of monaural hearing loss, in the right ear, and dizzying acute syndrome two days before.

The anamnestic survey also revealed the presence of right ear tinnitus, started with hearing loss, in conjunction with febrile episodes (~39°C) and visual disturbances, which instead were insurgents about a month before and for which diagnosis was made of conjunctivitis.

The vestibular examination showed the reduction of the right labyrinthine function: *Videooculography*: presence of spontaneous, second-degree, horizontal nystagmus, with fast phase directed to

the left, inhibited by visual fixation; *Untenberger test*: presence of rotation to right side; *Romberg test*: positivity to the test; *Caloric test (ENG)*: iporesponsivity of right vestibular system.

The audiological evaluation showed: *Tonal audiometric examination*: presence of sensorineural hearing loss in right ear, mainly for medium and high frequencies. Normal hearing in left ear (Figure 1); *Impedometric examination*: tympanogram type A bilaterally and positivity of Metz's test in right ear, indicative of cochlear suffering; *ABR examination*: deconstructed track, using 120 dB SPL click stimulus, in right ear; normal track, with regular attendance of the waves, in left ear.

At that stage it was placed diagnosis of sudden hearing loss with vestibular impairment in right ear.

They were administered vasoactive and neurotrophic drugs for ten days. At the follow up, after ten days, was highlighted the disappearance of the vertiginous state, persistent moderate imbalance, and an improvement of auditory function in right ear (Figure 2).

The patient was advised to continue vasoactive and neurotrophic therapy for further seven days. The patient after 7 days to follow up reported a further deterioration of hearing loss in right ear, with the average loss values greater than those of the initial event. The patient also reported a subjective feeling of frequent changes in hearing sensitivity, independent of ponderable factors. A condition of imbalance persisted, without vertiginous state.

The diagnostic evaluation therefore provided viral titrations for *Herpes simplex virus*, *Cytomegalovirus*, *Herpes Zoster virus*, Syphilis and Lyme disease. These tests were negative for infection either past or present.

Cerebral magnetic resonance (high-resolution) imaging showed normal MRI findings.

It has been advanced the hypothesis of a condition of hydrops endolymphatic, which is why then administered depletional therapy and recommended a low-salt diet. After twenty days, at new follow-up, stationary hearing condition and phenomena of disequilibrium were found. Then were carried out a new eye examination and blood tests, aimed at the study of the immune profile.

The eye examination revealed the presence of keratitis in both eyes, while a significant increase was highlighted in blood chem-

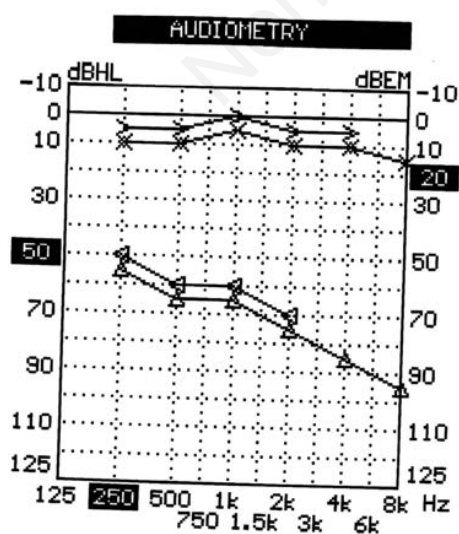


Figure 1. Tonal audiometric examination at first time.

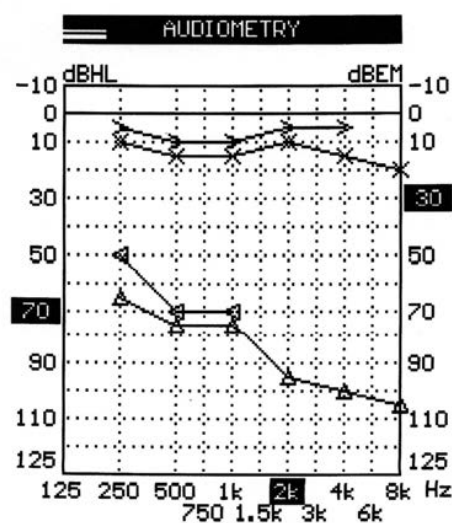


Figure 2. Tonal audiometric examination at first follow up.

istry tests of white blood count, erythrocyte sedimentation rate and CRP. The values of complement C3 and C4 and radial immunodiffusion were out of norm and there was positivity of the anti-Hsp70 antibody test. On the basis of the findings it was assumed typical Cogan's syndrome, which is why the patient was started at Division of Clinical Immunology where she began intravenously corticosteroid therapy in high doses for ten days and then continued with oral steroid therapy, at low doses, in combination with methotrexate, cyclophosphamide, cyclosporine, folin, acetylsalicylic acid.

The patient is then subjected to control after 40 days, and then after 2 months.

The first and second follow up showed no particular changes on the side of audiology, although extrauditive manifestations were improved.

Discussion

The present study describes the clinical evolution and long-term follow-up of patient suffering from Cogan's syndrome.

Cogan's syndrome is a rare autoimmune vasculitis, and its pathogenesis is unknown. Infection, but primarily autoimmunity, may play contributing roles in the pathogenesis of this disease. It is characterized by ocular and audiovestibular symptoms similar to those of Meniere's syndrome. Approximately 70% of patients have systemic disease, of which vasculitis is considered the pathological mechanism. The immunologic theory is based on the release of auto-antibodies against corneal, inner ear and endothelial antigens, and of anti-nuclear cytoplasmic auto-antibodies (ANCA).¹⁷

The etiology and mechanism of Cogan's syndrome remain unknown. Exposure to a toxic substance preceded symptom onset in several patients but it was primarily the possible triggering role of an infection, present in 30% of the cases in the weeks preceding ocular or audiovestibular symptomatology, that is evoked.

In our patient, elevated white blood count, erythrocyte sedimentation rate and CRP as well as some non-specific alterations of the complement system, positivity of the anti-Hsp70 antibody test were the only notable abnormal laboratory parameters. These findings, often noticed in inflammatory processes, however, are non-specific. Only when cardinal symptoms, cochleovestibular and eye disease, are present does the clinical diagnosis of Cogan's syndrome becomes obvious. The diagnostic mainstay is to verify the presence of interstitial keratitis.

Cogan's syndrome should always be considered in patients presenting a progressive hearing loss associated with ocular inflammations. According to the findings of this study, early recognition of Cogan's syndrome and rapid initiation of combined immunosuppressive therapy, such as corticosteroids and cyclophosphamide, seem to be important in preventing persistent deafness. Whether systemic complications and a fatal outcome also can be prevented still remains unanswered.

Conclusions

The nosology of Cogan's syndrome remains poorly defined. The boundaries between this disease and immunological deafness or systemic diseases affecting the eye and ear remain to be established. The etiology and mechanisms of Cogan's syndrome are unknown: the role of triggering factors - perhaps infectious - has been evoked, as have immunological reactions directed against constituents of the eye and/or inner ear.

The succession of symptoms described in the case reported in the present study raises early stage of considerable diagnostic doubts. Few aspects of the case in question in fact differ from similar events to sudden hearing loss, as vestibular neuronitis, as Meniere's disease.

Unique different element was the fever, even if such a symptom not typifies the disease in question.

It is important in such cases that, in relation also to the young age, is suspected an immune disorder, type of Cogan's syndrome, so that the establishment of appropriate therapy can control the clinical evolution

No biological test is available at present to affirm the diagnosis of the disease.

Treatment is poorly codified: the modalities of cortico-therapy and recourse to other therapeutic agents, notably immune-suppressants, in the case of cortico-resistance or cortico-dependence merit new studies.

References

1. Broughton SS, Meyerhoff WE, Cohen SB. Immune-mediated inner ear disease: 10-year experience. *Semin Arthritis Rheum* 2004;34:544-8.
2. Ruckenstein MJ. Autoimmune inner ear disease. *Curr Opin Otolaryngol Head Neck Surg* 2004;12:426-30.
3. Gaubitz M, Lübben B, Seidel M, et al. Cogan's syndrome: organ-specific autoimmune disease or systemic vasculitis? A report of two cases and review of the literature. *Clin Exp Rheumatol* 2001;19:463-9.
4. Gluth MB, Baratz KH, Matteson EL, Driscoll CL. Cogan syndrome: a retrospective review of 60 patients throughout a half century. *Mayo Clin Proc* 2006;81:483-8.
5. Lunardi C, Bason C, Leandri M, et al. Autoantibodies to inner ear and endothelial antigens in Cogan's syndrome. *Lancet* 2002;360:915-21.
6. Calabrese V, Cornelius C, Maiolino L, et al. Oxidative stress, redox homeostasis and cellular stress response in Ménière's disease: Role of vitagenes. *Neurochem Res* 2010;35;12:2208-17.
7. Matin N, Tatabase O, Falsaperla R, et al. Epilepsy and innate immune system: a possible immunogenic predisposition and related therapeutic implications. *Hum Vaccine Immunother* 2015;11;2021-9.
8. Dattilo S, Mancuso C, Koverech G, et al. Heat shock protein and hormesis in the diagnosis and treatment of neurodegenerative disorders. *Immun Ageing* 2015;4:12-20.
9. Vitaliti G, Tatabaie O, Matin N, et al. The usefulness of immunotherapy in pediatric neurodegenerative disorders: a systematic review of literature data. *Hum Vaccine Immunother* 2015;11;2749-63.
10. Trovato A, Siracusa R, Di Paola R, et al. Redox modulation of cellular stress response and lipoxin A4 expression by Coriolus versicolor in rat brain: relevance to Alzheimer's disease pathogenesis. *Immun Ageing* 2016;53;350-8.
11. Di Mauro P, Cocuzza S, Licciardello L, et al. Auditory function in patients with Charcot-Marie-Tooth syndrome. *Acta Med Mediterr* 2016;32;1719-22.
12. Pleyer U, Baykal HE, Rohrbach JM, et al. Cogan's syndrome: too often detected too late? A contribution to early diagnosis of Cogan's syndrome. *Klin Monatsbl Augenheilkd* 1995;207:3-10.
13. Cundiff J, Kansal S, Kumar A, et al. Cogan's syndrome: a cause of progressive hearing deafness. *Am J Otolaryngol*

- 2006;27:68-70.
14. Grasland A, Pouchot J, Hachulla E, et al. Study Group for i Cogan's Syndrome. Typical and atypical Cogan's syndrome: 32 cases and review of the literature. *Rheumatology (Oxford)* 2004;43:1007-15.
 15. Selivanova O, Haxel BR, Mann WJ. Cogan's syndrome: a diagnostic challenge. *HNO* 2006;54:619-23.
 16. Scalia G, Palermo CI, Maiolino L, et al. Detection of serum IgA to HSV1 and its diagnostic role in sudden hearing loss. *New Microbiol* 2013;36:41-7.
 17. Gluth MB, Baratz KH, Matteson EL, et al. Cogan syndrome: a retrospective review of 60 patients throughout a half century. *Mayo Clin Proc* 2006;81:483-8.

Non commercial use only