

ORIGINAL ARTICLE

Correspondence:

Giorgio Ivan Russo, Urology Section, Department of Surgery, University of Catania, 95125 Catania, Italy.

E-mail: giorgioivan@virgilio.it

Keywords:

hyaluronic acid, intralesional therapy, Peyronie's disease, verapamil


Received: 28-Nov-2016

Revised: 3-Mar-2017

Accepted: 23-Mar-2017

doi: 10.1111/andr.12368

Evaluation of intralesional injection of hyaluronic acid compared with verapamil in Peyronie's disease: preliminary results from a prospective, double-blinded, randomized study

¹V. Favilla, ¹G. I. Russo , ²A. Zucchi, ³G. Siracusa, ¹S. Privitera, ¹S. Cimino, ²M. Madonna, ⁴T. Cai, ⁵G. Cavallini, ⁶G. Liguori, ⁷G. D'Achille, ⁸M. Silvani, ⁹G. Franco, ¹⁰P. Verze, ¹⁰A. Palmieri, ¹¹B. Torrisi, ¹⁰V. Mirone and ¹G. Morgia

¹Urology Section, Department of Surgery, University of Catania, Catania, Italy, ²Department of Urology and Andrology, University of Perugia, Perugia, Italy, ³Department of Urology, University of Sassari, Sassari, Italy, ⁴Urology Unit, Santa Chiara Regional Hospital, Trento, Italy, ⁵Medicitalia Andrology Section, Outpatient Clinic of Ferrara, Ferrara, Italy, ⁶Urology Unit, Cattinara Hospital, Trieste, Italy, ⁷Urology Unit, San Giacomo Hospital, Monopoli, Italy, ⁸Urology Unit, Hospital "degli Infermi", Biella, Italy, ⁹Urology Department, University "La Sapienza", Rome, Italy, ¹⁰Urology Department, University of Naples Federico II, Naples, Italy, and ¹¹Department of Statistics, University of Catania, Catania, Italy

SUMMARY

Several intralesional therapeutic protocols have been proposed for the treatment of Peyronie's disease. Among all, hyaluronic acid (HA) and verapamil have been differently tested. We aimed to evaluate the efficacy of intralesional verapamil (ILVI) compared with intralesional HA in patients with early onset of Peyronie's disease (PD). This is a multi-centre prospective double-arm, randomized, double-blinded study comparing ILVI vs. intralesional HA after 12-weeks. Sexually active men, older than 18 years and affected by the acute phase of PD were eligible for this study. Patients have been double-blinded randomly divided into two groups (1 : 1 ratio): Group A received intralesional treatment with Verapamil (10 mg in 5 mL of normal saline water) weekly for 12 weeks, while group B received intralesional treatment with HA (0.8% highly purified sodium salt HA 16 mg/2 mL) weekly for 12 weeks. The primary efficacy outcome was the change from the baseline to the endpoint (12 weeks after therapy) for the penile curvature (degree). The secondary outcome was the change in the plaque size and in the International Index of erectile Function (IIEF-5) score. The difference between post- and pre-treatment plaque size was -1.36 mm (SD ± 1.27) for Group A and -1.80 mm (SD ± 2.47) for Group B (p -value = NS). IIEF-5 increased of 1.46 points (SD ± 2.18) in Group A and 1.78 (SD ± 2.48) in Group B (p -value \pm NS). No difference in penile curvature was observed in Group A, while in Group B the penile curvature decreased of 4.60° (SD ± 5.63) from the baseline ($p < 0.001$) and vs. Group A. According to PGI-I results, we found significant difference as concerning patient global impression of improvement (PGI-I) (4.0 vs. 2.0; $p < 0.05$). This prospective, double-arm, randomized, double-blinded study comparing ILVI vs. HA as intralesional therapy showed greater efficacy of HA in terms of penile curvature and PGI-I.

INTRODUCTION

Peyronie's disease (PD) is an acquired fibrotic disorder of unknown pathophysiology, characterized by the deposition of collagen and fibrin in the form of plaque on the tunica albuginea of the penis, resulting in penile deformity, penile pain, erectile dysfunction and distress (Brock *et al.*, 1997) with a significant negative impact on patients quality of life. The efficacy of medical management of PD is difficult to determine because of the

lack of proper studies. These therapeutic options include: oral treatment (potassium *para*-aminobenzoate, Potaba), vitamin E, colchicine, tamoxifen, carnitine, pentoxifylline, phosphodiesterase type 5 inhibitors); intralesional treatment [steroids, verapamil, collagenase clostridium histolyticum (CCh), interferons]; and topical treatment [extracorporeal shock wave therapy (ESWT), iontophoresis, traction devices and vacuum devices] (Hauk *et al.*, 2006; Safarinejad *et al.*, 2010; Hatzimouratidis

et al., 2012; Gelbard *et al.*, 2013; Favilla *et al.*, 2014; Levine *et al.*, 2015; Nehra *et al.*, 2015). However, these compounds have been found to produce the potential occurrence of mild to severe adverse events, including penile ecchymosis, swelling, pain, and corporal rupture with collagenase; in addition, therapy with collagenase is limited by the high cost of the compound (Nehra *et al.*, 2015). For this reason, the intralesional therapy with verapamil, for reduced side effects and lower costs, remains the most widely used especially in Europe. For this reason novel intralesional agents are strongly needed with better benefit–risk profile. Recent prospective, multicenter, pilot study assessing the efficacy of hyaluronic acid (HA) as intralesional treatment for patients with PD showed encouraging preliminary results for improvement of plaque size, penile curvature, and overall sexual satisfaction (Zucchi *et al.*, 2016) and similar results are reported in other study (Gennaro *et al.*, 2015). Hyaluronic acid is an extracellular matrix glycosaminoglycan that at physiological pH is highly polarized and maintains hydration, turgor, plasticity and viscosity in the amorphous connective tissue matrix. It also have an antioxidant and anti-inflammatory effect, well defined in osteoarthritis where it decreases oxygen-free radicals in the synovial fluid, inhibits apoptosis, promotes cell survival and decreases concentrations of inflammatory proteins (Yu *et al.*, 2014). Blocking the effects of substances that generate inflammation and oxidative stress, HA is also efficacious in decreasing scar formation and for this reason it is used widely in numerous medical applications, including cosmetic and orthopaedics surgery (Yu *et al.*, 2014). Although the efficacy of intralesional HA has been evaluated in two prospective studies, however there are no comparative data with intralesional verapamil, considered one of the standard treatments of PD.

Aim

The aim of this study was to evaluate the efficacy and tolerability of intralesional verapamil (ILVI) compared with intralesional HA in patients with early onset of PD.

MATERIALS AND METHODS

This is a multi-centre prospective double-arm, randomized, double-blinded study comparing ILVI injection vs. intralesional HA injection after 12-weeks of follow-up.

Patients were enrolled from 11 Italian andrology centres and pre-treatment clinical evaluations were carried out by urologists experienced with PD management. Sexually active men International Index of erectile Function (IIEF-5 > 11) older than 18 years and affected by the acute phase of PD were eligible for this study. Study criteria included patients with acute inflammatory phase of the disease with duration of the disease <12 months associated with a soft nodule or plaque and/or painful erection and/or a recent change in penile curvature. Exclusion criteria were: patients at the chronic or fibrotic stage of PD, previous medical, surgical and EWST treatment for PD, calcified plaques or hourglass deformity as defined at duplex Doppler ultrasonography, severe concomitant ED (IIEF score <7), any medical treatment for ED before or during the study, severe penile curvature incompatible with sexual intercourse.

Pre-treatment workup

All patients underwent Duplex Doppler ultrasonography in the basal condition and after the induction of penile erection with

the assistance of an intracavernous injection of alprostadil 10 µg/mL. Repeat dosing was administered to a maximum of 20 µg/mL until full erectile rigidity was achieved. All procedures were performed by the same experienced operator at each centre. Plaque size was measured according to the longest diameter (mm) and plaque position was assessed as follow: proximal, medial, distal or septum. The degree of penile curvature was evaluated during a full erection using a goniometer protractor. Bending side was described as dorsal, right-dorsal, left-dorsal, left-lateral, right-lateral, ventral.

After preliminary evaluation for eligibility (including medical and sexual history, physical examination, and self-administration of IIEF-5 questionnaires) enrolled patients have been double-blinded randomly divided in two groups (according to a computer-generated random sequence with a 1 : 1 ratio): Group A received intralesional treatment with Verapamil (10 mg in 5 mL of normal saline water) weekly for 12 weeks, while group B received intralesional treatment with HA (0.8% highly purified sodium salt HA 16 mg/2 mL; Sinovial, IBSA, Lodi, Italy) weekly for 12 weeks. Before treatment, all the patients underwent local anesthesia (dorsal nerve penile block) by 1% plain lidocaine injection at the base of the penis. Intralesional injections with Verapamil or HA were delivered into the plaque in the tunica albuginea avoiding dorsal vein or urethra puncture using a 21-gauge needle. Treatment was administered weekly for 12 weeks. Adverse events were monitored on the light of Common Terminology Criteria for Adverse Events (CTCAE) guidelines.

Main outcomes measures

The primary efficacy outcome was the change from the baseline to the endpoint (12 weeks after therapy) for the penile curvature (degree). The secondary outcome was the change of plaque size (mm) and of the IIEF-5 score. All patients provided written informed consent in accordance with the Declaration of Helsinki, and the Human Ethics Committee approved the study protocol (ethics committee of Catania University, Catania, Italy).

Twelve weeks after the end of therapy, penile curvature and plaque size were re-evaluated with Duplex Doppler ultrasonography as described earlier and IIEF-5 was administrated again. The results were compared with the pre-treatment values and between the two groups. The Patient Global Impression of Improvement (PGI-I) questionnaire was used to ask the patient to describe the changes from the baseline after treatment (Viktrup *et al.*, 2012). Answers was given on a seven-point scale (1 = a lot better, 2 = much better, 3 = a little better, 4 = no change, 5 = a little worse, 6 = much worse, 7 = a lot worse).

Statistical analysis

The study sample of 140 was powered for an approximately 0.5-point difference in the reduction in plaque size using a two-sided type I error = 0.05 and type II error = 0.1 (90% power), requiring 60 patients per group. The maximum sample size was set to 70 subjects per group, allowing for a 15% drop-out rate.

Changes from baseline to end of therapy in plaque size, penile curvature and IIEF-5 score were analysed using ranked one-way analysis of variance (ANOVA) with a term for treatment group.

Treatment group differences in primary and secondary end points were determined using post hoc analysis. Data were reported as means ± standard deviation (SD) or median, and nominal *p*-values were presented. Multivariate logistic

regression analysis has been conducted to verify significant predictors of 10° of reduction in penile curvature after treatment. All tests were completed using IBM SPSS Statistics ver. 20.0 (IBM Co., Armonk, NY, USA) and for all statistical comparisons significance was considered as $p < 0.01$.

RESULTS

Overall, 201 patients with acute phase of PD were screened. All patients described the onset of PD as pain, tension, or 'tingling' during erection, curvature, and/or erectile dysfunction and had at least one palpable plaque on the shaft at physical examination. Of these, 140 patients met the inclusion criteria and were randomly divided in two treatment groups: Group A received intralesional Verapamil, while Group B received intralesional HA. 132 patients completed the treatment cycle (69 in Group A and 63 in Group B) and attended the follow-up visit (12 weeks after the end of therapy) with seven patients lost at follow-up (Fig. 1). Table 1 presents the demographics and clinical data of the study groups. Mean age was 57.46 years (SD ± 10.19) for Group A and 55.14 (SD ± 10.94) for Group B. At baseline, mean plaque size was 10.13 mm (SD ± 4.90) for Group A and 11.44 mm (SD ± 5.53) for Group B; mean curvature was 33.77 (SD ± 6.44) for Group A and 32.22 (SD ± 10.54) for Group B and mean IIEF-5 score was 19.22 (SD ± 5.25) for Group A and 19.44 (SD ± 3.95) for Group B. Table 2 lists the results after treatment expressed as mean difference ± SD. The difference between post- and pre-treatment plaque size was -1.36 mm (SD ± 1.27) for Group A and -1.80 mm (SD ± 2.47) for Group B (p -value = NS between groups). IIEF-5 increased of 1.46 points (SD ± 2.18) in Group A and 1.78 (SD ± 2.48) in Group B (p -value = NS between groups). The changes after treatment in plaque size and IIEF-5 were statistically significant in both groups ($p < 0.001$). PGI-I was 3.53 (SD ± 0.57) for Group A and 3.13 (SD ± 1.535) for Group B. No difference in penile curvature was observed in Group A, while in Group B the penile curvature decreased of 4.60° (SD ± 5.63) from the baseline ($p < 0.001$) and vs. Group A ($p < 0.001$). According to PGI-I results, we found significant difference as concerning PGI-I (4.0 vs. 2.0; $p < 0.05$). At the multivariate logistic regression analysis, adjusted for comorbidities, age and characteristics at baseline, intralesional treatment with HA was associated with decrease in 10 degree of curvature [OR = 6.8 (95% CI 1.5-9.7); $p < 0.05$]. No injection-site ecchymosis or hematomas were observed. No local or systemic drug reactions were noted.

Figure 1 Flow diagram of included patients. [Colour figure can be viewed at wileyonlinelibrary.com].

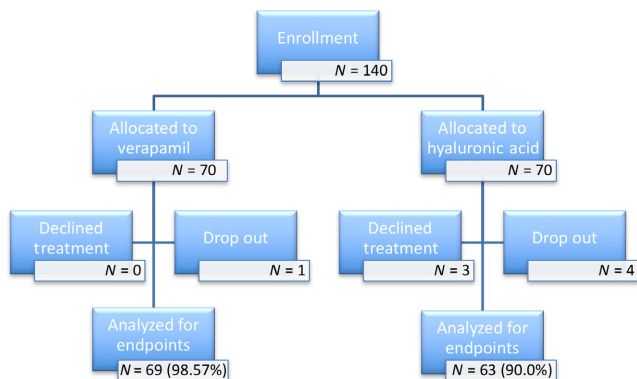


Table 1 Baseline characteristics of the patients

	Group A Verapamil	Group B Hyaluronic acid	p-Value
Patients, n	69	63	–
Age, year, mean ± SD	57.46 ± 10.19	55.14 ± 10.93	0.80
Smokers, n (%)	35 (50.7)	34 (54.0)	0.75
Incurvation side, n (%)			
Dorsal	21 (30.4)	24 (38.1)	0.66
Ventral	7 (10.1)	5 (7.9)	
Right Lateral	14 (20.3)	10 (15.9)	
Left Lateral	14 (20.3)	9 (14.3)	
Right Lateral-dorsal	7 (10.1)	8 (12.7)	
Left Lateral-dorsal	6 (8.7)	7 (11.1)	
Plaque position, n (%)			
Proximal	20 (29.0)	20 (31.7)	0.63
Medium	26 (37.7)	23 (36.5)	
Distal	15 (21.7)	12 (19.0)	
Septum	8 (11.6)	8 (12.7)	
Plaque extension, mm, mean ± SD	10.13 ± 4.90	11.44 ± 5.53	0.43
Penile curvature, degrees, mean ± SD	33.77 ± 6.44	32.22 ± 10.54	0.40
Entity of curvature, n (%)			
10°	4 (6.3)	0 (0.0)	0.30
20°	2 (3.2)	3 (4.3)	
30°	34 (54.0)	40 (58.0)	
40°	19 (30.2)	23 (33.3)	
50°	4 (6.3)	3 (4.3)	
IIEF-5 score, mean ± SD	19.22 ± 5.25	19.44 ± 3.95	0.51

Table 2 Mean changes of primary outcomes between groups from baseline to final follow-up

	Verapamil	Hyaluronic acid
Plaque extension, mm, mean difference ± SD	-1.36 ± 1.27 ^b	-1.80 ± 2.47 ^b
Penile curvature, degrees, mean difference ± SD	0.00 ± 0.00	-4.60 ± 5.63 ^{a,b}
IIEF-5 score, mean difference ± SD	1.16 ± 1.94 ^b	1.78 ± 2.48 ^b
PGI-I	3.53 ± 0.57	3.13 ± 1.53

^a $p < 0.001$ vs. Group A. ^b $p < 0.001$ vs. same Group baseline.

DISCUSSION

Peyronie's disease has been treated with some success by intralesional injection of different drugs, particularly when patients are in the early, painful, progressive stages, do not have calcified plaques and have a short case history. Intralesional injections of verapamil was introduced by Levine *et al.* (1994), this calcium antagonist, reducing calcium-dependent collagen transport and collagenase activities, seems to have the capacity to slow, prevent, or even reverse plaque formation and the progression of PD (Levine & Estrada, 2002). Since then, studies have assessed the efficacy of ILVI for PD but have yielded mixed results (Levine, 1997; Shirazi *et al.*, 2009). While initial reports showed significant improvements in curvature (Levine *et al.*, 1994), later studies failed to display similar significant outcomes (Rehman *et al.*, 1998). Intralesional treatment with Verapamil has been investigated as part of multimodal therapies for the management of PD. In a recent prospective randomized controlled trial, an additional benefit in terms of pain resolution and improvement in sexual function was observed when verapamil was offered with an oral anti-oxidant, compared to intralesional

verapamil alone (Favilla *et al.*, 2014). The association of intralesional verapamil and tadalafil showed better pain control while reducing penile curvature and erectile function, improving the quality of life, in a prospective randomized study (Dell'Atti, 2015). In a not-randomized study (Bennett *et al.*, 2007) 94 patients were treated with six intralesional verapamil injections on alternating weeks. Penile pain was alleviated in all patients and 18% showed decreased curvature. However, a randomized, single-blinded, placebo-controlled trial comparing intralesional Verapamil with saline showed no significant difference or improvement in penile curvature, pain, plaque features, or sexual function (Shirazi *et al.*, 2009). Major flaws have been highlighted in all verapamil trials, including a lack of standardized measurement tools, a lack of pain assessment, short follow-up periods, and small sample sizes (Mitropoulos *et al.*, 2012). Furthermore, In a small-sample, randomized, controlled trial, no differences were found between the placebo and verapamil groups regarding penile pain, plaque size, or penile curvature (Shirazi *et al.*, 2009). Because of a lack of systematic evidence, the role of ILIV in PD has not yet been adequately defined (Hatzimouratidis *et al.*, 2012). In December 2013 collagenase clostridium histolyticum (CCh/Xiaflex) was approved by the US Food and Drug Administration (FDA) for treatment of Peyronie's disease. Currently, Xiaflex it is the only drug available for treatment of Peyronie's disease (Gelbard *et al.*, 2013). However, this compound has been found to produce the potential occurrence of mild to severe adverse events, including penile ecchymosis, swelling, pain, and corporal rupture (Gelbard *et al.*, 2013). In addition, therapy with collagenase is limited by the high cost. Based on currently available scientific evidence, the intralesional agent presenting the optimal benefit-risk ratio is far from determined, and further research of novel intralesional agents is strongly needed. Hyaluronic acid is the predominant glycosaminoglycan (GAG) in 'amorphous ground substance' of connective tissue. It consists of glucuronic acid and *N*-acetylglucosamine, held together by β -glycosidic bonds. HA is present at high concentrations in the tunica albuginea and controls the distribution of nutrients in the connective tissue as a result of its hydrating action. Furthermore, HA counteracts the effect of inflammatory cytokines (Karna *et al.*, 2006). In cosmetic and orthopedics surgery, HA has been shown to be efficacious in decreasing scar formation and blocking the effects of substances that generate inflammation and oxidative stress (Takahashi *et al.*, 2000). Intralesional treatment with HA decreased plaqued size and penile curvature and improved IIEF in a prospective, single arm, self-controlled, interventional, multicentre pilot study on 65 patients (Zucchi *et al.*, 2016). Similar results were reported by another study including 83 patients who underwent treatment with HA vs. 81 patients in the control group (Gennaro *et al.*, 2015). At 12 month follow up all treated patients experienced three statistically significant outcomes: reduction in plaque size, improvement in penile curvature and IIEF. Furthermore, the improvements remained substantially stable at 24 months follow up. Although the latter is a case-control study, however, there are no comparative data with intralesional verapamil, considered one of the standard treatments of acute phase of PD. Currently this is the first study comparing intralesional Verapamil with intralesional HA. The results of our study showed that HA as intralesional therapy exhibited greater efficacy in terms of penile curvature and patient satisfaction

compared to ILVI. Although HA is more expensive than verapamil (25 € vs. 3 €), compared with other intralesional therapy, the cost of HA is certainly lower than that of collagenase and compared to the latter treatment, the use of intralesional HA as well as observed with intralesional verapamil, it's characterized by the absence of significant side effects and good level of patients compliance. For these reasons, intralesional HA could represent a new therapeutic strategy to treating acute phase of PD.

Nevertheless, the limitations to this study must be considered when interpreting the results. First, the lack of a controlled group treated with placebo and the short follow-up (12 weeks) could have limited interpretation of data. Second, the study was not designed as non-inferiority trial. Finally, the inter variability among measurement of plaque size in the 11 centres could have represented a bias. Further prospective, randomized, placebo-controlled studies with larger patient cohorts stratified by disease stage are sorely needed to establish the real impact of intralesional therapeutic option for early-stage PD, other than confirming the high treatment tolerability.

CONCLUSION

This prospective, double-arm, randomized, double-blinded study showed greater efficacy of HA in terms of penile curvature and patients satisfaction compared to ILVI. Although plaque size and overall sexual satisfaction improved with both therapies, better outcomes were observed in patients treated with HA. In this group of patients, a decrease in penile curvature was also described. Hyaluronic acid seems more advisable also because it has a lower risk of adverse effects compared to the other molecules used 'off-label' for intralesional therapy. The best intralesional treatment for patients with PD has not been detected yet and more studies are needed even to test combination therapies.

REFERENCES

- Bennett NE, Guhring P & Mulhall JP. (2007) Intralesional verapamil prevents the progression of Peyronie's disease. *Urology* 69, 1181–1184.
- Brock G, Hsu GL, Nunes L, von Heyden B & Lue TF. (1997) The anatomy of the tunica albuginea in the normal penis and Peyronie's disease. *J Urol* 157, 276–281.
- Dell'Atti L. (2015) Tadalafil once daily and intralesional verapamil injection: a new therapeutic direction in Peyronie's disease. *Urol Ann* 7, 345–349.
- Favilla V, Russo GI, Privitera S, Castelli T, Madonia M, La Vignera S, Condorelli R, Calogero AE, Farina FP, Cimino S & Morgia G. (2014) Combination of intralesional verapamil and oral antioxidants for Peyronie's disease: a prospective, randomised controlled study. *Andrologia* 46, 936–942.
- Gelbard M, Goldstein I, Hellstrom WJ, McMahon CG, Smith T, Tursi J, Jones N, Kaufman GJ & Carson CC 3rd. (2013) Clinical efficacy, safety and tolerability of collagenase clostridium histolyticum for the treatment of peyronie disease in 2 large double-blind, randomized, placebo controlled phase 3 studies. *J Urol* 190, 199–207.
- Gennaro R, Barletta D & Paulis G. (2015) Intralesional hyaluronic acid: an innovative treatment for Peyronie's disease. *Int Urol Nephrol* 47, 1595–1602.
- Hatzimouratidis K, Eardley I, Giuliano F, Hatzichristou D, Moncada I, Salonia A, Vardi Y, Wespes E & European Association of U. (2012) EAU guidelines on penile curvature. *Eur Urol* 62, 543–552.
- Hauck EW, Diemer T, Schmelz HU & Weidner W. (2006) A critical analysis of nonsurgical treatment of Peyronie's disease. *Eur Urol* 49, 987–997.

- Karna E, Miltyk W, Palka JA, Jarzabek K & Wolczynski S. (2006) Hyaluronic acid counteracts interleukin-1-induced inhibition of collagen biosynthesis in cultured human chondrocytes. *Pharmacol Res* 54, 275–281.
- Levine LA. (1997) Treatment of Peyronie's disease with intralesional verapamil injection. *J Urol* 158, 1395–1399.
- Levine LA & Estrada CR. (2002) Intralesional verapamil for the treatment of Peyronie's disease: a review. *Int J Impot Res* 14, 324–328.
- Levine LA, Merrick PF & Lee RC. (1994) Intralesional verapamil injection for the treatment of Peyronie's disease. *J Urol* 151, 1522–1524.
- Levine LA, Cuzin B, Mark S, Gelbard MK, Jones NA, Liu G, Kaufman GJ, Tursi JP & Ralph DJ. (2015) Clinical safety and effectiveness of collagenase clostridium histolyticum injection in patients with Peyronie's disease: a phase 3 open-label study. *J Sex Med* 12, 248–258.
- Mitropoulos D, Artibani W, Graefen M, Remzi M, Roupret M, Truss M & European Association of Urology Guidelines P. (2012) Reporting and grading of complications after urologic surgical procedures: an ad hoc EAU guidelines panel assessment and recommendations. *Eur Urol* 61, 341–349.
- Nehra A, Alterowitz R, Culkin DJ, Faraday MM, Hakim LS, Heidelbaugh JJ, Khera M, Kirkby E, McVary KT, Miner MM, Nelson CJ, Sadeghi-Nejad H, Seftel AD, Shindel AW, Burnett AL & American Urological Association E, Research I. (2015) Peyronie's disease: AUA guideline. *J Urol* 194, 745–753.
- Rehman J, Benet A & Melman A. (1998) Use of intralesional verapamil to dissolve Peyronie's disease plaque: a long-term single-blind study. *Urology* 51, 620–626.
- Safarinejad MR, Asgari MA, Hosseini SY & Dadkhah F. (2010) A double-blind placebo-controlled study of the efficacy and safety of pentoxifylline in early chronic Peyronie's disease. *BJU Int* 106, 240–248.
- Shirazi M, Haghpanah AR, Badiee M, Afrasiabi MA & Haghpanah S. (2009) Effect of intralesional verapamil for treatment of Peyronie's disease: a randomized single-blind, placebo-controlled study. *Int Urol Nephrol* 41, 467–471.
- Takahashi K, Hashimoto S, Kubo T, Hirasawa Y, Lotz M & Amiel D. (2000) Effect of hyaluronan on chondrocyte apoptosis and nitric oxide production in experimentally induced osteoarthritis. *J Rheumatol* 27, 1713–1720.
- Viktrup L, Hayes RP, Wang P & Shen W. (2012) Construct validation of patient global impression of severity (PGI-S) and improvement (PGI-I) questionnaires in the treatment of men with lower urinary tract symptoms secondary to benign prostatic hyperplasia. *BMC Urol* 12, 30.
- Yu CJ, Ko CJ, Hsieh CH, Chien CT, Huang LH, Lee CW & Jiang CC. (2014) Proteomic analysis of osteoarthritic chondrocyte reveals the hyaluronic acid-regulated proteins involved in chondroprotective effect under oxidative stress. *J Proteomics* 99, 40–53.
- Zucchi A, Costantini E, Cai T, Cavallini G, Liguori G, Favilla V, De Grande G, D'Achille G, Silvani M, Franco G, Palmieri A, Verze P & Mirone V. (2016) Intralesional injection of hyaluronic acid in patients affected with Peyronie's disease: preliminary results from a prospective, multicenter, pilot study. *Sex Med* 4, e83–e88.