

EDITORIAL COMMENT

Angiographic or Functional Success? Rethinking the Goal of Percutaneous Coronary Intervention*



Davide Capodanno, MD, PhD

Over the past 3 decades, the definition of complete revascularization following percutaneous coronary intervention (PCI) or coronary artery bypass grafting has moved from the concept of complete “anatomic” revascularization (i.e., irrespective of size and territory supplied, or based on minimum diameter or vessel type criteria) to the concept of “functional” or “reasonably complete” revascularization (1). Because it is well established that assessing coronary physiology by means of fractional flow reserve (FFR) and other indices allows for the safe deferral of nonischemia-producing lesions, the quest for full anatomic revascularization irrespective of functional significance has become more a cosmetic than a thoughtful goal.

The SYNTAX score is the most accepted computational tool to quantify the anatomic complexity of coronary artery disease (2). Unsurprisingly, the functional SYNTAX score (FSS) calculated as the SYNTAX score of vessels with positive FFR has been associated with improved prognostic implications compared with anatomic assessment alone (3). The addition of clinical variables to the SYNTAX score has also been proven to refine its discrimination characteristics (2,4). In studies assessing the prognostic impact of complete revascularization, adaptations of the SYNTAX score have been introduced to quantify the degree of atherosclerosis left untreated after PCI (i.e., residual SYNTAX score [rSS]) or coronary artery

bypass grafting (i.e., coronary artery bypass grafting-SYNTAX score) (5,6). The proliferation of prognostic models to be used after revascularization could be seen as an intellectual sophistication with limited applicability in daily practice, but objectifying the extent of residual lesions and/or ischemia has at least some research implications. In this context, for example, one may be interested in quantifying the impact of functionally significant lesions left untreated by PCI. To address this question, another index integrating anatomic and functional information named residual FSS (rFSS) has been theorized, which can be calculated as the rSS of vessels with positive FFR (Figure 1).

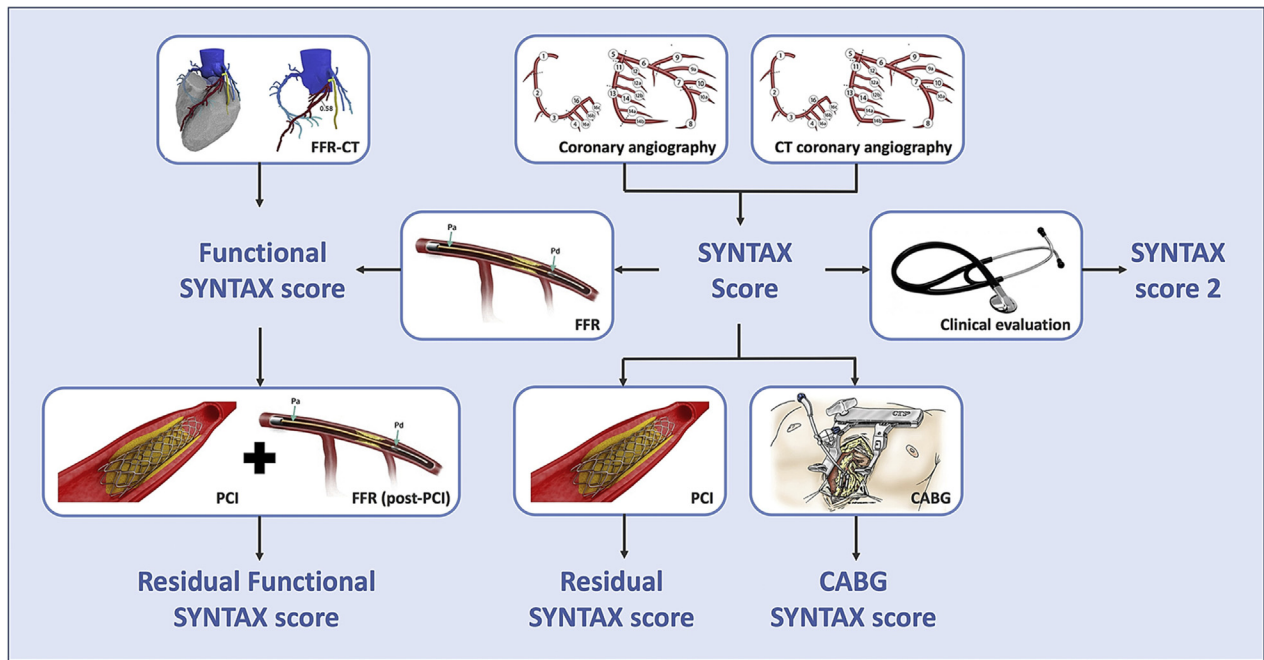
SEE PAGE 237

In this issue of *JACC: Cardiovascular Interventions*, Choi et al. (7) report on a pre-specified subanalysis of the 3V FFR-FRIENDS registry (n = 1,136), a previously published prospective investigation of the clinical relevance of total physiologic atherosclerotic burden assessed by total sum of FFR in the 3 major coronary vessels (3-vessel FFR), now focusing on the 385 patients (34%) who underwent PCI. Because by study protocol FFR measurements were repeated in all vessels treated with PCI, and because not all the FFR-positive lesions were treated, the authors were able to determine the rFSS as the rSS of vessels with post-PCI FFR ≤ 0.80 , and to compare its prognostic ability with the corresponding performances of the rSS and post-PCI 3-vessel FFR. Reasons for leaving functionally significant lesions untreated included the presence of diffuse disease with no apparent focal stenosis (50%); the reverse mismatch between angiographic severity and functional significance (34%); and lesion location in small, calcified, or tortuous vessels (16%). A 4-fold higher adjusted risk of major adverse cardiac events at 2 years was observed in 102 patients with rFSS ≥ 1 , indicating functional incomplete

*Editorials published in *JACC: Cardiovascular Interventions* reflect the views of the authors and do not necessarily represent the views of *JACC: Cardiovascular Interventions* or the American College of Cardiology.

From the Division of Cardiology, Cardio-Thoracic-Vascular Department, Azienda Ospedaliero Universitaria “Policlinico-Vittorio Emanuele,” Catania, Italy; and the Department of General Surgery and Medical-Surgical Specialties, University of Catania, Catania, Italy. Dr. Capodanno has reported that he has no relationships relevant to the contents of this paper to disclose.

FIGURE 1 SYNTAX Score and Its Adaptations



CABG = coronary artery bypass graft; CT = computed tomography; FFR = fractional flow reserve; PCI = percutaneous coronary intervention.

revascularization, compared with 283 patients with rFSS = 0, indicating functional complete revascularization. A prognostic model including clinical risk factors and the rFSS displayed a discrimination C statistic of 0.70, which was numerically higher than that observed in models embracing clinical risk factors only (0.56), and clinical risk factors plus rSS (0.62) or 3-vessel FFR (0.63). Although these findings sound plausible and intriguing, it should be noted in assessing generalizability that the study reflects a low-risk PCI population with no left main disease or chronic total occlusions, a 3-vessel disease in only 29%, and little usage of stents. Also notably, at 2 years, only 24 major adverse cardiac events were counted, which were mostly ischemia-driven revascularizations (a more subjective endpoint than death or myocardial infarction). Adding to the small sample size and the observational nature of the study, these caveats emphasize the need for cautious interpretation.

Yet, putting the results in perspective, a commendable aspect of the 3V FFR-FRIENDS sub-study is the attempt of characterizing the extent and impact of functional incomplete revascularization by means of the rFSS. This is a different focus than that of an earlier sub-study of the FAME trial, where the authors looked at the relationship between clinical

events and the rSS after FFR-guided functionally complete revascularization, concluding that residual angiographic lesions that are not functionally significant do not reflect residual ischemia or predict a worse outcome (8). Choi et al. (7) now suggest in a complementary manner that functional incomplete revascularization, on top of clinical risk factors, is a more important determinant of clinical adverse sequelae than anatomically incomplete revascularization. Should operators be more aggressive in treating all FFR-significant lesions than the operators were in this registry? The authors refrain from making this argument explicit, but the implication resonates from their findings. Indeed, the visual-functional mismatch between coronary angiography and physiology can be addressed by intracoronary imaging in doubtful cases. Treatable lesions in the context of diffuse disease and challenging anatomies should not be overlooked if they are accountable for residual ischemia. PCI by itself does not guarantee that complete functional revascularization is achieved: suboptimal stent deployment, another preventable or correctable factor, determines local abnormal shear stress and lower FFR (9,10).

It is too early based on the available evidence to conclude that physiologic assessment should be

performed extensively not only before but also after PCI, but the analysis from Choi et al. (7) is another step in that direction. Confirmation in studies with larger numbers, experimental design, and more granular risk stratification by increasing rFSS thresholds would be of value. Indeed, future developments in post-processing of coronary imaging with determination of pseudo-FFRs (i.e., quantitative flow ratio) may enable quicker and automatic calculation of functional prognostic parameters, including the rFSS. Impaired post-PCI FFR indicates residual ischemia that may be attributed to undetected or suboptimally treated

atherosclerosis. For years, interventional cardiologists have determined the success of their procedures by relying on visual estimation of post-procedural coronary angiography. There is now accruing belief that “functional success” should replace “angiographic success” as a performance metric in the PCI jargon.

ADDRESS FOR CORRESPONDENCE: Dr. Davide Capodanno, Division of Cardiology, Cardio-Thoracic-Vascular Department, Azienda Ospedaliero Universitaria Policlinico-Vittorio, Via Santa Sofia 78, 95123, Catania, Italy. E-mail: dcapodanno@gmail.com.

REFERENCES

1. Ong ATL, Serruys PW. Complete revascularization: coronary artery bypass graft surgery versus percutaneous coronary intervention. *Circulation* 2006;114:249-55.
2. Capodanno D. Risk stratification for percutaneous coronary intervention. *Interv Cardiol Clin* 2016;5:249-57.
3. Nam C-W, Mangiacapra F, Entjes R, et al. Functional SYNTAX Score for risk assessment in multivessel coronary artery disease. *J Am Coll Cardiol* 2011;58:1211-8.
4. Farooq V, van Klaveren D, Steyerberg EW, et al. Anatomical and clinical characteristics to guide decision making between coronary artery bypass surgery and percutaneous coronary intervention for individual patients: development and validation of SYNTAX Score II. *Lancet* 2013;381:639-50.
5. Généreux P, Palmerini T, Caixeta A, et al. Quantification and impact of untreated coronary artery disease after percutaneous coronary intervention: the residual SYNTAX (Synergy Between PCI with Taxus and Cardiac Surgery) Score. *J Am Coll Cardiol* 2012;59:2165-74.
6. Farooq V, Girasis C, Magro M, et al. The CABG SYNTAX Score: an angiographic tool to grade the complexity of coronary disease following coronary artery bypass graft surgery. From the SYNTAX Left Main Angiographic (SYNTAX-LE MANS) substudy. *EuroIntervention* 2013;8:1277-85.
7. Choi KH, Lee JM, Koo B-K, et al. Prognostic implication of functional incomplete revascularization and residual functional SYNTAX score in patients with coronary artery disease. *J Am Coll Cardiol Intv* 2018;11:237-45.
8. Kobayashi Y, Nam C-W, Tonino PAL, et al. The prognostic value of residual coronary stenoses after functionally complete revascularization. *J Am Coll Cardiol* 2016;67:1701-11.
9. Li S-J, Ge Z, Kan J, et al. Cutoff value and long-term prediction of clinical events by FFR measured immediately after implantation of a drug-eluting stent in patients with coronary artery disease. *J Am Coll Cardiol Intv* 2017;10:986-95.
10. Fearon WF, Luna J, Samady H, et al. Fractional flow reserve compared with intravascular ultrasound guidance for optimizing stent deployment. *Circulation* 2001;104:1917-22.

KEY WORDS angiographic success, functional residual SYNTAX score, functional success, SYNTAX score