POROCARCINOMA OF THE EYELID TREATED WITH PROTON BEAM RADIOTHERAPY: CASE REPORT AND LITERATURE REVIEW

ALESSANDRA TOCCO*, GIUSEPPE PRIVITERA*, LUIGI RAFFAELE*, VINCENZO SALAMONE*, CLAUDIO SCOGLIO*, ROBERTO MILAZZOTTO*, DARIO MARLETTA*, GIACOMO CUTTONE**, GIUSEPPE ANTONIO PABLO CIRRONE**, ANDREA RUSSO***, TERESIO AVITABILE***, CORRADO SPATOLA *
*UO Radiodiagnostica e Radioterapia Policlinico-VE Catania, **INFN-LNS Catania, ***UO Oftalmologia Policlinico-VE Catania

ABSTRACT

Introduction*: Porocarcinoma is a rare sort of skin cancer developing from eccrine sweat glands, with a very rare location to the eyelid. Surgery is the unique form of treatment reported in the literature. We use radiotherapy for a case of an almost centenary man who suffered from an histologically proven porocarcinoma at the level of the left inferior eyelid.*

Materials and methods*: We made a treatment plan comparison between photon-beam and proton-beam radiotherapy and chose the latter due to the favourable dose distribution of charged particles. Irradiation was delivered through an extreme hypofractionation*

Results*: A rapid complete response was obtained. No relevant effects have been reported and visual function is maintained.*

Conclusions*: This is the first case of use of proton-beam radiotherapy for the treatment of eyelid porocarcinoma. We believe that protontherapy can become a valid alternative to surgery for this type of cancer.*

Keywords*: Eyelid porocarcinoma, eccrine, radiotherapy, proton therapy.*

DOI: 10.19193/0393-6384_2018_3_109

Received *August 30, 2017;* ***Accepted*** *January 20, 2018*

Introduction

Porocarcinoma is a very rare sort of malignant skin cancer developing from eccrine sweat glands. Its etiology is not well understood. However, some studies have showed that the tumor developed from a pre-existing eccrine poroma, it is believed that it arises from the eccrine secretory apparatus, specifically the intradermal portion of the sweat gland duct, called the acrosyringium.

Its biological behavior is unpredictable, with an high rate of recurrence after resection and metastasis to vital organs[1].

Eyelid location is even more rare and surgery is the unique form of treatment reported in the literature, while no experience exist on the use of radiotherapy[2-3].

We report our experience in its use in a very elderly patient, who was judged unsuitable for surgery.

Case report

We report the case of a 98 years old man who suffered from a histologically proven porocarcinoma at the level of the left inferior eyelid (Figure 1a). The lesion showed a rapid growth in a two-month period. Because of his age and the cardiac comorbidities, surgery was excluded and the patient has been sent to our centre to be evaluated for radiation therapy.

Patient performed a diagnostic MR to evaluate the dimension of the lesion (18 mm in maximum diameter) and the depth of invasion of the orbital

soft tissues. There was no involvement of ocular structures and patient retained a good visual acuity.

Fig. 1: Disease presentation at diagnosis at the level of the left inferior eyelid (a), at 4-weeks follow-up (b) and after 14 months from the end of treatment (c).

The objective of treatment was to reduce the eyelid swelling that produced a major discomfort, a moderate-severe painful symptomatology to the patient and some bleeding episode.

Moreover, the rather tumultuous growth of the tumor mass would shortly cause a loss of visual function to the patient.

After obtaining an informed consent by the patient and his relatives, an orbital radiotherapy was proposed. A treatment plan comparison was made between a photon-beam treatment with intensity-modulated radiotherapy (IMRT) or stereotactic technique (SRT) and a proton-beam radiotherapy.

IMRT and SRT were simulated by means of a dedicated treatment plan system (TPS), Elekta XIO (ElektaAB, Stockholm, Sweden), with a step-and-shoot technique for IMRT plan and an arc-dynamic technique for SRT, that are currently in use at our centre for the treatment of other kind of tumors[4-6]. The dose distribution obtained was not satisfactory with both photon-beam techniques, because of an exceeding dose limit to the lens, the lacrimal gland and a discrete dose deposition to the whole orbital tissues. Moreover, a multiple fractionated treatment, at least 25 daily fractions (for IMRT) should have been done, with a reduced compliance for the old patient. Consequently, IMRT and SRT plans were refused.

Proton beam radiotherapy (PBRT) was delivered at CATANA (Centro di AdroTerapia ed Applicazioni Nucleari Avanzate) Centre, at INFN-LNS (Istituto Nazionale di Fisica Nucleare-Laboratorio del Sud) of Catania. Here, the accelerator in use is a Super-conducting Cyclotron that permits a proton beam at energy between 50 and 70 MeV with an intensity of 10-20Na. A dedicated beam line in air has been realized to bring the proton beam to the eye of the patient, who is placed in a seated position on treatment chair.

Patient fixation is allowed by a thermoplastic mask fixed on a frame. Dose distribution takes place through the well-known Bragg-peak phenomenon. It is responsible for an increasing dose deposition of these particles as they travel through the tissue, with a more or less constant low entry dose, a region of high dose at a depth determined by the initial proton energy, and no dose beyond the end of the range. For a 60 MeV proton beam the width of the falloff of the dose from 90% to 10% is about 1 mm at a depth of 3 cm.

Target volume definition is clinical. The entire lesion must be within the light field with 5 mm security margins. Dose profile is represented in figure 2. Treatment plan showed no dose deposition to lens, lacrimal gland and other orbital tissues.

We use a customized collimator packaged to take the entire lesion in its shape. We invited the patient to look at a point to create an optimal beam angle, in order to avoid unnecessary irradiation to organs at risk, and gaze angle to treat the tumor, while sparing as much as possible the cornea.

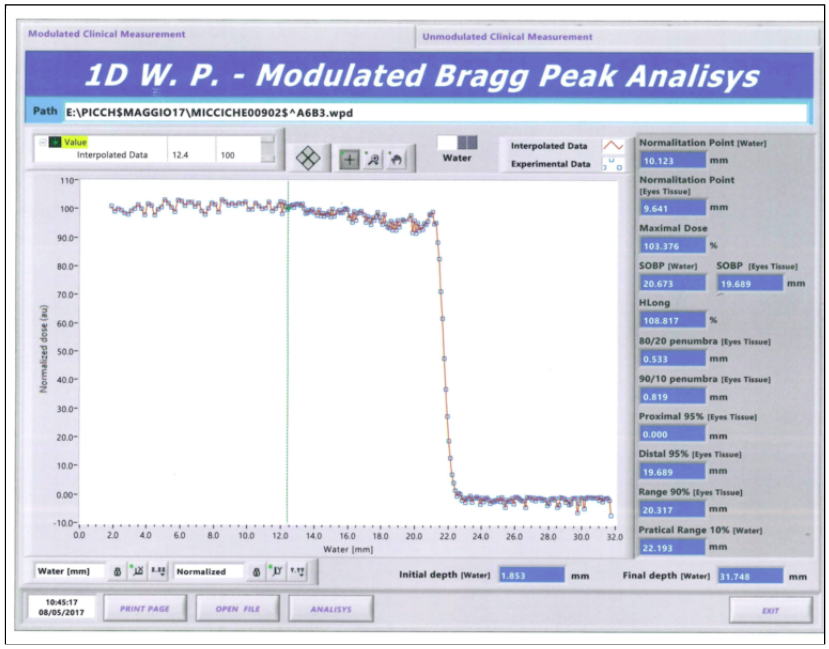

Fig. 2: Dose profile with 62 MeV proton beam.

The treatment is carried out in 4 fractions on 4 consecutive days. The prescribed total dose is 54.5 Gy, which corresponds to 60 GyRBE (Relative Biological Effectiveness) with fraction of 15 GyRBE. At follow-up after 4 weeks the lesion was completely disappeared (Figure 1b), with an acute conjunctivitis and eye swelling as unique acute side effects.

Treatment procedures are almost the same we use in the treatment of other more frequent ocular (i.e. uveal melanoma) or orbital and periorbital tumors (i.e. lymphoma, basal cell and squamous cell carcinoma) at CATANA Centre[7-8].

The rapid and dramatic response obtained is still maintained after 14 months from the end of treatment and patient at present is almost centenary (figure 1c). No relevant late side effects have been reported, except for an eyelashes loss and eyelid teleangectasia, visual function is maintained.

Discussion

Porocarcinoma is a rare cutaneous adnexal tumor arising from the eccrine secretory apparatus. Because the clinical behavior of this cancer includes deep invasion, regional lymphatic spread, and distant metastases, complete surgical excision is recommended1. To date, there have been few cases of eyelid porocarcinoma reported in the literature. All patients underwent surgery with no evidence of progression disease at their last follow up; unfortunately, we lack data on their further follow up or cosmetic results of the surgical approaches. None of the patients underwent any form of radiation therapy (conventional type or radiosurgery), so this is the first experience in this department and we cannot make comparisons between different techniques.

In this case, the technique with protons was preferred to traditional photon-beam radiation therapy for the favourable dose distribution of proton beams, the possibility of "striking" the lesion with a higher dose per fraction (15 Gy/day) and the greater local control obtained.

Conclusion

Sweat gland carcinomas are rare cutaneous adnexal tumor with confusing histopathology and uncertain clinical behavior.

Proton beam radiotherapy has produced in the case presented a rapid and complete response, thanks to the high-dose fractionation of 15 GyRBE daily, with a very limited spectrum of acute and late side effects.

We believe that our experience can allow other patients to benefit from PBRT for the treatment of orbital and periorbital malignant tumors.

References

1) Salih AM, Kakamad FH, Baba HO, Salih RQ, Hawbash MR, Mohammed SH, Othman S, Saeed YA, Habibullah IJ, Muhialdeen AS, Nawroly RO, Hammood ZD, and Abdulkarim NH: Porocarcinoma: presentation and management, a meta-analysis of 453 cases. Annals of medicine surgery (Lond), 2017 Aug; 20: 74-79.

2) Chua PY, Cornish KS, Stenhouse G, Barras CW: A Rare Case of Eccrine Porocarcinoma of the Eyelid. Semin Ophthalmol. 2015;3 0(5-6): 443-5. Epub 2014 Feb 27.

3) Boynton JR, Markowitch W Jr: Porocarcinoma of the eyelid. Ophthalmology. 1997 Oct;104(10):1626-8

4) Spatola C, Militello C, Tocco A, Salamone V, Raffaele L, Migliore M, Pagana A,Milazzotto R,Chillura I, Pergolizzi S & Privitera G: Intensity-modulated radiotherapy for relapsed malignant pleural mesothelioma . Future Oncology (2016); 12(23s), 67-71.

5) Spatola C, Militello C, Tocco A, Salamone V, Luigi R, Migliore M, Marletta D, Cannizzaro A, Bevilacqua R, Milone P, Pergolizzi S & Privitera G. Single-institution experience of intensity-modulated radiotherapy for

malignant pleural mesothelioma at University of Catania. Future Oncol. 2018 Feb 5. doi: 10.2217/fon-2017-0280. [Epub ahead of print]

6) Spatola C, Tocco A, Milazzotto R, Pagana A, Chillura I, Bevilacqua R, Militello C, Salamone V, Raffaele L, Migliore M, & Privitera G: Role, timing and technique of radiotherapy in pediatric pleuropulmonary synovial sarcoma. Future Oncology (2016) 12(23s), 73-77.

7) Spatola C, Privitera G, Raffaele L, Salamone V, Valastro L.M, Cuttone G, Cirrone GAP: Protontherapy of ocular tumors: 5 Years experience at Italian CATANA Centre. Rivista medica, vol.14, N.1, 2008.

8) Cirrone GAP, Cuttone G, Raffaele L, Salamone V, Avitabile T, Privitera G, Spatola C, Margarone D, Patti V,1,4 Petringa G, Romano F,1,5 Russo A, Sabini MG, Scuderi V, Schillaci F, and Valastro LM. Clinical and research activities at the CATANA facility of INFN-LNS: From the conventional hadrontherapy to the laser-driven approach. Frontiers in Oncology, Sept 2017, Volume 1, Article 223.

Corresponding Author:
ALESSANDRA TOCCO
e-mail: aluccia82@hotmail.it
(Italy)